

## AMNIOTIC-FLUID EMBOLISM

## A CASE REPORT AND REVIEW OF THE RECENT LITERATURE

J. DOMMISSE, M.B., CH.B., M.R.C.O.G., Lecturer, Division of Obstetrics and Gynaecology, University of Cape Town and Cape Provincial Administration

Amniotic-fluid embolism is a rare but catastrophic complication of pregnancy. Awareness of this entity will lead to earlier clinical diagnosis. This is essential since treatment, to be effective, must be energetic. This case report, the second<sup>1</sup> in the South African literature, is presented together with a brief review of the possible mechanism, complications and treatment.

## CASE REPORT

C.M., a Coloured female aged 28 years, gravida 5, para 4, was a 'booked' admission. Her blood group was O Rhesus positive, and the Wassermann reaction was negative. Her previous obstetrical and medical history had been normal. No untoward features developed during her rather irregular antenatal attendance, except for an iron-deficiency anaemia, which was treated with oral ferrous sulphate.

The patient was admitted at 38 weeks of gestation with spontaneous rupture of the membranes. The presentation was vertex with the head not engaged; the foetal heart rate was normal. Twenty-four hours after admission she developed a pyrexia (100-101°F), and antibiotic therapy was commenced. The liquor became offensive, and 48 hours after admission no foetal heart was audible.

Labour commenced spontaneously 24 hours later and the patient delivered an 8-lb. macerated infant after 6 hours. The second stage was extremely rapid and the third stage was completed in 10 minutes. The placenta and membranes were complete and the blood loss 24 ounces. Intramuscular ergometrine was administered.

Immediately after completion of the third stage the patient had a rigor and collapsed. She was acutely dyspnoeic and cyanosed. The pulse was impalpable. The uterus was firmly contracted and there was no excessive vaginal bleeding. No free fluid was detectable in the peritoneal cavity.

Oxygen was administered and an intravenous infusion of dextrose commenced. A vaginal examination excluded uterine inversion, but revealed a tear of the lower uterine segment. Blood loss was slight and the shock disproportionate.

A rapid laevophed infusion was commenced and a systolic blood pressure of 60 mm.Hg was recorded. Hydrocortisone, 200 mg., was administered intravenously and 2 pints of blood transfused rapidly.

One hour after delivery the patient started to bleed rapidly *per vaginam* and a specimen of venous blood failed to clot. Two further pints of blood, 2 G of human fibrinogen, and 500 ml. of double-strength plasma was transfused. There was no response and 2½ hours after delivery the patient died.

## Autopsy Findings

The significant autopsy findings were as follows:

1. The uterine cavity contained a small amount of necrotic material. Smears showed gram-negative bacilli and gram-positive cocci. Cultures grew *Escherichia coli*. There was a tear in the myometrium extending from the cervix into the lower segment. The overlying peritoneum was intact, and there was no evidence of intraperitoneal haemorrhage.

2. Both pleural cavities contained half a pint of clear fluid. The lungs showed no macroscopic lesions of significance except oedema, but random microscopic sections showed the features of amniotic-fluid embolism. These are illustrated in Figs. 1 and 2.

3. There was striking pallor of all organs, notably the kidneys and the liver. The heart, in addition, was flabby and dilated with an extensive subendocardial haemorrhage at the base.

4. The spleen was soft and enlarged, weighing 334 G. The upper one-third of the femur contained red marrow.

## DISCUSSION

Several factors contributed towards this maternal death. Amniotic-fluid embolism was a significant feature, both clinically and histologically. A possible pre-existing anaemia, uterine rupture, and acute blood loss were also factors, as was the sepsis which could have produced an overwhelming endotoxoid shock—the so-called Swartzmann reaction.

## Mechanism

The syndrome of amniotic-fluid embolism was first described by Meyer in 1926.<sup>2</sup> A recent review of the literature by Aquillon *et al.*<sup>2</sup> reported 73 proved cases and described the syndrome as follows:

'Amniotic-fluid embolism is found mostly in "elderly" multiparas with difficult deliveries productive of large infants, followed shortly by the sudden onset of a fulminating and commonly fatal course. The patients with a short duration of symptoms exhibit acute respiratory distress, shock and death. Their autopsy findings include pulmonary

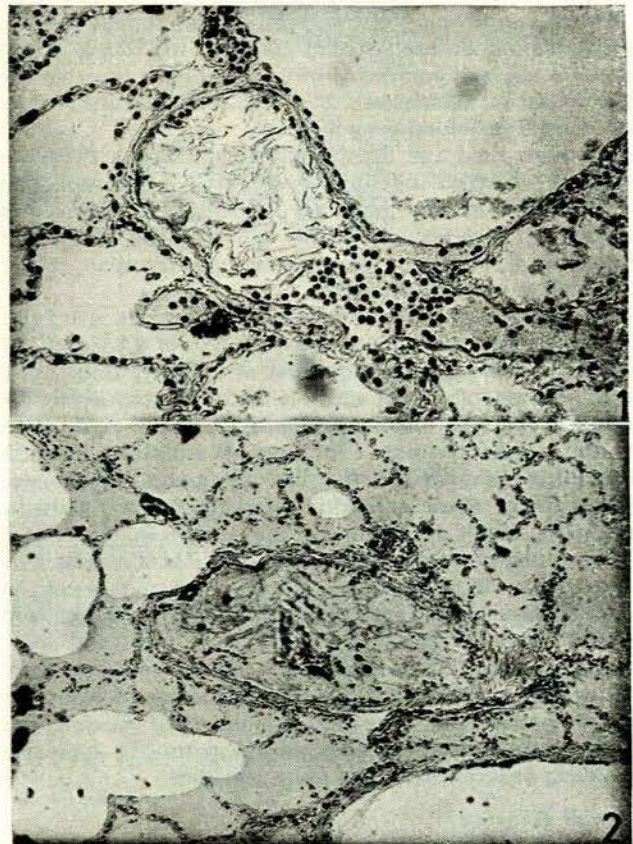


Fig. 1. Longitudinal section of a pulmonary capillary showing squames, lanugo hairs, and leukocytes.

Fig. 2. Pulmonary vessel distended with debris from vernix caseosa and meconium in the centre of the field. Oedema of the surrounding air sacs.

amniotic-fluid embolism, and pulmonary oedema. The patients who survive the initial episode exhibit a haemorrhagic tendency and show evidence of hypofibrinogenemia. With proper treatment, the Lord willing, recovery is possible.

Three possible portals of entry of amniotic fluid into the maternal blood stream have been postulated. Firstly, the fluid may track via a break in the membranes to the chorio-decidual space and hence into the maternal circulation, carrying with it decidual tissue rich in thromboplastins.<sup>3</sup> The venous sinuses in the endocervical region are not covered by membranes, and with the foetal head below this level liquor may be forced to enter these veins.<sup>3</sup> Finally, amniotic fluid may enter through a tear in the myometrium.

Entry usually occurs with strong contractions near the end of the second stage of labour and in most cases only when the contractions are tumultuous. High rupture of the membranes may be a predisposing factor.

At postmortem examination the pulmonary vessels may contain epithelial squames, lanugo hairs, particles of vernix caseosa, the mucus and epithelial cells of meconium, and leukocytes. There is also pulmonary oedema, and the mechanism of death in the acute stage is probably an acute dilatation of the pulmonary vessels producing reflex coronary vasoconstriction and a central type of shock.<sup>2</sup>

#### Coagulation Defect

Patients surviving the acute episode may rapidly develop a coagulation defect. Vaginal bleeding will occur if the uterus is not well contracted or a laceration is present. The mechanism of haemostasis in a well-retracted uterus does not depend on blood coagulation.<sup>4</sup>

Amniotic fluid and decidual tissue are rich in thromboplastins<sup>2, 4, 5</sup> which initiate the conversion of prothrombin to thrombin in the presence of calcium. Intravascular coagulation then occurs with not only fibrinogen depletion but also depletion of Ac-globulin, prothrombin, blood platelets and other factors.<sup>6-8</sup>

Hodgkinson and Neufeld<sup>7</sup> conceive this fibrinogen-fibrin conversion syndrome not as the migration of a formed clot but as the widespread distribution of a sticky, amorphous, freshly formed fibrin gel which is mixed and carried by the turbulence of the circulating blood. Another explanation for the relative absence of microscopic indication of fibrin thrombi in these cases<sup>9</sup> is that there is an increased fibrinolytic activity.<sup>3</sup> Some authorities consider fibrinolysis to be the major factor in producing the fibrinogen depletion.<sup>10</sup> The postulated mechanism is that tissue kinase, acting as an activator of plasminogen, produces plasmin which, in turn, by proteolysis digests the circulating fibrinogen and other coagulation factors.<sup>6</sup> Jackson *et al.*,<sup>11</sup> in fully documented cases of fibrinogenopaenia, failed to demonstrate any evidence of fibrinolytic activity. Schneider,<sup>12</sup> who feels that amniotic fluid does not produce defibrination, has demonstrated the appearance of a heparin-like substance following experimental meconium embolism.

#### Clinical Diagnosis

Amniotic-fluid embolus is, fortunately, a rare complication of pregnancy, but cannot usually be foreseen. One should, however, be wary of the multiparous patient with a large baby in tumultuous labour, especially if there is a

possibility that a high rupture of the membranes has occurred. Embolization usually occurs at the end of the second stage of labour. The dramatic clinical picture of sudden shock with dyspnoea and, usually, with cyanosis is typical, but may be simulated by pulmonary embolism or acute pulmonary oedema.

On standing, the blood is said to settle in three layers with a layer of amniotic debris above the buffy coat.<sup>2</sup>

The clinician must be on the immediate look-out for the development of a coagulation defect. This is probably a 'once for all'<sup>13</sup> mechanism, although in cases of afibrinogenemia complicating accidental haemorrhage Rocky and Crichton<sup>14</sup> believe that the defect may recur; they therefore advise hourly tests.

The simplest test is Weiner's clot-observation test,<sup>4</sup> but in addition Russel *et al.*<sup>15</sup> describe additional tests, firstly, mixing the specimen with unclotted donor blood to detect a heparin-like or anticoagulant material and, secondly, mixing a specimen with clotted donor blood, lysis within one hour being indicative of increased fibrinolytic activity.

The 'FI-Test' is a simple bedside method which may be of some value. Laboratory confirmation of the coagulation defect is impractical unless facilities are readily available. Most methods are rather tedious, but Ellis<sup>16</sup> has described a quick and accurate method utilizing an Evelyn photometer or a Unicam spectrophotometer. This method takes 30-40 minutes and is accurate within 5%. Estimates of fibrinolytic activity can be done by the Ratnoff technique.<sup>11</sup>

#### Management

There is, in our present state of knowledge, little that can be done to prevent this catastrophe. High artificial rupture of the membranes is possibly better avoided or combined with low rupture, and pitocin infusions should be carefully controlled if strong contractions are occurring.

In the acute stage treatment is with cardiac posture, oxygen (preferably under pressure), antispasmodics (such as aminophylline or papaverine), and pressor drugs such as aramine, hypertensin, or even adrenaline. Care must be taken not to overload these patients, and blood or other transfusion should be limited unless bleeding is occurring.

As early as 1937 Sheehan<sup>17</sup> demonstrated that if the blood is rendered incoagulable by the administration of heparin before injection of tissue extract (thromboplastin), the toxic and haematologic effects ordinarily seen do not occur. In 1963 Merskey *et al.*<sup>18</sup> and other investigators<sup>6, 19</sup> used heparin in cases of defibrination syndrome with excellent results. It would seem to be a logical step to administer heparin to these patients in the acute stage and possibly even after a coagulation defect has been demonstrated, thus preventing further intravascular coagulation occurring.

If the patient is actively bleeding, preparation must be made to deal with the bleeding site since this is unlikely to be from a well-retracted intact uterus.<sup>4</sup>

Several methods of correcting an established clotting defect have been advocated. It is important to remember that not only fibrinogen but also other coagulation factors are depleted, and also that in some cases there is evidence of fibrinolysis.<sup>6-8</sup> The possible value of heparin therapy has been mentioned. To date there is no report of it having been used in coagulation defects in pregnancy.

Human fibrinogen, in spite of its high cost, has been extensively used. It can, however, only replace one factor, and viral hepatitis is said to occur in 6% of cases, so that the additional administration of gamma globulin to these patients has been advocated.<sup>15</sup>

Stored blood is deficient in coagulation factors but is obviously the best treatment for oligoemic shock. Dried plasma reconstituted to quadruple strength contains approximately 4.4 G of fibrinogen per pint, but is difficult to administer, and much of the fibrinogen is collected on the blood filter. The method of freezing and thawing is very important in regard to the eventual yield of active fibrinogen per unit of fresh frozen plasma.<sup>20</sup> This is approximately 0.5 G<sup>21</sup> per unit and in addition contains most of the other factors which may be depleted.<sup>13</sup> It is easily and rapidly administered. The only disadvantage is the increased blood volume produced. We have been very impressed with the reversal of the coagulation defect in cases of hypofibrinogenaemia complicating accidental haemorrhage produced by only 2 or 3 units of FFP.

Patients not responding to this therapy should be suspected of having increased fibrinolytic activity. Recently this has been successfully treated with epsilon-amino-caproic acid;<sup>10, 13, 22</sup> 3-6 G being administered by slow intravenous injection. Russel *et al.*<sup>15</sup> advocate the administration of hydrocortisone in these cases, but this is purely empirical.

Dextran and similar substances should be avoided since they form a dextran-fibrinogen complex, further depleting the coagulation factors.<sup>4</sup>

## SUMMARY

A fatal case of amniotic-fluid embolism associated with a coagulation defect is presented.

The pathological mechanism, clinical picture and management is discussed.

Recent advances in treatment include the use of heparin and epsilon-amino-caproic acid.

The advantages of fresh frozen plasma in correcting the coagulation defect is stressed.

I wish to thank Dr. E. Barrow, Superintendent of St. Monica's Home, for permission to publish this report, and Dr. G. Selzer for her advice and the photographic illustrations. The late Prof. James T. Louw encouraged the writing of this report.

## REFERENCES

- De Wet, J. J. and Steytler, J. G. (1959): *S. Afr. Med. J.*, **33**, 1051.
- Aquillon, A., Andjus, T., Grayson, A. and Race, G. J. (1962): *Obstet. Gynec. Surv.*, **17**, 619.
- Reid, D. E., Weiner, A. E. and Roby, C. C. (1953): *Amer. J. Obstet. Gynec.*, **66**, 465.
- Bourne, A. W. and Williams, L. H. (1962): *Recent Advances in Obstetrics and Gynaecology*, pp. 182-190. London: Churchill.
- Ratnoff, O. D. and Vosburgh, G. J. (1952): *New Engl. J. Med.*, **247**, 970.
- Leading article (1960): *Brit. Med. J.*, **1**, 789.
- Hodgkinson, C. P. and Neufeld, J. (1960): *Clin. Obstet. Gynec.*, **3**, 585.
- Tuller, M. (1957): *Amer. J. Obstet. Gynec.*, **73**, 273.
- Schneider, C. L. (1951): *Surg. Gynec. Obstet.*, **92**, 27.
- Nilsson, J. M., Sjoerdsma, A. and Waldenström, J. (1960): *Lancet*, **1**, 1322.
- Jackson, D. P., Hartmann, R. C. and Busby, T. (1955): *Obstet. and Gynec.*, **5**, 223.
- Schneider, C. L. (1953): *Amer. J. Obstet. Gynec.*, **65**, 245.
- Panel discussion (1962): *Brit. Med. J.*, **2**, 394.
- Rockey, T. and Crichton, D. (1961): *S. Afr. Med. J.*, **35**, 765.
- Russel, K. P., Caillonett, J. C. and Longo, L. D. (1960): *Clin. Obstet. Gynec.*, **3**, 703.
- Ellis, B. C. and Stransky, A. (1961): *J. Lab. Clin. Med.*, **58**, 477.
- Sheehan, H. L. (1937): *J. Path. Bact.*, **45**, 189.
- Merskey, C. *et al.* (1963): *Lancet*, **1**, 611.
- Von Francken, J. *et al.* (1963): *Ibid.*, **1**, 70.
- Bradlow, B. A. and Ellis, B. C. (1960): *Med. Proc.*, **6**, 253.
- Ellis, B. C.: Personal communication.
- Belko, J. S. *et al.* (1963): *Arch. Surg.*, **86**, 396.