

# THE SURGICAL APPROACH TO THE MITRAL VALVE AND THE TECHNIQUE OF CORRECTING INSUFFICIENCY OF THE ANTERIOR AND OF THE POSTERIOR CUSP WITH PERICARDIUM

J. C. VAN DER SPUY, DIP. SURG.; F. A. MEINTJIES, F.R.C.S. (EDIN.); AND G. HUMAN, M.MED. (INT.),\* *Departments of Thoracic Surgery and Medicine, University of Pretoria and Pretoria General Hospital, Republic of South Africa*

I have planted, Apollos watered; but God gave the increase. So then neither is he that planteth anything neither he that watereth; but God that giveth the increase (*1 Corinthians*: 3, v. 6, 7).

Since Lillehei and his associates<sup>6</sup> first presented an open-heart method for the treatment of mitral insufficiency in 1957, several other reports have been published on this subject and several different approaches to the mitral valve described. Thus the mitral valve has been approached from the right through a vertical incision in the left atrium posterior to the inter-atrial groove or via the right atrium, by incising the inter-atrial septum using postero-lateral,<sup>6</sup> antero-lateral<sup>4</sup> and median sternotomy<sup>7</sup> incisions, and through the left atrial appendage by means of a transverse transsternal incision.<sup>4</sup>

As we believed that the complete correction of mitral insufficiency could best be obtained by paying detailed attention to the functional correction of the morbid anatomy<sup>14</sup> of the valve unit, it became clear that the approach to the valve should ideally be one which would allow the surgeon an excellent view of the valve unit from close range. During 1958 and 1959\*\* 2 left-sided

\*Bursar, Cardiac Research Group, CSIR.

\*\*Unpublished data.

approaches were therefore developed in the animal laboratory, namely, transventricular to the cusps, chordae tendineae and papillary muscles and transatrial to the ring and cusps. Both these approaches as such were employed with equal success. As it became apparent that lengthening of the shortened and thickened chordae tendineae would present serious technical difficulties, and because the ring and cusps were much more readily accessible via the left atrium, the transventricular approach was abandoned and the transatrial approach fully developed. Nichols and associates,<sup>6</sup> working independently, published the results they obtained with annuloplasty in 36 patients with mitral insufficiency and in 37 with mitral stenosis using a very similar left-sided approach.

## ANATOMICAL CONSIDERATIONS<sup>12</sup>

The antero-medial (anterior) cusp of the mitral valve is much longer than the postero-lateral (posterior) cusp. As the apical zones of the 2 cusps correspond, the body of the anterior cusp lies opposite the base of the shorter posterior cusp.

The chordae tendineae of the posterior cusp are inserted into the entire undersurface of the cusp except for a narrow basal zone. Those of the anterior cusp are inserted into a wide zone along the periphery of the cusp. The remaining larger central trigonal portion of the anterior cusp is therefore thinner and more mobile than the marginal zone since its

movements are not directly limited by the chordae tendineae. On the undersurfaces of the cusps the chordae tendineae expand into flat, somewhat triangular, sheets which are attached to the cusps at acute angles, resulting in the formation of many small nooks and crevices.

The base of the anterior cusp is attached to the postero-lateral half of the root of the aorta and, therefore, in the resting position this cusp is naturally convex posteriorly. The excursions of the central portion of the anterior cusp during systole increases this convexity. The posterior cusp is attached to the concave base of the left ventricle, and the base of this cusp is therefore concave anteriorly. At the end of systole the convex anterior cusp fits into the concave base of the posterior cusp. At this stage a large portion of the anterior cusp billows towards the left atrium above the level of the base of the posterior cusp.

During systole the anterior cusp swings upwards and backwards. This swing is made possible by the absolute length of the cusp and its chordae tendineae, by the relative increase in this length caused by systolic approximation of the bases of the papillary muscles towards the mitral 'ring', and by the stretching of these muscles by the intraventricular pressure exerted on the undersurface of the cusp.

Shortening of the cusps and of the chordae tendineae, fixity of the papillary muscles, and thickening of the central trigone of the anterior cusp will therefore reduce the efficient functioning of the mitral valve.

#### PATHOLOGICAL CONSIDERATIONS<sup>14</sup>

The characteristic valve lesions found in mitral rheumatic endocarditis are the result of both valvulitis and tendinitis. The tendinitis plays a very much more important role in the production of incompetence, and even perhaps of stenosis, than the valvulitis. As a result of a fibrinous deposit on the surface of the chordae tendineae, the fine filaments become fused and thickened. Subsequently, owing to fibrosis, they become shortened. The fibrinous deposit in the nooks and crevices on the under-surfaces of the cusps leads to thickening and eventually to shortening of the corresponding areas of the cusps. Thickening and shortening will therefore chiefly affect the chordal zones of the cusps and consequently the extent and distribution thereof will differ considerably in the 2 cusps. The cusp which is the seat of active valvulitis is oedematous and infiltrated by macrophages and fibroblasts with fibrin deposited on the surface. Later it becomes infiltrated by fibrous tissue. This valvulitis is of particular importance in relation to the mobility of the central trigone of the anterior cusp.

#### SURGICAL CONSIDERATIONS

There is probably general agreement by workers in this field that on the whole the results of the treatment of mitral insufficiency with annular plication are very unsatisfactory. Annuloplasty will, no doubt, be of considerable value in the treatment of incompetence caused by a markedly dilated annulus<sup>4</sup> and also perhaps in cases of lateral commissural incompetence owing to eccentric endocarditis.<sup>14</sup>

Work is at present in progress in many centres<sup>1-3, 5, 11</sup> in an attempt to find a completely satisfactory mitral valve prosthesis, which many hope may be the final solution to this difficult problem. Even gross incompetence, however, is very frequently produced by a very limited disease process, and even grossly scarred valve tissue is good, strong, functioning tissue and should not be sacrificed indiscriminately. In such cases it is probably more correct to reconstruct an incompetent valve anatomically and functionally, perhaps with the aid of autogenous tissue,<sup>5, 10</sup> rather than to replace the whole valve with a prosthetic-valve unit.

In cases of posterior-cusp incompetence it would seem correct to lengthen the cusp unit by means of a thin and

mobile inlay into the bare basal area of the posterior cusp.

In the case of anterior-cusp incompetence with shortening and thickening of the chordae tendineae, the marginal zone and central trigone, competence will be restored by means of a somewhat semilunar inlay along the outside margin of the central trigone, i.e. along the inside margin of the peripheral zone of chordal insertion.

#### APPROACH AND TECHNIQUE OF OPERATION

With the patient in the supine position a No. 4 polythene tube, for monitoring right atrial pressure during cardiopulmonary bypass and during the early postoperative period, is passed into the inferior vena cava via the right saphenous vein.

With the patient in the lateral position the left pleural cavity is entered by means of an extended postero-lateral incision through the bed of the sixth rib. The mediastinal pleura and blood vessels are dissected from a portion of the pericardium selected for the reconstruction of the incompetent mitral valve. The pericardium is thereafter opened vertically anterior to the phrenic nerve. The mitral valve is explored digitally through the left atrial appendage and the size and localization of the valve opening, the mobility and thickness of the individual cusps and the extent and localization of the regurgitant stream very carefully noted. The left subclavian artery is dissected out. Heparin is then administered.

A slightly angled arterial cannula, mounted on a 10-inch length of tygon tubing, is introduced into the proximal portion of the subclavian artery through the second intercostal space in the paravertebral region. This approach to the subclavian artery facilitates cannulation of the artery and removes the arterial line from the field of operation.

A right-angled stainless steel cannula mounted on a 10-inch length of tygon tubing, is passed through an opening of the same size, made with Hegar's dilators, at the base of the right ventricular outflow tract and connected to the venous line of the pump-oxygenator.

A second right-angled stainless steel cannula, mounted on a 10-inch length of tygon tubing, is passed into the cavity of the left ventricle through an opening, dilated to the same size with Hegar's dilators, near the apex of the ventricle. This catheter is connected to the decompression line from the inflow end of the left ventricular decompression chamber illustrated in Fig. 1.

Partial bypass is now started. At the very same moment the left ventricular decompression system is allowed to function by removing the clamp across the decompression line. When a flow rate of about 50 ml. per kilo. per minute is reached, the pulmonary artery, not previously dissected out, is cross-clamped. Drainage from the right ventricle is by means of suction and removes caval as well as coronary sinus blood. The patient's temperature is controlled at 32°C.

Ventricular fibrillation is produced by means of electrical fibrillation or hypothermia.

Before extending the incision in the left auricle widely into the atrium, about  $\frac{3}{4}$  inch above the atrio-ventricular groove, the decompression line is clamped off. With the left atrium now widely opened, the cusps and chordae

tendineae can be carefully inspected without any danger of air embolism.

The pre-operative assessment of the morbid and functional anatomy of the valve,<sup>14</sup> and the information ob-

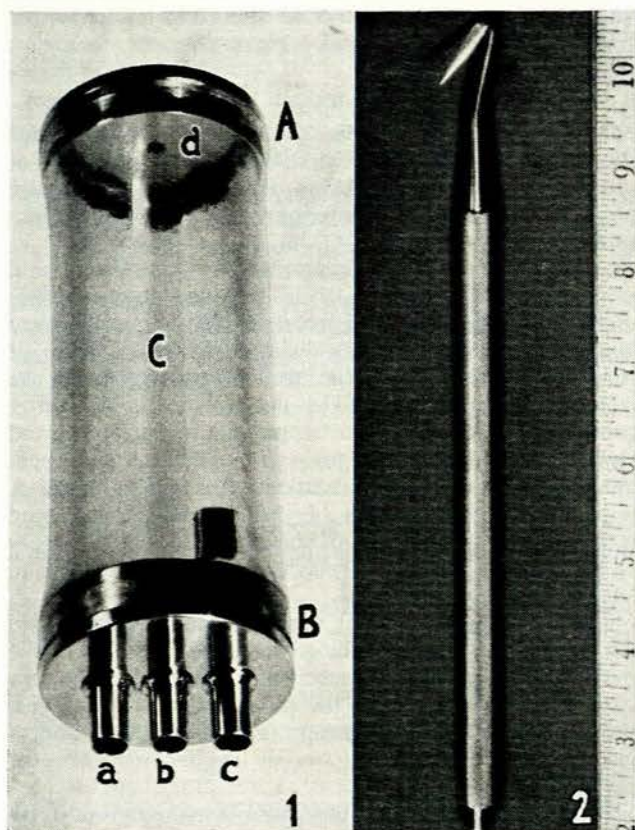


Fig. 1. The assembled decompression chamber.

A. Stainless steel upper end-plate with air vent (d) through which first the  $\frac{3}{8}$ -inch tygon decompression line, and thereafter the decompression chamber, are filled with heparinized donor blood to a level just below the inner opening of the outflow tube (c).

B. Stainless steel lower end-plate with one outflow (c) and two inflow, (a) and (b), tubes. The inner openings of the latter are flush with the inner surface of the lower end-plate. The inner end of the outflow tube is 5 cm. higher. Only the left ventricular inflow tube (a) is connected in open-heart operations on the mitral valve where venous drainage is directly from the right ventricle instead of from the superior and inferior vena cava. The second inflow tube in such cases is closed with a short length of tygon tubing and metal stopper. The lower end-plate is fixed at ventricle level. When the pressure in the left ventricle rises above 5 cm., blood overflows into the outflow tube and drains by gravity into the cardiac sucker reservoir.

C. Tygon barrel.

Fig. 2. Posterior-cusp hook-knife which is used to make several stab incisions through the base of the posterior cusp from its ventricular aspect.

tained during the earlier digital exploration and by direct inspection of the valve should make it quite clear whether the anterior or posterior or even perhaps both cusps are to be reconstructed or whether annuloplasty alone or in

conjunction with cusp reconstruction is required.

Valvuloplasty is now performed. In a case of posterior-cusp incompetence an incision which extends almost completely from commissure to commissure, is made through the base of the posterior cusp. Often a short and retracted posterior cusp cannot be visualized at all at this stage. The incision through the 'bare' basal area of the cusp is then made from its ventricular aspect with the aid of a posterior-cusp hook-knife (Fig. 2).

A posterior-cusp clamp (Fig. 3A) is applied to the previously prepared pericardium and the proposed cusp, with




Fig. 3A. Posterior-cusp clamp. The clamp is applied to a portion of the pericardium from which the mediastinal pleura and small blood vessels have been removed, and the proposed cusp, its margins projecting  $\pm \frac{3}{16}$  inch or more beyond the outside edge of the clamp, is excised.

Fig. 3B. Anterior-cusp clamp.

its margins projecting  $\pm \frac{3}{16}$  inch or more beyond the outside edge of the clamp, excised. With the surgeon standing behind the patient, closely spaced 4-0 interrupted silk sutures are passed successively, first through that margin of the divided cusp to which the chordae tendineae are attached and then through the corresponding free margin of pericardium which projects beyond the right-sided edge of the posterior-cusp clamp. Each suture is held with a pair of mosquito forceps and the one ear of each forceps successively hooked in the correct serial order over the prong of a Mayo artery forceps safety-pin which has previously been fixed to the drapes by means of a towel clamp. These sutures are passed in a direction from the lateral towards the medial commissure. A second series of 4-0 interrupted sutures are now passed first through the left free margin of the pericardial cusp and thereafter through the mitral ring in a direction from the medial towards the lateral commissure. The free ends of these individual sutures are again held with mosquito forceps which are again hooked in the correct serial order over the prong of a second artery forceps safety-pin. The cusp clamp, which during the placing of the sutures is held just outside the lumen of the left atrium, is withdrawn and the sutures tied. Although about 30 sutures are placed along the margin of the cusp, there is, with this technique, no danger whatsoever of these sutures becoming entangled. All these sutures, before their insertion, are soaked in a solution of synthetic penicillin.

Anterior-cusp incompetence can be corrected in a very similar fashion. An anterior-cusp clamp (Fig. 3B) is used to determine the size and shape of the pericardial inlay into this cusp and to facilitate its insertion.

With the valvuloplasty completed, rewarming of the patient is started. The incision in the wall of the left atrium, excluding the original incision in the auricle, which is to be used later for re-exploring the valve, is closed with a continuous O-silk suture. With the atrium filled with blood, the base of the auricle is cross-clamped. The ventricular catheter is held vertically and allowed to fill with blood from the ventricle or filled with saline, thereby allowing air trapped in the ventricle to escape. The filled catheter is then reconnected to the decompression line and the clamp across the latter removed. Should ventricular fibrillation not spontaneously revert to sinus rhythm, defibrillation is instituted. With the oesophageal temperature at 37°C, the clamp across the pulmonary artery is removed. With the heart beating satisfactorily, the bypass is discontinued and the arterial, venous and decompression lines clamped off simultaneously. The mitral valve is explored once more through the unsutured opening in the left auricle. The wound in the auricle is sutured, the cannulae removed, and the ventricular wounds and the incision in the subclavian artery sutured. Polybrene is administered. Two intercostal drains are introduced and antibiotic solution injected into the pleural cavity and the chest wall closed in layers.

#### RESULTS

Pericardial reconstruction of the mitral valve has been carried out in 20 patients with mitral incompetence since 6 December 1961 (Fig. 4). Of these patients 9 were in persistent chronic congestive cardiac failure, 6 in intermittent chronic right heart failure, 1 in acute left heart failure (traumatic rupture of anterior cusp during closed mitral valvotomy 1 week earlier) and 4 complained chiefly of dyspnoea or fatigue. Eleven patients had atrial fibrillation and in 9 the rhythm was regular. Eleven were females and 9 males.

In 18 a murmur of gross incompetence and in 13 of marked stenosis could be heard. In no case was there evidence of significant aortic regurgitation. In 12 patients there was roentgenographic evidence of marked cardiomegaly and in 5 of these the cardio-thoracic ratio ranged between 80% and 85%.

The electrocardiograms were not of much value in assessing correctly the nature of the mitral valve lesion. Ten patients showed evidence of right-, 2 of left- and 2 of combined ventricular hypertrophy. The electrocardiograms of 6 patients did not show any evidence of ventricular hypertrophy at all; in view of the radiographic and operative findings, in relation to valve pathology and gross cardiac appearances in these cases, they indicate balanced biventricular hypertrophy.

Of 3 patients with gross cardiomegaly (cardio-thoracic ratio 84% - 85%) and more or less pure mitral insufficiency, 1 had definite right ventricular hypertrophy, 1 biventricular hypertrophy and 1 doubtful right ventricular hypertrophy. A fourth patient with very marked cardiac enlargement (CT ratio 85%) had a large ostium secundum atrial septal defect and pure mitral insufficiency with right ventricular hypertrophy, whereas a fifth case (CT ratio 80%) had a moderately severe degree of stenosis and gross

insufficiency with no electrocardiographic evidence of either right or left ventricular hypertrophy. It is probably significant to note that even in this small series the more severe degrees of cardiomegaly in 80% of cases resulted from more or less pure mitral insufficiency and that in none of these instances was there electrocardiographic

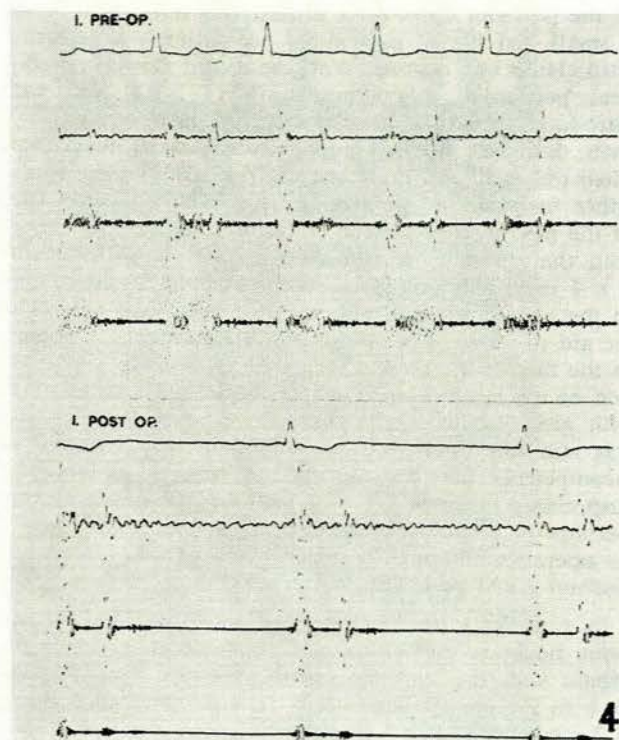


Fig. 4. Phonocardiograms of case 1 done pre-operatively and again 18 months after reconstruction of the posterior cusp with pericardium on 6 December 1961.

evidence of left ventricular hypertrophy. There was only 1 patient with a normal cardio-thoracic ratio. She, however, had gross mitral incompetence, without stenosis, and her electrocardiogram indicated the presence of left ventricular hypertrophy.

Right heart catheterization was done in 4 patients only. In 3 of these there was only slight cardiomegaly with moderate to severe pulmonary hypertension. All, however, had a severe degree of stenosis and incompetence. Three showed electrocardiographic evidence of right ventricular hypertrophy and 1 had a balanced electrocardiogram. Four patients had 1 or more previous closed mitral valvotomies and 1 patient an unsuccessful annuloplasty.

In 6 patients the valve on digital exploration and on direct inspection was completely or almost completely incompetent. In the remaining 14 the lesions were of varying degrees of combined stenosis and incompetence. In 1 case the lesion was predominantly stenotic, but severe incompetence was induced by closed mitral valvotomy. This was, however, anticipated and open-heart reconstruction of the posterior cusp could be done at the same time. In another patient, a boy aged 15, the anterior cusp was completely ruptured with a Tubb's mitral valve

dilator, and valvuloplasty could only be undertaken some days later.

In 17 cases the pericardial inlay was into the posterior cusp and in 3 into the anterior cusp. In the first 4 cases no cusp clamp was used and a portion of pericardium of no specific size or shape was sutured into the basal zone of the posterior cusp. As it proved very difficult to handle a small and flimsy portion of pericardium, a posterior-cusp clamp was devised. With the aid of this clamp elliptical pericardial inlays measuring  $1\frac{1}{2} \times 1$  inch were introduced into the posterior cusp in the next 7 cases. It soon, however, became apparent that such inlays were often too small and that commissural incompetence tended either to persist or to develop after such inlays. In each of the next 6 cases a large posterior cusp was constructed with the aid of a sausage-shaped cusp clamp measuring  $2 \times \frac{3}{8}$  inch. This size and shape proved highly satisfactory. In the next 2 cases an anterior cusp inlay was done with the aid of an anterior-cusp clamp measuring  $1\frac{1}{2} \times \frac{3}{8}$  inch. In the first of these cases this resulted in complete correction of the incompetence, but in the second, a child of 12 with gross cardiomegaly, the reconstructed anterior cusp was still too small and a moderately severe degree of incompetence persisted. In the last patient an anterior-cusp clamp measuring  $2 \times 1$  inch was employed and no incompetence could be felt digitally at the termination of the operation, although postoperatively a grade 1/6 systolic murmur could be heard.

In 6 patients no incompetence could be felt with an index finger in the left atrium at the termination of the bypass with the systemic systolic pressure more or less back to the pre-operative level. In 4 minimal, in 7 slight, in 2 moderate and in 1 severe incompetence persisted. The severe incompetence was due to a faulty technique in case 2; since no pericardial clamp was used the pericardial inlay was too small and difficult to handle, with the result that the medial half of the incision into the base of the posterior cusp could not be closed satisfactorily with pericardium. Otherwise the main cause for persistent incompetence was too small pericardial inlays. In the 2 patients with moderate postoperative incompetence (both children) the smaller posterior and anterior cusp clamps were employed.

In only 1 patient has there so far been evidence of a new development of incompetence postoperatively. This was in case 4 in whom a posterior cusp inlay was done without the use of a cusp clamp and in whom we were quite surprised to find no incompetence at the termination of the bypass owing to technical difficulties experienced in inserting the inlay as a flat sheet of tissue.

Seven of the 20 patients had very extensive valve calcification. Five of these patients died, 4 of them being in the first series of 10. In spite of the very severe degree of calcification 4 patients had no, 2 minimal and 1 slight postoperative incompetence.

Six of the first 10 patients died. In only 1 of these, however, was death due to an unsatisfactory operative result (the second case in the series). Staphylococcal endocarditis caused the death of 2 patients and a dissecting

aneurysm, which extended from the supra-avalvular region to a point beyond the origin of the renal arteries, was the cause of death in the fourth case. Postoperative bleeding was the major cause of death of a patient who had been subjected to 2 previous closed mitral valvotomies elsewhere and who had a pre-operative prothrombin index of 39% which would not respond to treatment. The sixth patient died very suddenly and unexpectedly on the first postoperative day, probably as a result of a calcific coronary artery embolism.

In the second 10 cases only 1 patient died. This was a man of 57 who also suffered from a severe degree of chronic bronchitis for which he received steroid therapy. His wound ruptured 1 day after the removal of his sutures. Cardiac arrest set in during the secondary suture of his wound from which he recovered after massage and defibrillation during a period of  $1\frac{1}{2}$  hours. Three days later, during endotracheal toilet via a tracheostomy tube, he collapsed and died.

#### SUMMARY

Some important aspects of the normal anatomy and of the pathological changes resulting from rheumatic endocarditis of the mitral valve are briefly outlined.

A left-sided approach, which gives the surgeon an excellent close range view of the mitral valve, is described.

The technique for treating mitral insufficiency by means of the functional correction of the morbid anatomy with pericardium is described in detail.

Twenty cases of mitral incompetence, so treated, are reported.

We wish to thank Drs. J. M. Combrink, W. H. Davis, and F. Ziady, of the Cardiac Unit, and Dr. L. F. Malherbe, of the Department of Medicine, University of Pretoria, for their assistance with the pre-operative investigations and postoperative care; Dr. P. N. Swanepoel, Medical Superintendent, Pretoria General Hospital, for his permission to publish these data; Mr. B. J. Badenhorst, our senior heart-lung machine technician, who made the prototype instruments used during these operations; and Mr. V. Hen-Boisen, who for several years has rendered valuable technical assistance in the animal laboratory and in the operating room in an honorary capacity.

#### REFERENCES

1. Barnard, C. N., Goosen, C. C., Holmgren, L. V. and Schrire, V. (1962): *Lancet*, **2**, 1087.
2. Doumanian, A. V. and Ellis, F. H. (1961): *J. Thorac. Surg.*, **42**, 683.
3. Du Plessis, L. A., Morrow, A. G. and Awe, W. C. (1963): *Med. Proc.*, **9**, 300.
4. Effler, D. B., Groves, L. K., Martinez, W. V. and Kolff, W. J. (1958): *J. Thorac. Surg.*, **36**, 665.
5. Frater, R. W. M. (1961): *Proc. Mayo Clin.*, **36**, 582.
6. Gott, V. L., DeWall, R. A., Gonzales, J. L., Hodges, P. C., Varco, R. L. and Lillehei, C. W. (1957): *Univ. Minnesota M. Bull.*, **29**, 69.
7. Kay, J. H., Egerton, W. S. and Zubiato, P. (1961): *Surgery*, **50**, 67.
8. Lower, R. R., Stofor, R. C. and Shumway, N. E. (1961): *J. Thorac. Surg.*, **42**, 696.
9. Nichols, H. T., Blanco, G., Uricchio, J. F. and Likoff, W. (1961): *Arch. Surg.*, **82**, 128.
10. Sauvage, L. R., Woods, S. J., Bill, A. H. and Logan, G. A. (1962): *J. Thorac. Surg.*, **44**, 67.
11. Starr, A. and Edwards, M. L. (1961): *Ibid.*, **42**, 673.
12. Van der Spuy, J. C. (1958): *Brit. Heart J.*, **20**, 471.
13. *Idem* (1960): Paper presented at the 2nd bi-annual meeting of the Southern African Cardiac Society, Cape Town, October.
14. *Idem* (1964): *S. Afr. Med. J.* (in the press).