

## IDIOPATHIC HYPOPARATHYROIDISM

S. GRIEVE, M.B., B.Ch., M.R.C.P.

L. SCHAMROTH, M.B., B.Ch., M.R.C.P.E., F.R.F.P.S.

*University of the Witwatersrand and Coronation Hospital, Johannesburg*

Idiopathic hypoparathyroidism is a rare disease. Drake, Albright, Baur and Castleman<sup>3</sup> fully described it in 1939. Only 50 or 60 proven cases (de Mowbray,<sup>2</sup> 1953) have been reported in the literature. As far as we know the following is the first reported case in an African.

### CASE REPORT

A 38-year old African female was admitted to Coronation Hospital, Johannesburg, on 28 October 1950, complaining of numbness and cramp-like pains in the hands and feet for the preceding 24 hours. She had also vomited several times during this period and had had hiccoughs for a few hours before admission. Apart from occasional palpitations there was no other significant history.

#### *Physical Examination*

The patient was moderately obese. She had typical carpo-pedal spasms. The Chvostek, Trousseau and Erb signs were all strongly positive. She was hypertensive, blood pressure being 180/120 mm. Hg, with a heaving cardiac impulse and a loud apical systolic murmur. The skin, hair and nails were normal. Both optic fundi were normal and no cataracts were noted. The thyroid gland was not palpable and there was no evidence of any previous operative procedure on her neck. The rest of the physical examination was negative.

#### *Laboratory Studies*

Haemoglobin 14.6 g.%. White cells 6,400 per c. mm. (differential count normal). Wassermann reaction negative. Serum alkali

reserve 57 vols.%. Blood urea 28 mg.%. Liver function tests normal. Plasma proteins 6.5 mg.%. Serum calcium 4.9 mg.%. Serum phosphorus 6.8 mg.%. (Numerous investigations showed a range of serum calcium from 4 to 6 mg.% and serum phosphorus from 6 to 8 mg.%)

Urea clearance test—89% of average normal renal function. Urinary concentration test—specific gravity up to 1022. Urine—N.A.D.; culture (numerous catheter specimens)—no growth.

Intestinal fat absorption—87% absorption of fat intake per day. Total stool solids analysis—29% fat, of which 19% was unsplit. No parasites found in the stools.

*Radiology.* Skull and long bones—N.A.D. Chest—markedly enlarged heart affecting chiefly the left ventricle. Intravenous pyelogram—no gross abnormality of the pelvis; excretion of the dye moderately good.

*Electrocardiography.* PR interval 0.16. Qt interval 0.4. QTc interval 0.52. T waves isoelectric in leads V 2, 3, 4 and 5.

#### *Treatment and Progress*

Initially 10 ml. of a 10% solution of calcium gluconate was given intravenously, followed by 10 g. of calcium lactate 3 times a day by mouth and 2 pints of milk plus 120,000 units of calciferol daily. This relieved the patient's symptoms but did not appreciably alter the biochemistry. Finally the daily administration of 3 ml. of A.T. 10 (dihydrotachysterol) produced a rapid restoration of the blood calcium and phosphorus levels to normal (Fig. 1).

The patient was discharged on a daily maintenance dose of a ½ to 1 ml. of A.T. 10. Her subsequent attendance at the outpatient department was extremely irregular and she was re-admitted

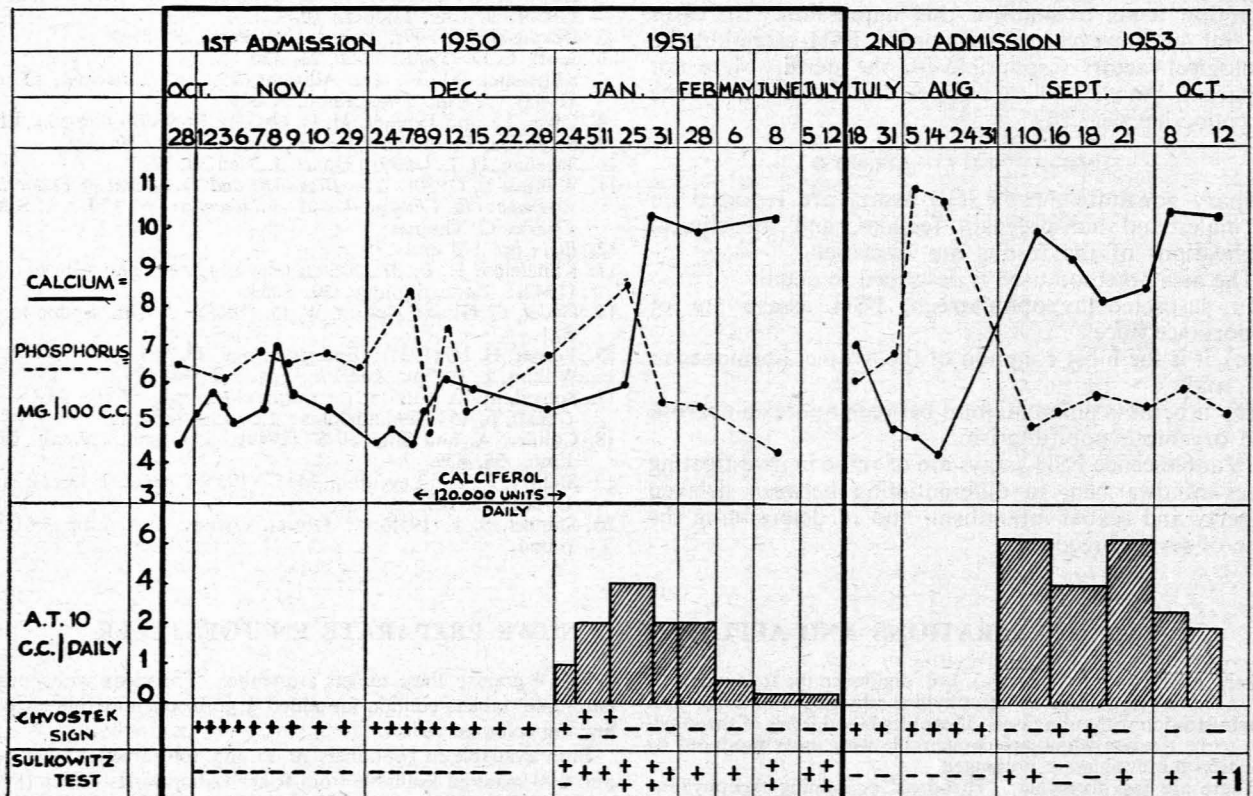


Fig. 1.

twice during the following 3 years, on the first occasion for treatment with hexamethonium compounds in an attempt to control her hypertension, which was unsuccessful.

#### READMISSION TO HOSPITAL

The patient was admitted to hospital for the 3rd time on 18 August, 1953 approximately 2½ years after the onset of her symptoms, on account of the return of her tetany, due mainly to neglect of therapy.

Examination revealed a similar clinical picture to that on her first admission, viz. marked carpo-pedal spasm with positive Chvostek and Trousseau signs. Vomiting and hiccough were again prominent. In addition she had early signs of congestive cardiac failure—engorged neck veins, moderate hepatomegaly and minimal peripheral oedema.

Further, the skin was now dry and had a peculiar texture which could best be likened to that of blotting paper. Distributed over the 'butterfly area' of the face were sharply demarcated, irregular patchy, brown pigmented areas. Bald patches were apparent on her head affecting chiefly the frontal and occipital regions. The hair was brittle and fell out easily. Her eyebrows and eyelashes had become thin and there was marked loss of axillary hair.

There was an almost mature cataract in the left eye and a very early lens change in the right eye.

During her stay in hospital she showed a peculiar mental state. She appeared depressed and gloomy. She had a perpetual frown on her face and did not converse with other patients. She answered questions in monosyllables.

#### Laboratory Studies

Haemoglobin 13.2 g.%. White cells 7,800 per c.mm. (differential count normal). Serum alkali reserve 47 vols.%. Chlorides (as NaCl) 540 mg.%. Sodium 333 mg.%. Potassium 14.3 mg.%. Chvostek and Trousseau signs. Vomiting and hiccough were present. Plasma proteins 6.5 g.%, (albumin 3.3 g., globulin 3.3 g., gamma-globulin 1.15 g.%). Blood urea 43 mg.%. Serum calcium 7.3 mg.%. Serum phosphorus 6.8 mg.%.

Urea clearance test—74% of normal function. Urinary concentration test—specific gravity up to 1022. Urine—N.A.D.; culture (catheter specimen)—no growth. P.S.P. excretion test—total excretion after 2 hours 4.4 mg. (73%). Ketosteroids—a 24-hour specimen of urine (2360 ml.) showed a total excretion of 4.5 mg. of 17 ketosteroids (estimated as dehydroandrosterone).

No clinical or laboratory evidence of moniliasis was found.

*Radiological examination* of the skull now showed a small area of calcification which had not been present on the patient's first admission. It was not in the region of the basal ganglia and probably represented a small area of calcification in the choroid plexus of the lateral ventricle.

An *electrocardiogram* again showed isoelectric T waves in leads V 4, 5, and 6. PR interval 0.16. QT interval 0.37. QTc interval 0.45.

An *electroencephalogram* (Dr. C. Mundy-Castle) revealed abnormalities of isolated focal sharp waves or spikes from the left temporal region, together with left-sided bursts of 7.9 c/sec. from the same area. Occasional right-sided temporal sharp waves were also seen. Hyperventilation evoked several generalized paroxysmal bursts of 6-7 c/sec. activity, one burst of 4 c/sec. activity and several bursts of 24 c/sec. This response is of doubtful normality.

*Ellsworth-Howard Test.* This test demonstrated a marked increase in the excretion of urinary phosphorus following injection of parathormone (see Fig. 2).

#### Treatment

On 1 September treatment with A.T. 10 was commenced. Three ml. was given twice daily with remarkable effect. In 7 hours the Chvostek and Trousseau signs had disappeared, and the Sulkowitch test became positive within 5 days.

The return of the blood calcium and phosphorus levels to normal confirmed the clinical improvement.

The patient now showed a marked improvement in her mental state. She became cheerful, co-operative and verbose and mingled freely with her fellow patients.

An *electrocardiogram* now showed a QT interval of 0.32 with T-wave inversion over V 5 and 6.

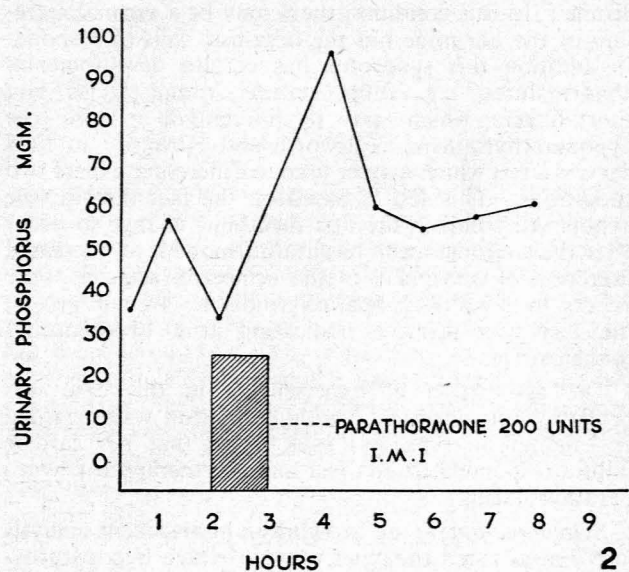


Fig. 2. Ellsworth-Howard Test.

Further, there was now no evidence of cardiac failure. She maintained her improvement as an out-patient on a maintenance dose of A.T. 10, the amount being based according to her requirements.

#### DISCUSSION

*Etiology.* Hypocalcaemic tetany may occur as a result of (1) deficient intake or absorption of calcium, (2) severe renal failure with phosphate retention and consequent reciprocal hypocalcaemia, or (3) hypoparathyroidism, usually due to operative removal of the parathyroid glands during thyroidectomy, or rarely idiopathic hypoparathyroidism.

This patient had an adequate intake and absorption of calcium as shown by absorption studies and stool examinations. Her renal function was moderately good and she had undergone no operation on the neck. Her repeated low blood-calcium and high blood-phosphorus reports, the ectodermal lesions, and her dramatic clinical and biochemical response to parathormone and A.T. 10, confirmed this as a case of idiopathic hypoparathyroidism.

The reason why all 4 parathyroid glands should cease to function is unknown. Sutphin, Albright and McCune<sup>9</sup> in 1943 reported 5 cases of idiopathic hypoparathyroidism associated with moniliasis. This may be purely coincidental or may be due to a predisposition of one disease for the other. It is interesting that Talbot, Butler and MacLachlan<sup>10</sup> in 1943 described 2 cases of moniliasis associated with Addison's disease; in one of them hypoparathyroidism was co-existent. The association of Addison's disease and idiopathic hypoparathyroidism has been noted by several observers and in 1946 was reviewed by Leonard,<sup>8</sup> who presented the clinical history and autopsy findings of one such case.

Albright *et al.*<sup>1</sup> in 1942 first reported 3 cases of an interesting condition which they termed 'pseudo-hypoparathyroidism—an example of Seabright-Bantam syn-

drome'. In this condition there may be a normal secretion of the hormone but the organism fails to respond. In addition this syndrome has certain developmental abnormalities, e.g. short stature, round facies and short fingers, which serve to differentiate it from true hypoparathyroidism. Ellsworth and Howard<sup>4</sup> in 1934 devised a test which may be used to differentiate these two conditions. This test is based on the fact that in true hypoparathyroidism the first metabolic change to occur after the administration of parathormone is an increased excretion of phosphate in the urine; no such response occurs in pseudo-hypoparathyroidism. In our patient the test was positive, indicating true hypoparathyroidism (Fig. 2).

The association of hypertension in this case was probably coincidental. The hypertension was regarded as essential in type and it is noted that her cardiac failure responded to bed rest and the therapy for hypoparathyroidism.

*Symptomatology:* de Mowbray<sup>2</sup> in his recent analysis of 57 cases listed the chief ways in which hypoparathyroidism may present as follows:

	Number of Cases	Percentage
Tetany .. .. .	40	70
Epilepsy or generalized convulsions ..	24	42
Laryngeal spasm .. .. .	5	9
Ectodermal lesions .. .. .	6	11
Failing vision due to cataracts ..	6	11

This case presents the majority of the classical features. Signs worthy of note were the marked manifestations of tetany, including hiccough and vomiting probably due to spasm of the diaphragm and pylorus respectively. On the first admission no ectodermal lesions were noted, but with the patient's failure to attend regularly as an out-patient over a period of 2½ years these ectodermal lesions appeared and were then a marked feature. Presumably the maintenance of correct out-patient therapy will prevent the progression of these lesions and possibly a regression. Learner and Brown<sup>7</sup> reported a case of extreme trophic changes in a patient with hypoparathyroidism; these changes appeared to have a seasonal incidence, appearing in January (winter) and disappearing in June (summer); on dihydrotachysterol therapy the tetany, ectodermal lesions, cheilitis and glossitis all disappeared, the loss of vision was arrested and no further loss of hair occurred.

The mental state of our patient is worthy of emphasis. On admission her depression and antagonism was striking. With the restoration of the serum calcium to normal levels she became cheerful, co-operative and sociable. Greene and Swanson<sup>6</sup> report similar symptoms. They list anxiety, depression, a sense of impending disaster and, in severe cases, delusions and hallucinations. Even suicide may be attempted. They report the prognosis as being good and recovery following the maintenance of a normal blood calcium level.

*Radiology.* Calcification in the basal ganglia and cerebellum occurs quite commonly in cases of hypoparathyroidism. In this case no such calcification was

noted. However, a small area of calcification appeared in the choroid plexus of the lateral ventricle which had not been there on the first admission.

*Electrocardiography.* The prolongation of the QT interval which was observed may occur in tetany from any other cause.

*Electroencephalography.* Gotta and Odoriz (1948)<sup>5</sup> describe (a) groups of abnormally slow waves, sometimes alternating with normal rhythm; (b) spikes; or (c) typical epileptic changes. This case showed abnormalities of focal sharp waves or spikes from the left temporal region.

*Treatment.* Parathormone is not used in the treatment of hypoparathyroidism. Its chief disadvantages are that owing to the fact that it is a foreign protein it leads to antihormone formation and resistance in the patient. It may give rise to reactions. (In this patient an intradermal injection of one minim of parathormone resulted in a moderate-sized wheal. The Ellsworth-Howard test had therefore to be modified; instead of 200 units of parathormone being injected intravenously, the same dose was given intramuscularly over the period of one hour.) Parathormone is also expensive and has to be given by injection.

Dihydrotachysterol (A.T. 10) is very effective for this condition. It is relatively inexpensive, it is taken by mouth, and it is easy to control.

The Sulkowitch reaction is a rough guide to treatment and is easy for patients to carry out on their own. However it is not an absolutely reliable guide, and regular blood calcium and phosphorus estimations should be carried out.

#### SUMMARY

1. A case of idiopathic hypoparathyroidism is described.
2. A brief summary of this clinical entity is given.

We should like to express our thanks to Dr. C. Mundy-Castle for the electroencephalographic report and to the South African Institute for Medical Research for the numerous laboratory investigations; also to Dr. V. D. Gordon, Superintendent of Coronation Hospital, for permission to publish this report.

#### REFERENCES

1. Albright, F., Burnett, C. H., Smith, P. H. and Parson, W. (1942): *Endocrinology*, **30**, 922.
2. de Mowbray, R. R. (1953): *Proc. Roy. Soc. Med.*, **46**, 291.
3. Drake, T. G., Albright, F., Baur, W. and Castleman, B. (1939): *Ann. Intern. Med.*, **12**, 1751.
4. Ellsworth, R. and Howard, J. E. (1934): *Bull. Johns. Hopk. Hosp.*, **55**, 296.
5. Gotta, H. and Odoriz, J. B. (1948): *J. Clin. Endocr.*, **8**, 895.
6. Greene, J. A. and Swanson, L. W. (1941): *Ann. Intern. Med.*, **14**, 1233.
7. Learner, N. and Brown, C. L. (1943): *J. Clin. Endocr.*, **3**, 261.
8. Leonard, M. F. (1946): *Ibid.*, **6**, 493.
9. Sutphin, A., Albright, F. and McCune, D. J. (1943): *Ibid.*, **3**, 625.
10. Talbot, N. B., Butler, A. M. and MacLachlan, E. A. (1943): *J. Clin. Invest.*, **22**, 583.