

MENINGITIS DUE TO *Listeria monocytogenes*: CASE REPORT

JOHN GANT, M.B., CH.B. (CAPE TOWN), M.R.C.P. (EDIN.)

and

DAVID MCKENZIE, M.MED. (PATH.), DIP. BACT. (L.S.T.M. & H.)

Departments of Medicine and Pathology, University of Cape Town, and Groote Schuur Hospital Cape Town

The organism *Listeria monocytogenes* is known to cause diseases which vary widely in their clinical presentation and occur in a wide variety of animals, including man. In 1926 Murray *et al.*¹ investigated the cause of death of a number of rabbits in Cambridge and from these animals they isolated a Gram-positive bacillus which when inoculated into rabbits produced as its most striking effect marked mononuclear leucocytosis. They found no report in the literature of a similar organism and they named the new microbe *Bacterium monocytogenes*. At the same time Harvey Pirie,² working in Johannesburg, was investigating a fatal disease of veld rodents (gerbilles). From these animals he isolated a Gram-positive bacillus and in his animal experiments he found liver necrosis to be the most prominent feature and, in honour of Lord Lister, he named this organism *Listerella hepatolytica*.

It was soon established that Murray and his colleagues in Britain and Harvey Pirie in South Africa had described

identical organisms. In 1940 the generic name was altered to *Listeria monocytogenes* and the term listeriosis is used to cover the different clinical pictures which may result from infection with this organism.

Human listeriosis is not rare but, to date, no case has been reported in this country. The discovery of a case in the Cape, presenting with meningitis, prompts this report.

CASE REPORT

C.S., a European male of 55 years, is from Swellendam, where he has lived for many years. He is a harness-maker and leather worker. His illness started in mid-November 1955, when he felt out of sorts, with vague generalized aches and, after a week, he consulted his doctor, who noted that his temperature was 99°F but found no specific abnormal signs. He was kept under observation for a week, during which time his temperature gradually rose to 103°F. He became dull and apathetic, the abdomen slightly distended and the liver enlarged. A diagnosis of typhoid fever was suggested, and blood for a Widal test was taken and chloromycetin prescribed. Within 48 hours the temperature came down to normal;

but after another 24 hours it rose again, although the antibiotic was still being taken. A day or two later a report was received that the Widal reaction was negative and on this account chloromycetin was discontinued. The man's condition remained virtually unchanged and no other antibiotic was prescribed. On 12 December the white-cell count was 18,000 and examination of a blood film showed a marked predominance of monocytes and lymphocytes with scanty neutrophil polymorphs.

His doctor stated that the patient had always been obese and pale and had a slightly myxoedematous appearance, but that he had never received treatment for this. In 1940 he had an attack of rheumatoid arthritis and since then had had occasional attacks of polyarthritis. He has 4 children, the youngest of whom is 11 years. For the past 8 years he has had little or no libido.

The patient was admitted to Groote Schuur Hospital, Cape Town for further investigation on 18 December.

He was obese and drowsy but could easily be roused. Herpes febrilis was present on the lips. There was no pigmentation and he was not jaundiced. The skin was dry and the eyebrows scanty but axillary and pubic hair were normal. The cardiovascular and respiratory systems were normal and the blood pressure was 105/75 mm. Hg. The liver was enlarged (3 fingers breadth below the coastal margin) and was firm, smooth and non-tender. The testes were slightly smaller than normal and were sensitive to pressure. Examination of the central nervous system revealed no localizing neurological signs but neck rigidity was present and Kernig's and Brudzinski's signs were positive.

Investigations

Blood. There was no anaemia. White blood-cells 14,000 per c.mm., polymorphs 42%, lymphocytes 56%. There were no atypical monocytes or lymphocytes suggestive of glandular fever.

Urine S.G. 1020. Albumin and urobilin present. Bile and sugar absent. On microscopy no abnormal constituents were seen.

Lumbar puncture. The cerebrospinal fluid was opalescent and under normal pressure. Protein 140 mg.%. Globulin ++. Chlorides 682 mg.%. Sugar Normal. Cells: polymorphs 1,100 per c.mm., lymphocytes 170.

Blood urea: 48 mg. %.

Serum proteins. Albumin 3.9 mg.%. Globulin 4.3 mg.%. Thymol turbidity 5.5. Thymol flocculation 3.

Serum bilirubin: 1.2 mg. %.

Agglutination and other tests. Paul Bunnell, Widal, Brucella, Weil Felix, and Weil's disease, all negative. Wassermann test of blood and cerebrospinal fluid, negative.

Liver biopsy Section showed a pronounced degree of haemachromatosis. There were no organisms demonstrable on a Gram-stained section.

Serum iron: 365 micrograms %.

Bacteriology of Cerebrospinal-Fluid

A Gram stain of a smear of the spun deposit of the first cerebrospinal fluid sent for examination showed numerous cells and scanty small Gram-positive bacilli distributed in widely separated clusters. On each of a blood-agar plate incubated at 37°C aerobically, and a boiled-blood-agar plate incubated at 37°C under CO₂, 3-4 colonies were present and proved to be small, Gram-positive, diptheroid-like organisms. Ziehl-Nielsen staining of the CSF showed no acid-fast bacilli.

Examination of a second cerebrospinal fluid yielded the same findings. In view of the unusual clinical features, and the CSF chemistry and bacteriology, the diagnosis of *Listeria* infection was mooted.

The organism grew aerobically and anaerobically on Hartley's agar and blood agar. The colonies on blood agar were small, greyish in colour and opaque, with a smooth convex surface and entire edge. On Hartley's agar they were somewhat less opaque. Haemolysis of the blood agar was present beneath the colonies and was more marked in the anaerobic culture.

Growth on McConkey's medium was minimal. A glucose-agar shake-culture showed no special features. Growth was obtained at 4°C and on media containing 6% NaCl. Growth in broth tended to be granular, the granularity disappearing as the deposit was shaken into the supernatant broth.

Hanging-drop examination for motility was positive and motility was confirmed in a Craigie tube.

Acid, but no gas, was produced after 24-hours incubation in dextrose, maltose, rhamnose and mannose. A small amount of acid was formed in sucrose, lactose and dextrin. The sucrose and lactose media were strongly acid after 6 days; there was no increase of acid in the dextrin.

No acid was formed in galactose or glycerol and the organisms failed to grow in Koser's citrate. There was no H₂S production and no hydrolysis of urea. The methylred reaction was positive and the Voges-Proskauer negative. Growth occurred in litmus milk with the formation of acid, but no clot or digestion. The catalase test was positive.

The organism was shown to be sensitive to chloromycetin, streptomycin, terramycin and ilotycin but not to penicillin or sulphatriad.

Six mice each received an intraperitoneal injection of 0.5 ml. of an overnight broth-culture. Three died within 48 hours and two more in 72 hours; the remaining one died after 6 days. The organism was recovered from the heart-blood, liver and spleen. At autopsy small scattered yellow areas were noted on the livers, and histologically these areas proved to be small areas of necrosis with a surrounding polymorphonuclear reaction. Gram-positive bacilli were demonstrated in these lesions.

At the same time 0.5 ml. of overnight broth-culture of the organism was injected intraperitoneally into 2 rabbits and 2 guinea pigs. Drops of culture were instilled into the eyes of the rabbits without scarification of the cornea. No keratitis developed nor did any of the animals show outward signs of illness. A differential leucocyte count performed on one rabbit was as follows:

	Total	Poly.	Mono.	Lympho.	Eosino.	Baso.	Absolute Monocyte Count
Before inoculation ..	4,500	8	0.5	84.5	6.5	0.7	24.5
4 days after inoculation ..	9,000	57	13	23	7	—	1,170
8 days after inoculation ..	6,400	32	1	66	1	—	64

Course and Treatment

The patient's temperature subsided spontaneously by 21 December. However, his general condition remained unchanged

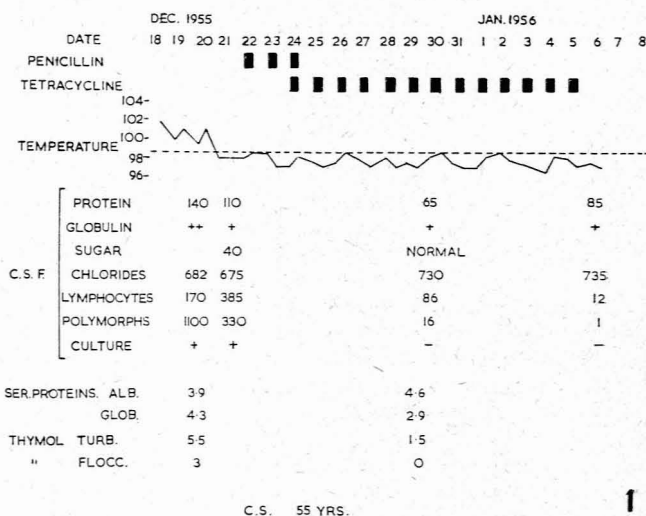


Fig. 1.

and, on 22 December, penicillin, which he received both intramuscularly and intrathecally, was prescribed. On 24 December the report on the sensitivity of the organism was received from the laboratory and, accordingly, penicillin was discontinued and tetracycline, in a dose of 250 mg. by the mouth 6-hourly, substituted. This was continued until 5 January 1956 while the patient made an uneventful recovery (see Fig. 1).

From specimens of cerebrospinal fluid taken on 19 and 21 December *Listeria monocytogenes* was isolated. A specimen taken on 30 December was sterile and showed considerable reduction in

the cell count, while the specimen taken on 6 January 1956 was virtually normal.

The serum proteins and liver-function tests which were abnormal on admission had reverted to normal 10 days later (see Fig. 1).

DISCUSSION

Listeria monocytogenes has been isolated from at least 27 different species of animal (including man), and its distribution is world-wide. The nature of the disease it causes may vary considerably from case to case within the same species and tends to vary in its manifestations from species to species. For instance, in ferrets infection results in an extremely mild illness which is little more than a carrier state, while in other species it may manifest as a meningo-encephalitis or generalized septicaemia with a very high mortality. It may present also as a focal necrosis of the liver, a genital-tract infection or, less commonly, a conjunctivitis, a myocarditis or a distemper-like illness.

Human listeriosis is not rare, but it has not previously been reported in South Africa. Murray³ has analysed the reported human cases and the following chart³ summarizes roughly the types of clinical presentations and the frequency with which they occur.

Clinical Presentation	Approximate %
Meningitis and meningo-encephalitis	33%
Granulomatosis infantiseptica	29%
Septicaemia	21%
Mononucleosis	8%
Conjunctivitis	6%

Granulomatosis infantiseptica is an intra-uterine infection of the newborn. The predominant feature of

this condition is extensive focal necrosis affecting especially the liver and, less often, the lungs. The mortality rate is very high. Occasionally meningitis may be associated with it. The organisms can be isolated from the affected areas in the child and frequently from the genital tract of the mother, who may or may not manifest the disease. Should she do so the mortality rate is low. This condition appears to have occurred most often on the continent of Europe and has been reported mainly from Germany.

SUMMARY

1. A case of meningitis due to *Listeria monocytogenes* is reported. No record of a similar case in South Africa has been found.
2. An incidental finding in this patient was the presence of haemachromatosis.
3. A brief review of the clinical manifestations of listeriosis in man is given.

This patient was referred to Groote Schuur Hospital by Dr. F. C. Malherbe of Swellendam and was admitted to Professor J. F. Brock's wards. Thanks are due to Professor Brock and to Dr. N. H. G. Cloete, Superintendent of Groote Schuur Hospital, for permission to publish the case. We are indebted to Dr. C. J. Uys for the histological reports and to Professor M. van den Ende, Head of the Department of Bacteriology, for advice.

REFERENCES

1. Murray, E. G. D., Webb, R. A. and Swann, M. B. R. (1926): *J. Path. Bact.*, **29**, 407.
2. Pirie, J. H. H. (1926-1928): *Publ. S. Afr. Inst. Med. Res.*, **3**, 163.
3. Murray, E. G. D. (1955): *Canad. Med. Assoc. J.*, **72**, 99.