

Better Clinical Diagnosis of Contraction of the Transverse Brim

D. CRICHTON

SUMMARY

The angle which the superior pubic rami make at the pubic symphysis is called the suprapubic angle.

If the size of the suprapubic angle is less than the described norm of 180° , the transverse diameter of the pelvic brim tends to be reduced. If, in addition, the shape of the suprapubic angle is angulated (Norman style) as opposed to arched (Roman style) the available transverse diameter is significantly less than the maximal transverse diameter, and the available true conjugate is less than the maximal true conjugate.

The clinical technique of measuring the suprapubic angle is described and its clinical importance emphasised.

Department of Gynaecology and Obstetrics, University of Natal and King Edward VIII Hospital, Durban

D. CRICHTON, M.B. CH.B., D.PHIL., F.R.C.S., F.R.C.O.G.

Date received: 13 July 1973.

Transverse brim contraction can be suspected by abdominal palpation.

The author's method of abdominovaginal estimation of pelvic size is held to be superior to the generally accepted single-handed method.

S. Afr. Med. J., 48, 781 (1974).

Consistent accuracy in the clinical measurement of pelvic size is unattainable. Even the most skilful and experienced clinicians make serious errors at times; hence their long-standing search for more accurate methods. Many have been tried; yet not one has proved perfect.

For instance, external pelvimetry to determine significant internal pelvic diameters was discredited about a quarter of a century ago.

It was radiological cephalopelvimetry which indirectly discredited external pelvimetry by proving that there is a

poor correlation in length between the intertuberous, intercrystal and external conjugate diameters measured by external pelvimetry and obstetrically significant internal diameters. The observer error by caliper measurement, especially in fat patients, also contributed to the misleading deductions often made from external pelvimetry.

Unfortunately, the hope that the new method of radiological cephalopelvimetry would provide obstetricians with a routine disproportion assessment service, proved ephemeral when the dangers from irradiation came to be appreciated, and a radiological forecast of the outcome of labour was shown not to depend solely upon the mere arithmetical ratio of head size to pelvic size.

More recently, new hopes were pinned on accurate ultrasonic measurements of the fetal head and pelvic size. Unfortunately, the apparatus is expensive, and a specially-trained staff is required to undertake the interpretations which are time-consuming. There are very serious limitations in that clinicians conducting a labour are unable to check the validity of the reports (which is feasible and valuable with radiographs), and no intrapartum guide is obtainable as in the case of intrapartum cephalopelvimetry.

This contribution will enable obstetricians to achieve greater *clinical* accuracy by palpation of the superior pubic rami.

SIGNIFICANT TRANSVERSE DIAMETERS OF THE PELVIC BRIM

It would detract from the essentially practical purpose of this contribution to cloud the issue by introducing complicated theoretical queries as to the precise level (or depth) of the transverse diameter which is measured on the pelvic brim view (or preferably planned brim view) of the pelvis radiologically. Yet it is essential to note the important difference between the available and maximal (or true) transverse diameter measurements in pelvises whose inlets are anthropoid or, especially, android in shape, since these shapes predominate in cases of disproportion.

The maximal transverse diameter is the largest transverse diameter which can be measured on the brim view of the pelvis, whereas the available transverse diameter is that which transects the midpoint of the true conjugate.

Usually the brim is not quite circular (gynaecoid) and the available transverse diameter lies slightly in front of the maximal transverse diameter, but the difference in length is trivial (Fig. 1). This is not so, however, in many patients who present with disproportion (especially among the Blacks), and where the brim is android and the available transverse diameter is considerably smaller than the maximal transverse diameter. Radiologists, however, rarely measure the available transverse diameter, despite proof of its greater significance (Fig. 1).

An interesting feature about the brim shape of android pelvises (especially among the Blacks) is that the illustrations in obstetric and radiological textbooks depict the so-called triangular shape with too generous a maximal transverse diameter and deficient invasion of the inlet area by the sacral promontory.

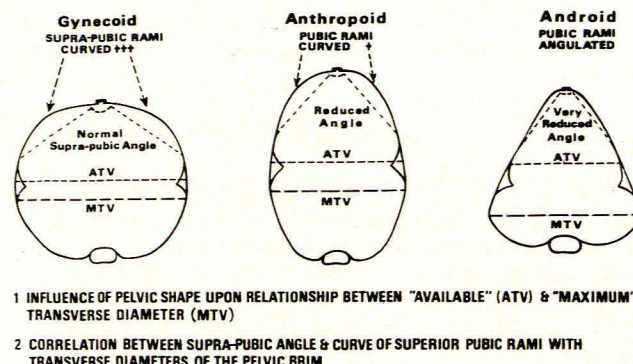


Fig. 1. The shape of the fore-pelvis.

THE SUPRAPUBIC ANGLE

The superior pubic rami flare back from the pubic symphysis at an angle which I have called the suprapubic angle. In a gynaecoid pelvis it measures about 160° , but it cannot be appreciated radiologically on the planned view of the pelvic brim which is commonly employed today to reduce irradiation (a full Thoms view of the pelvic brim being required), but the measurement is not of vital importance in radiological assessment of pelvic capacity.

On the other hand, it is the clinical measurement of this suprapubic angle which I find important, because the smaller the size of the suprapubic angle, the smaller is the transverse diameter; and the more angulated (as opposed to arched) the boundaries of the suprapubic angle, the smaller is the available, in relationship to the maximal, transverse diameter, and the smaller is the available true (obstetric) conjugate in relationship to the maximal true conjugate.

CLINICAL ESTIMATION OF THE SUPRAPUBIC ANGLE

Technique by Abdominal Palpation

With practice, the superior pubic rami and the suprapubic angle can be appreciated with ease when Paulic's grip is used, by pronating the hand slightly and allowing the fingers to slip down on to the anterosuperior aspect of the pubic rami. Thus, a right-handed person usually has his thumb on the right superior pubic ramus and the index and left fingers on the left. Appreciation of the suprapubic angle is enhanced by gently and slowly approximating and retreating these fingers along the anterosuperior surface of the superior pubic rami (Fig. 2).

In difficult, fat patients, confirmative palpation of the superior pubic rami may be helped by using the fingers of both hands (Fig. 3). Particular care must be exercised to differentiate the bony feel of the superior pubic rami from that of the inguinal ligament.

If the suprapubic angle is reduced, the clinician becomes aware of the probability of transverse brim contraction. Next, he must assess the shape of the boundaries of this

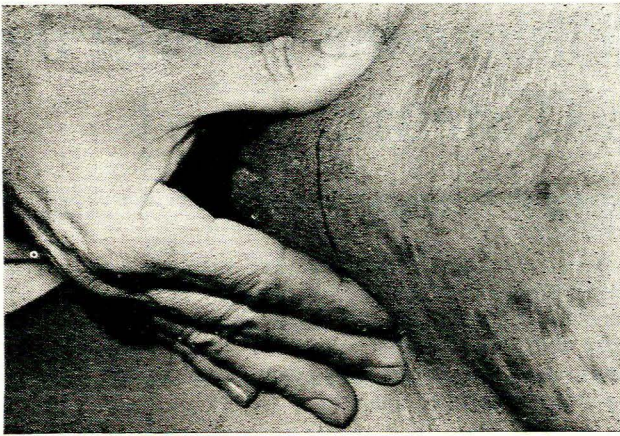


Fig. 2. Assessing the suprapubic angle.

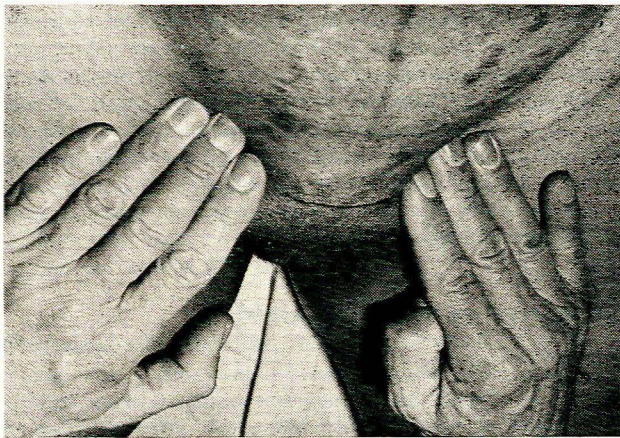


Fig. 3. Double-checking the suprapubic angle.

reduced angle, whether they are arched (like a Roman arch) or angulated (in Norman style), because the angulated reduction of the suprapubic angle should arouse an added suspicion that the available transverse diameter is considerably smaller than the true transverse diameter and further that the available conjugate is smaller than the true conjugate.

Technique of Estimating the Transverse Diameter of the Brim by Vaginal Examination

Obstetric textbooks rarely mention estimation of the length of the transverse diameter of the brim by vaginal examination, and never by abdominal palpation.

It is true that direct measurement of the transverse diameter of the pelvic brim is not feasible by actually spanning the diameter between 2 fingers in the vagina. Nevertheless, the author's method of combining abdominal palpation of the extremities of the superior pubic rami with vaginal examination of the extremities of the transverse diameter of the pelvic brim, permits a more valuable estimation, although not a direct measurement, to be made, whereas contraction has all too frequently been missed in the past (Fig. 4).

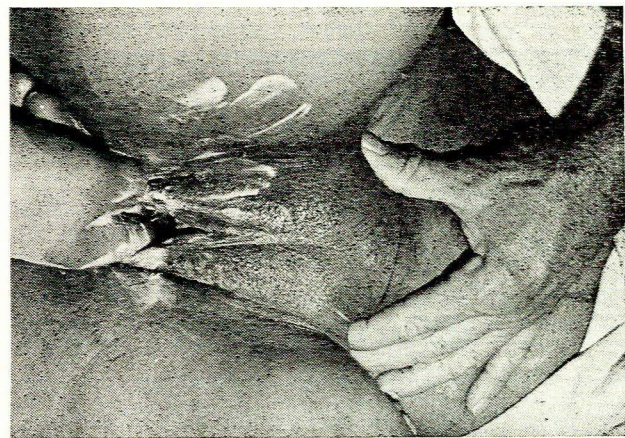


Fig. 4. Clinical evaluation of pelvic size by abdomino-vaginal examination.

This method of estimating the pelvic size by internal examination is not executed in the traditional single-handed manner, but is essentially an abdominovaginal procedure (Fig. 4). Similarly, attention during vaginal examination is not focused on anterior overlap alone, which is accepted practice, but also on anterolateral overlap.

REFERENCES

1. Crichton, D. (1962): *J. Obstet. Gynaec. Brit. Emp.*, 69, 366.