

The Ehlers-Danlos Syndrome in a Xhosa Male

R. PAMPHLETT, MATILDA M. NELSON

SUMMARY

A Xhosa male with the typical features of the Ehlers-Danlos syndrome is presented. This condition has not previously been described in an indigenous inhabitant of Southern Africa.

S. Afr. Med. J., 48, 741 (1974).

The Ehlers-Danlos syndrome is an uncommon, genetically determined disorder of connective tissue. Affected individuals have the unique stigmata of articular hypermobility in association with dermal fragility and extensibility.

Considerable morbidity results from a variety of complications and, in rare instances, sudden death may be the consequence of aortic dissection, spontaneous arterial rupture or intestinal perforation.

The majority of case descriptions have concerned Whites in Europe and the USA, although there have been sporadic reports from other parts of the world. To the best of our knowledge, the Ehlers-Danlos syndrome has not been previously recognised among the indigenous people of Southern Africa, and we therefore present this brief report of an affected Xhosa male.

CASE REPORT

A 20-year-old Xhosa male was seen in the genetic clinic at Groote Schuur Hospital in July 1973. He gave a history of repeated episodes of skin splitting after minor traumatic events. The lacerations gaped widely, but did not bleed to any extent. Surgical closure was difficult since the sutures tended to tear out of the wound edges and healing was usually slow. During late childhood a blow on his right thigh resulted in a massive haematoma, which was treated by aspiration. He had always been aware of the extreme laxity of his joints and was able to place his limbs in grotesque positions. He had never suffered a joint dislocation, but, because of his articular instability, he avoided lifting heavy objects. Venous varicosities in the lower limbs had become troublesome in early manhood but his general health was otherwise good.

He was born in the Transkei, and all his immediate family were still living there. Nothing is known of his perinatal history, but he was adamant that his younger sister, his parents and other members of the kindred were not similarly affected. There was no parental consanguinity.

The patient was 175 cm in height, weight 55 kg, and had normal bodily proportions. Wide, gaping papyraceous scars were present over the knees, shins and right thigh, while

irregular linear scars were scattered over the forehead. The skin was otherwise normal in appearance, but it had the quality of extreme extensibility and, over the elbow regions it could be stretched for more than 8 cm (Fig. 1). On release it sprang back.

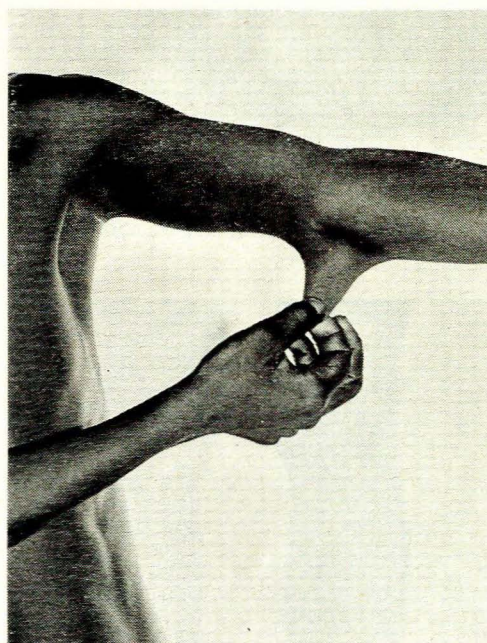


Fig. 1. Dermal extensibility.

The joints were extremely hypermobile, and the fingers could be passively hyperextended until their tips touched the dorsum of the hand (Fig. 2). The thumbs could easily be opposed to the forearms, the elbows hyperextended by 20°, the knee joints hyperextended by 15°, and the palms of the hand could be placed flat on the ground without flexion of the knees. These movements were entirely painless.

Numerous hard, shotty, subcutaneous spheroids could be palpated in the subcutaneous tissues of both shins. Marked pes planus and considerable varicosity of the veins of the lower legs were readily apparent (Fig. 3). Clinical examination was otherwise unremarkable and, in particular, no abnormality was detected in the eyes, teeth or nails. The cardiovascular, gastro-intestinal, respiratory and neurological systems were normal.

DISCUSSION

The Ehlers-Danlos syndrome is heterogeneous and at least 6 varieties may be identified.¹ Our patient's clinical features are consistent with those of the gravis form of the condition.²

Department of Human Genetics, University of Cape Town
R. PAMPHLETT, B.SC. (MED.), *Medical Student*
MATILDA M. NELSON, M.B. CH.B., M.R.C.P., D.C.H., *Senior Lecturer*

Date received: 29 October 1973.

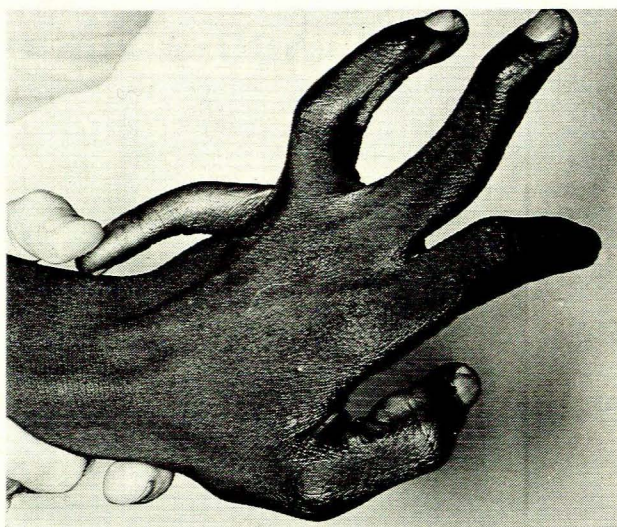


Fig. 2. Articular hypermobility.

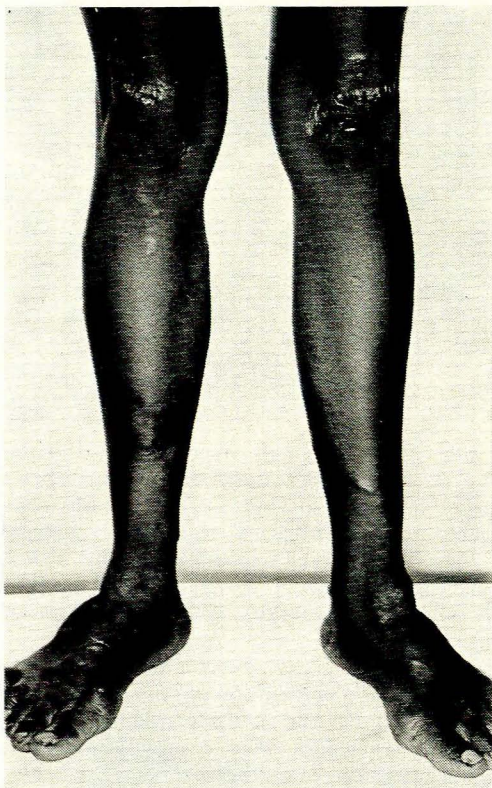


Fig. 3. Papyrus scars and pes planus.

Apart from skin splitting and haematoma formation, the patient's disorder has caused little ill health. However, his articular instability is a considerable handicap, as he is unable to do manual labour. Although his pes planus is of gross degree, his feet are painless, the only problem being a difficulty in obtaining shoes of suitable width.

Venous varicosities are a well-known feature of the gravis form of the Ehlers-Danlos syndrome and, due to the problems inherent in surgical management of the condition, they are not easy to treat.

The Ehlers-Danlos syndrome is inherited as an autosomal dominant trait, although an uncommon X-linked form has also been described. The patient's statement that no other members of his kindred are affected is not untoward, since mutation occurs relatively frequently, and the patient himself probably represents a new mutation of the gene. There is a 50% risk that any of his children, irrespective of their sex, will be affected.

Over 500 patients with the Ehlers-Danlos syndrome have been reported in the world literature. The majority of these were Whites in the USA or Europe, although cases have been described in Japan,³ India,⁴ Israel,⁵ Scandinavia,⁶ Korea,⁷ Russia⁸ and Cuba.⁹ The syndrome has also been observed in Negroes in the USA,^{10,11} but we have been unable to find any description of the condition in an indigenous inhabitant of Africa.

The minimum prevalence of the Ehlers-Danlos syndrome in England was estimated at 1 in 150 000, and in view of the number of affected Whites personally encountered in Southern Africa, it is reasonable to assume that the disorder has a similar prevalence in this ethnic group. If this gene frequency holds true for the indigenous Blacks, there would be more than 100 affected individuals. It would be possible to explain this apparent discrepancy on a basis of the condition not being diagnosed, by affected Blacks having a high mortality rate or by their 'fitness to reproduce', in the genetic sense, being reduced. However, the striking stigmata of the syndrome are unlikely to remain unrecognised, the mortality rate is not high and fitness to reproduce is not usually greatly impaired. It is therefore possible that there is a genuine difference in the frequency of the gene in the White and Black inhabitants in this country.

The geographical distribution of genetic disease is attracting increasing interest, and for this reason we present this case.

ADDENDUM

After the acceptance of our article, a report of a Black male with combined Ehlers-Danlos and Marfan's syndrome was published in this *Journal*.¹² The clinical features of this individual were suggestive of the Marfanoid hypermobility syndrome, an entity considered by McKusick¹ to be distinct from the true Ehlers-Danlos syndrome.

REFERENCES

1. McKusick, V. A. (1972): *Heritable Disorders of Connective Tissue*, 4th ed., p. 339. St Louis: C. V. Mosby.
2. Beighton, P. (1970): *The Ehlers-Danlos Syndrome*, p. 14. London: William Heinemann.
3. Araki, T. (1966): *Orthop. Surg. (Tokyo)*, **17**, 822.
4. Singh, S. D., Munjal, N. and Mansharamani, R. K. (1964): *Indian J. Pediat.*, **31**, 1.
5. Lewitus, Z. (1956): *Arch. Derm.*, **73**, 158.
6. Svane, S. (1966): *Acta orthop. scand.*, **37**, 49.
7. Min, H. K. and Lee, J. D. (1963): *Korean J. Intern. Med.*, **6**, 545.
8. Melnikov, S. A. and Gorbacheva, F. E. (1965): *Vestn. Derm. Vener.*, **1**, 83.
9. Aleman, E., Cazanar, D., Margolles, A. and Guernica, A. (1965): *Rev. Cuba Pediat.*, **37**, 35.
10. Bruno, M. S. and Narasimhan, P. (1961): *New Engl. J. Med.*, **264**, 274.
11. Madison, W. M. jun., Bradley, E. J. and Castillo, A. J. (1963): *Amer. J. Cardiol.*, **11**, 689.
12. Birkenstock, W., Louw, J. H., Maze, A. and Sladen, R. N. (1973): *S. Afr. Med. J.*, **47**, 2097.