

FOLLOW-UP OF PATIENTS WITH ARRHYTHMOGENIC RIGHT VENTRICULAR CARDIOMYOPATHY DYSPLASIA

Miroslav J Munclinger, Jai J Patel, Abdul S Mitha

Objective. The enlargement of data on the natural course and management of patients with arrhythmogenic right ventricular cardiomyopathy/dysplasia (ARVC/D).

Design. Retrospective and partly prospective observational study.

Setting. Cardiac Unit, Wentworth Hospital, Durban — the only unit in KwaZulu-Natal providing an arrhythmia and electrophysiology service.

Study population. Those included were: (i) patients referred for palpitations, unexplained syncope, or ventricular tachycardia and in whom ARVC/D was diagnosed according to multiple criteria; and (ii) family members of patients with ARVC/D in whom the disease was documented using the same criteria.

Main outcome and measurements. Diagnosis, management, morbidity and mortality were analysed.

Results. Twelve patients were diagnosed with ARVC/D over a period of 6 years. At the end of follow-up for 3.4 ± 3.2 years, 7 of them were well and alive on anti-arrhythmic medication, 2 were asymptomatic, and 3 had died. One death was sudden, 1 patient died due to left ventricular failure, and 1 patient died due to a low cardiac output syndrome 3 months after right ventricular isolation, i.e. the mortality rate was 25%. ARVC/D was found in all racial groups and was familial in 5 patients (42%). In all but one patient the correct diagnosis was not suspected by the referring institution, physician or cardiologist.

Conclusions. ARVC/D needs to be included into a differential diagnosis of unexplained syncope, palpitations, or ventricular tachycardia by all health service providers. Its management remains a complex challenge with varying results.

S Afr Med J 2000; 90: 61-68.

Cardiac Unit, Wentworth Hospital and University of Natal, Durban

Miroslav J Munclinger, MD, PhD

Jai J Patel, FCP

Abdul S Mitha, FRCP



Arrhythmogenic right ventricular cardiomyopathy/dysplasia (ARVC/D)¹ was defined as a syndrome in 1978;² however, data analysing the broad clinical spectrum of this disease and assessing different therapeutic modalities are still incomplete. Twenty years later general awareness of the disease has not spread satisfactorily and appropriate diagnosis and management has often been offered only to those patients who reach centres specialised in the management and treatment of rhythm disturbances.

The disease is characterised by a replacement of the myocardium of the right ventricle with fibrofatty tissue. The coexistence of fibrofatty tissue and surviving myocardium creates an environment for ventricular arrhythmias. It is an important cause of unexpected sudden death among young people, especially competitive athletes.³

ARVC/D has been reported in America, Europe, and Asia.^{4,6} Cases diagnosed and followed up at Wentworth Hospital, Durban within the last 6 years are reported here to complement existing data on the geographical distribution of ARVC/D and to enlarge the limited pool of data on clinical course and follow-up of patients afflicted with this condition.

PATIENTS AND METHODS

Patients were diagnosed as having ARVC/D according to criteria suggested recently.⁷ These criteria are based on structural abnormalities of the right ventricle, tissue characterisation of the right ventricle, electrocardiographic criteria, and family history. The presence of two major, one major and two minor, or four minor criteria is considered to be diagnostic.⁷

Patients were followed up in a general cardiology clinic, or later in a clinic focused on arrhythmias. The follow-up periods differed according to clinical needs but were a minimum of 1 year for all patients, with the exception of one patient (SC) who defaulted for 10 years. Standard facilities and methods were used for routine examinations. Signal-averaged ECG was done using software available in MAC15 (Marquette Electronics Inc). Echocardiographic examinations were done using a variety of equipment; in recent years they have been performed with Hewlett Packard Sonos 2500.

All angiographic investigations as well as biopsies were done via femoral access. A Mullins transseptal sheath was used for the manipulation of the biopotom in the right ventricle. Multiple sites were targeted and samples were routinely taken from the apical area of the right ventricle. The ventricular stimulation protocol used during electrophysiological studies involved drives of eight extrastimuli followed by up to three independently timed extrastimuli and bursts of fast ventricular pacing, both in the resting state and while on isoprenaline. Radiofrequency catheter ablation was attempted using catheters and ablators from Medtronic and EP Technologies.

Magnetic resonance imaging (MRI) was performed using either a Siemens 1.0 Tesla (St Aiden's Hospital, Durban) or a General Electric 1.5 Tesla (Wentworth Hospital, Durban). Right ventricular isolation in patient CK was performed by Professor U von Oppell at Groote Schuur Hospital, Cape Town.

Pharmacological treatment was empirically instituted in symptomatic patients. Tolerated ventricular ectopia has been considered 'acceptable', but if a recurrence of sustained ventricular tachycardia or frequent and symptomatic episodes of non-sustained ventricular tachycardias occurred, then the drug dose was either increased or the drug was changed. Electrophysiological studies were used to document ventricular tachycardia in patients without 12-lead ECG of clinical tachycardia and in some patients with infrequent episodes of ventricular tachycardia in order to assess the drug effect.⁸

RESULTS

Diagnosis of ARVC/D

Over the last 6 years 12 patients were diagnosed as having ARVC/D. The diagnostic features used for the final diagnosis are summarised in Table I. Eight patients were white, 2 were black and 2 were of Asian descent. Two of them were asymptomatic and were diagnosed only because of familial occurrence. The most frequent symptom was palpitations. As an index symptom syncope was observed in 2 patients (Table II). Spontaneous sustained or non-sustained ventricular tachycardias were documented in 9 patients and were inducible in all but 1 of the patients submitted to an electrophysiological study. More than one morphology of ventricular premature contractions (VPCs) or ventricular tachycardia were observed in 8 patients. None of our patients had clinical signs of right-sided congestive failure, but both patients who had clinical signs of left ventricular failure died (1 after arrhythmia surgery).

Follow-up

Patients were followed up for 3.4 ± 3.2 (0.5 - 12.8) years. All symptomatic patients were on anti-arrhythmic drugs (Table III). The majority of patients had tried various drugs over the years, but eventually stayed on amiodarone. Sotalol was usually attempted before amiodarone was started. The sudden death of patient LW was probably caused by a pro-arrhythmic effect of propafenone.

Catheter ablation was attempted twice in patient NL. Although ventricular stimulation induced two different morphologies of ventricular tachycardia, ablation of clinically relevant exercise-induced tachycardia originating in the right ventricular outflow tract was attempted. This tachycardia exited at the antero-septal aspect of the basal right ventricular outflow tract, i.e. in the area where we normally ablate idiopathic right ventricular outflow tract tachycardias, and its



Table 1. Diagnosis of arrhythmogenic right ventricular dysplasia

Patient	Structural RV abnormalities	Tissue characteristics	ECG	Arrhythmias	SAECG	Familial	Criteria
SC	A: global dilatation and hypokinesia E: global dilatation and hypokinesia	B: not performed MRI: FF infiltration	Epsilon wave Inverted T waves V1-4	SuVT/LBBB VPCs 13 000/24 h	Yes	No	2 major 3 minor
NL	A: localised dyskinesia E: no abnormalities	B: normal MRI: FF infiltration	Inverted T waves V1-4	SuVT/LBBB	No	No	1 major 2 minor
LW	A: not performed E: global dilatation and hypokinesia	B: not performed MRI: not performed	Epsilon wave Inverted T waves V1-4	SuVT/LBBB	NA	Yes	2 major 3 minor
MN	A: localised dyskinesia, mild global hypokinesia E: mild dilatation	B: FF infiltration MRI: NA	Inverted T waves V1-4	NSuVT, VPCs	No	No	2 major 1 minor
SA	A: limited dyskinesia E: prominent moderator band	B: myocarditis A: FF infiltration	Epsilon wave Inverted T waves V1-5	SuVT/LBBB VPCs 53 000/24 h	No	No	2 major 3 minor
KM	A: mild global dilatation, regional hypokinesia E: mild global dilatation	B: FF infiltration MRI: FF infiltration	Inverted T waves V1-4	VPCs/LBBB 12 000/24 h	No	Yes	1 major 4 minor
KC	A: not performed E: mild global dilatation	B: not performed MRI: FF infiltration	Normal	VPCs 2 000/24 h	NA	Yes	MRI 3 minor
MG	A: localised dyskinesia E: normal	B: FF infiltration MRI: FF infiltration	Epsilon wave Inverted T waves V1-4	SuVT/LBBB	Yes	No	2 major 3 minor
CK	A: global dilatation and hypokinesia E: global dilatation, prominent MB	B: hypertrophy MRI: FF infiltration	Epsilon wave Inverted T waves V1-4	NSuVT/LBBB VPCs 24 000/24 h	Yes	Yes	2 major 5 minor
FB	A: normal E: mild dilatation	B: FF infiltration MRI: FF infiltration	Epsilon wave Inverted T waves V1-2	NSuVT/LBBB	No	No	2 major 2 minor
TC	A: limited dyskinesia, mild global hypokinesia E: mild global dilatation, dilated RVOT, trabecular disarray	B: atrophy/hypertrophy, FF infiltration MRI: atrophy, FF infiltration	Normal	SuVT/LBBB	No	No	2 major 2 minor
CG	A: not performed E: mild dilatation, trabecular disarray	B: not performed MRI: possible FF infiltration, RV wall thinning	Borderline	NSuVT VPCs 3 500/24 h	NA	Yes	1 major 3 minor

* Confirmed at surgery and autopsy.

RV = right ventricle; SAECG = signal averaged ECG; A = angiography; E = echocardiography; RVOT = right ventricular outflow tract; B = myocardial biopsy; MRI = magnetic resonance imaging; FF = fibrofatty; NA = not available; SuVT = sustained ventricular tachycardia; LBBB = left bundle branch block morphology; VPCs = ventricular premature contractions; NSuVT = non-sustained ventricular tachycardia.

induction was isoprenaline-dependent. Both ablation attempts failed, probably because epicardial location of the substrate as the fibrofatty infiltration documented on the MRI scan involved the subepicardial area only.

Patient CK suffered from an extremely progressive course of the disease and died due to a low cardiac output state 1 year after his first symptom (syncope) and 3 months after a right ventricular isolation for uncontrolled ventricular tachycardias.

His case will be discussed elsewhere.

The third patient (MN) died more than 4 years after the diagnosis of ARVC/D was made. His ventricular tachycardia was controlled on sotalol. He also suffered from arterial hypertension and from atrial fibrillation that developed 2.4 years before his death. He was treated for pulmonary tuberculosis and was admitted with pleural effusion to another hospital 2 months before his death. We have failed to obtain



Table II. Clinical presentation and follow-up

Patient	Age	Sex	Follow-up (yrs)	Presentation	VT	EPS	VT/ EPS	VT/VPCs > 1 morph	Cardiac LV failure	Final outcome	
SC	20	M	12.8	Exercise-induced VT	Yes	No	No	Yes	Yes*	No	'Controlled' on amiodarone — recurrent breakthroughs of slow VT
NL	43	M	5.3	Syncope during exertion	Yes	Yes	Yes	Yes	Yes	No	No recurrences on amiodarone
LW	15	M	5.0	Palpitations	Yes	No	No	Yes	NA	No	SCD (pro-arrhythmic effect of propafenone?)
MN	45	M	4.6	Palpitations, presyncope	Yes	No	No	NA	Yes	Yes/LV	Died due to acute LV failure [†]
SA	29	M	2.5	Presyncope	Yes	Yes	Yes	Yes	Yes	No	'Controlled' on amiodarone and beta-blocker (frequent VPCs & NSuVT)
MG	30	M	2.2	Palpitations	Yes	Yes	No	No	No	No	VT controlled on amiodarone and atenolol [‡]
KM	23	M	2.0	Chest pain, family history	No	Yes	Yes [§]	Yes	No	No	Asymptomatic on beta-blocker
KC	15	M	2.0	Screening, family history	No	No	No	No	No	No	Asymptomatic, no medication
CK	19	M	1.4	Syncope on exertion	Yes	Yes	Yes	Yes	Yes	Yes/LV	Died 3 months after RV isolation due to low cardiac output
FB	38	F	1.2	Palpitations on exertion	Yes	Yes	Yes [§]	No	No	No	Minimal symptoms on amiodarone
TC	44	M	1.1	Palpitations, presyncope	Yes	Yes	Yes	Yes	No	No	No breakthrough on sotalol
CG	22	M	0.5	Screening, family history	No	No	No	Yes	No	No	Asymptomatic, no medication

* Angiographic LV ejection fraction 49%, echocardiographic LV ejection fraction normal.

† Patient suffered from pulmonary TB, arterial hypertension, and atrial fibrillation.

‡ Patient suffered from arterial hypertension.

§ Non-sustained monomorphic ventricular tachycardia.

VT = sustained ventricular tachycardia documented; EPS = electrophysiological study performed; VT/EPS = ventricular tachycardia induced during electrophysiological study; VPCs = ventricular premature contractions; morph = surface ECG morphology; LV = left ventricle or ventricular; M = male; F = female; NA = not available; NSuVT = non-sustained ventricular tachycardia.

Table III. Treatment

Patient	Drugs used (in chronological order)*	Other modalities
SC	Propranolol, mexiletine, amiodarone [†]	No
NL	Disopyramide, sotalol, amiodarone	Failed radio-frequency catheter ablation
LW	Mexiletine, procainamide, disopyramide, sotalol, amiodarone, propafenone	No
MN	Sotalol	No
SA	Sotalol & mexiletine, amiodarone, amiodarone & atenolol	No
KM	Acebutolol, sotalol, acebutolol	No
KC [‡]	—	No
MG	Propafenone, amiodarone, amiodarone & atenolol	No
CK	Sotalol, amiodarone, amiodarone & propranolol	AAI pacemaker, arrhythmia surgery: total RV isolation
FB	Beta-blocker, sotalol, amiodarone	No
TC	Propafenone, sotalol	No
CG [‡]	—	No

* Treatment was terminated either because of a breakthrough of ventricular tachycardia or because of uncontrolled and symptomatic ventricular premature contractions; pharmacological treatment summarises drugs administered by different physicians since presentation.

† Patient was asymptomatic for 10 years without any treatment after original presentation with recurrent ventricular tachycardia.

‡ Patients are asymptomatic — diagnosis established during family screening.

AAI = single chamber atrial; RV = right ventricle.



detailed data concerning the final period in that hospital; however, he was transferred to us in pulmonary oedema with severe left ventricular dysfunction and died a few hours after arrival. There were no signs of ischaemia and the impairment of left ventricular function was global without regional differences.

Since none of the patients in this study died of non-cardiac causes, the total cardiac mortality was 25%. Morbidity in symptomatic patients was high as all of them had to be on pharmacological treatment and all but one suffered from minor symptoms.

Left ventricular involvement

Left ventricular dysfunction was observed in 5 of 10 symptomatic patients. Two deaths were consequences of left ventricular failure, although causes other than ARVC/D cannot be excluded in one of our patients who died. Old chronic fibrotic changes in the left ventricle were found in the second patient who died after right ventricular isolation.

DISCUSSION

Diagnosis

An appropriate diagnosis of ARVC/D has been restricted to the academic cardiology unit, as the correct diagnosis was suspected by the referring physician or cardiologist in only 1 of the 12 cases reported here. The incidence of ARVC/D is not known, but it has been shown to cause about 20% of sudden deaths in people aged 20 - 40 years.⁹ As a cause of sudden death in this age group it may be as frequent as myocarditis, pulmonary embolism and aortic dissection together.¹⁰ Despite these facts ARVC/D is often overlooked. As shown in our small group, the disease must be suspected in all racial groups. The imbalance observed by ourselves is most likely owing to varying access to health services rather than racial differences. The incidence of familial disease (42%) in this study was similar to findings of others,¹¹ and underlines the importance of appropriate screening.

ARVC/D should be suspected in all patients presenting with palpitations, unexplained syncope or ventricular tachycardia, especially if they are young and their symptoms are related to exertion or excitement. Ventricular arrhythmias present with left bundle-branch morphology (Fig. 1), and echocardiography documents either a normal heart or right ventricular abnormalities. The differential diagnosis from benign right ventricular outflow tract tachycardia in those without significant right ventricular abnormalities may require extensive investigation.

Evidence of structural and/or functional abnormalities of the right ventricle is crucial in establishing a diagnosis of ARVC/D. Echocardiography is extremely important for primary suspicion, and a detailed analysis of right ventricular anatomy

and function should be an organic part of echocardiographic investigation of any young person with unexplained syncope or ventricular tachycardia. However, angiography remained the decisive method for establishment of right ventricular anatomy and function in our patients. Echocardiographic features¹² failed to discover limited right ventricular dyskinesia that is highly specific for the diagnosis of ARVC/D^{13,14} in 5 patients (NL, MN, SA, MG and KM). Lack of facilities for dynamic assessment of MRI in our institution meant that it was not possible to compare MRI with angiography.

Tissue characteristics are also crucial to the diagnosis. An endomyocardial biopsy was performed in 8 patients and only 1 showed normal myocardium.¹⁵ The presence of adipose cells or tissue in endomyocardial samples was found in 5 patients, while other abnormalities were documented in 2 (Table I). A high number of positive findings among our patients was probably related to our technique. We sampled not only the septum, but also the apicoseptal and apical area of right ventricle, i.e. in one of the locations of the 'triangle of dysplasia'. No complications were observed. MRI was extremely helpful once some experience was gained, and an unequivocal finding of T1-hyperintensity within the right ventricular free wall, trabecules and/or interventricular septum was typically found in patients who were diagnosed according to the recommended criteria.⁷ MRI was not used as a diagnostic criterion in the reported group, with one exception. We did not feel that a myocardial biopsy and/or angiography was indicated in the completely asymptomatic patient KC.

Electrocardiographic findings were typical, as reported before¹ (Fig. 1). Only one patient with an abnormal right ventricle and ventricular tachycardia had a normal resting ECG (TC). The presence of multiple morphologies of ventricular tachycardia and/or frequent ventricular premature contractions in 8 of 9 patients with documented ventricular arrhythmia illustrates the complexity of arrhythmogenic substrate and the difficulties that are inevitable if radiofrequency catheter ablation and/or limited arrhythmia surgery are used in management.¹⁶⁻¹⁹

Treatment and prognosis

It is surprising that despite widely publicised results of trials documenting risks of class IC anti-arrhythmic drugs in patients with structural heart disease,²⁰ 2 patients were started on empirical propafenone before referral to Wentworth Hospital in 1995 and 1996 respectively. The use of class I anti-arrhythmic drugs in ARVC/D is controversial. Monotherapy may be extremely dangerous;²¹ however, class I anti-arrhythmic drugs are still used in combination with class III drugs in some countries, e.g. in the UK. At the end of follow-up occasional palpitations were reported by all patients and were documented as VPCs or short runs of non-sustained ventricular tachycardia in some patients. Despite the fact that

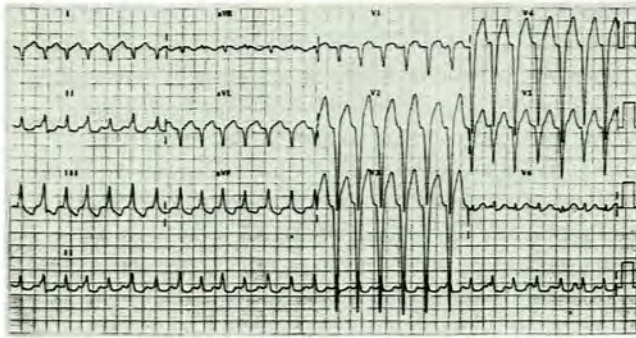
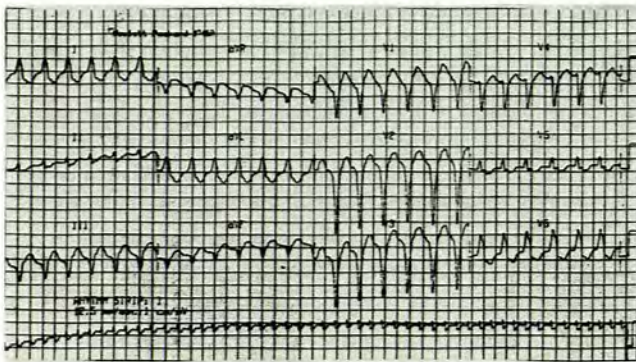
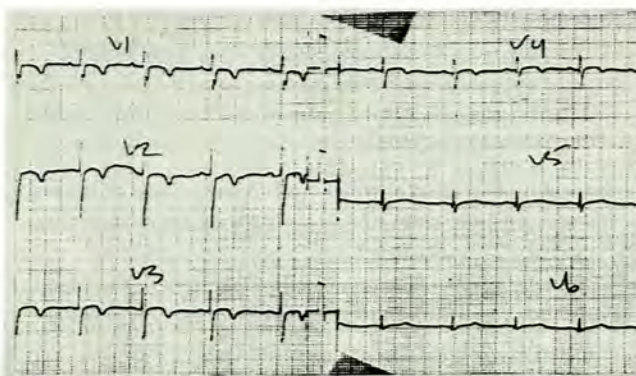


Fig. 1 Typical ECG patterns of ARVC/D.
1a. Ventricular tachycardia originating in the right ventricular outflow tract. Broad QRS tachycardia (165 beats/min) with atypical LBBB morphology (lateral precordial leads are not predominantly positive) and right frontal electrical axis. There is no obvious A-V dissociation. These ECG patterns may be documented in both benign right ventricular outflow tract tachycardia and ARVC/D.



1b. Ventricular tachycardia originating in the right ventricular apical area. Broad QRS tachycardia (150 beats/min) with LBBB morphology and left frontal electrical axis. The right-to-left septal activation and left frontal axis suggest that the arrhythmia originates in the right ventricular apical area, i.e. in one of the locations of the 'triangle of dysplasia'.



1c. Sinus rhythm. Abnormalities typical of ARVC/D in the sinus rhythm should be sought in precordial leads. The length of depolarisation in V1 and V2 may be prolonged, as in this ECG, and/or an abnormal terminal deflection of QRS (epsilon wave) may be observed in leads V1 or V2. The most frequent repolarisation changes are flat or inverted T waves in leads V1-3 (V1-4 in this recording).

no complete control of symptoms has been achieved in reported patients we feel that the empirical pharmacological treatment was satisfactory, except in the case of patient LW. His death was at least partly caused by poor compliance. Psychological problems may have played a significant role, as in the case of his sister who succumbed to the disease while avoiding medical care and in the two suicides reported by Marcus.⁴ Psychological factors are especially prominent in young patients from families that have lost other young members to the disease.

In general, class I anti-arrhythmic drugs should be avoided. Beta-blockers are useful as they suppress adrenergic activity that often triggers an arrhythmia; however, they should not be used as monotherapy in a patient with ventricular tachycardia. Sotalol and amiodarone are the mainstream drugs used in the management of ARVC/D. If they fail, then all other available therapeutic modalities such as catheter ablation, implantable cardioverter/defibrillator, or surgery (right ventricular isolation) must be considered in order to limit the arrhythmic risk.

The mortality rate during 3.4 ± 3.2 years was 25%. There was one sudden death and two deaths due to left ventricular failure. Although in one of them the cause of death was not established beyond doubt, the fast progression of left ventricular failure was similar to that seen in certain other patients with ARVC/D.²² We believe that the cause of death in the second patient was a latent left ventricular involvement that manifested after right ventricular isolation. The relatively poor prognosis in this series probably reflects underdiagnosis and referral of only the most serious cases to a tertiary centre.

Mortality differs significantly among published studies (Table IV). None of the published reports is really prospective and the duration of follow-up varies. Furthermore, the numbers reported are rather low, with one or two deaths changing the statistics significantly. There may also be doubts regarding the diagnosis in some cases, as the inclusion of patients with idiopathic right ventricular outflow tract tachycardia cannot be excluded. Despite the above it is obvious that ARVC/D has a significant mortality. Moreover, the morbidity is also very significant. It is difficult to analyse morbidity from available literature; however, an attempt is made in Table IV. Wherever possible we tried to establish the number of patients who suffered from a recurrence of ventricular tachycardia or cardiac failure during follow-up; this was observed in 9 - 67% and 0 - 25% of cases respectively.

A very interesting aspect is temporary spontaneous suppression of tachycardia. This was observed for 10 years in our patient SC despite the fact that his right ventricular cardiomyopathy/dysplasia had progressed significantly over that period. A similar phenomenon of clinical ventricular tachycardia disappearance was observed in 4 patients in Leclercq and Coumel's report.²³



Table IV. Review of follow-up of patients with ARVC/D (% in brackets adjusted for unavailable data)

Authors	Patients (N)	FU (yrs)	VT recurrence	CHF (N)	LVF (N)	TPL (N)	Mortality		Post surgery	Total
							SD	CF		
Blomstrom-Lundqvist + Sabel ⁵	15	1.5 - 28	10 (67)	3 (20)	0	0	2(13)	0	0	3 (20)
Leclercq + Coumel ²³	58	8.8 ± 7.2	NA	NA	0	0	1 (2)	2 (3.5)	1 (2)	5 (9)
Marcus <i>et al.</i> ⁴	33	3.9 - 8.4	3 (9)	7 (21)	1 (3)	0	2(6)	2 (6)	1 (3)	9*(27)
Lemery <i>et al.</i> ²⁴	12	2.5 - 15	7 (58)	0	0	0	0	0	1 (8)	1 (8)
Wichter <i>et al.</i> ⁸	64	0.2 - 8.6	7 (11)	0	0	0	0	0	0	0
Canu <i>et al.</i> ²⁵	22	10.7	6 (29)	4 (18)	0	0	3 (14)	0	0	5* (23)
Daubert <i>et al.</i> ²⁶	74	5.7 ± 3.75	17 (67)	NA	NA	0	1 (1.4)	0	1 (1.4)	2 (2.7)
Pinamonti <i>et al.</i> ²⁷	43	1 - 23	NA	9 (21)	1 (2)	1 (2)	3 (7)	5 (12)	0	8 (19)
Kullo <i>et al.</i> ²⁸	20	1 - 15	3 (15)	5 (25)	0	2 (10)	2 (10)	1 (5)	0	4 (20)
This report	12	0.5 - 12.8	5 (42)	0	2 (16)	0	1 (8)	1 (8)	1 (8)	3 (25)
Total	353	2 - 10.7	58 (19)	28 (13)	4 (1.4)	3 (0.8)	15 (4.2)	11 (3.1)	5 (1.4)	40 (11.3)

* One patient died during catheter ablation and two committed suicide.

† Two patients were lost to follow-up.

FU = follow-up; VT = ventricular tachycardia; CHF = congestive heart failure; LVF = left ventricular failure; TPL = heart transplant; SD = sudden death; CF = cardiac failure; NA = not available.

Patient CK had uncontrolled symptoms and succumbed to the disease in less than 2 years. There is no doubt that the right ventricular isolation played a significant role in the progression of left ventricular dysfunction, which emphasises the need to refine indications for different therapeutic approaches in different subgroups. Although some reports on right ventricular isolation are very promising and show no mortality,¹⁸ other results suggest that left ventricular involvement may be a risk factor for arrhythmia surgery.¹⁹ Death after arrhythmia surgery was reported in half the follow-up studies analysed (Table IV).

A better understanding of the pathobiology of the disease is necessary as the differences among patients and reported studies may be based on genetic differences^{29,30} or on different insults causing and/or triggering the progression of ARVC/D. It is hoped that more understanding of ARVC/D will be derived from prospective international registries (e.g. the US arrhythmogenic right ventricular dysplasia registry, PO Box 245037, Tuscon, Arizona 85724-5037, USA).

In conclusion, ARVC/D occurs in the spectrum of cardiac disorders among all groups of the South African population, and all indicated cases should be screened. Our experience confirms that ARVC/D has a significant morbidity and mortality and that more insight into the pathogenesis and progression of the disease is necessary.

We thank the staff of our unit, especially the clinical technologists and nurses who took part in investigation and follow-up of patients with ARVC/D. Special thanks to Dr D D Royston of the Department of Radiology, Wentworth Hospital, Durban for analysing most of the MRI scans.

This paper was presented during the 21st Biennial Congress of the Southern Africa Cardiac Society in Durban, 22 - 25 September 1998.

References

- Marcus FI, Fontaine G. Arrhythmogenic right ventricular dysplasia/cardiomyopathy: a review. *Pacing Clin Electrophysiol* 1995; **18**: 1298-1314.
- Frank R, Fontaine G, Vedel J, *et al.* Electrocardiologie de quatre cas de dysplasie ventriculaire droite arythmogene. *Arch Mal Coeur Vaiss* 1978; **71**: 963-972.
- Corrado D, Thiene G, Nava A, Rossi L, Pennelli N. Sudden death in young competitive athletes: Clinicopathologic correlations in 22 cases. *Am J Med* 1990; **89**: 588-596.
- Marcus FI, Fontaine GH, Frank R, Gallagher JJ, Reiter MJ. Long-term follow-up in patients with arrhythmogenic right ventricular disease. *Eur Heart J* 1989; **10**: Suppl D, 68-73.
- Blomstrom-Lundqvist C, Sabel KG. A long term follow up of 15 patients with arrhythmogenic right ventricular dysplasia. *Br Heart J* 1987; **58**: 477-488.
- Aizawa Y, Funazaki T, Takahashi M, *et al.* Entrainment of ventricular tachycardia in arrhythmogenic right ventricular tachycardia. *Pacing Clin Electrophysiol* 1991; **14**: 1606-1613.
- McKenna WJ, Thiene G, Nava A, *et al.* Diagnosis of arrhythmogenic right ventricular dysplasia/cardiomyopathy. *Br Heart J* 1994; **71**: 215-218.
- Wichter T, Borggrete M, Haverkamp W, Chen X, Breithardt G. Efficacy of antiarrhythmic drugs in patients with arrhythmogenic right ventricular disease. *Circulation* 1992; **86**: 29-37.
- Thiene G, Nava A, Corrado D, Rossi L, Pennelli N. Right ventricular cardiomyopathy and sudden death in young people. *N Engl J Med* 1988; **318**: 129-133.
- Loire R, Tabib A. Unexpected sudden cardiac death. An evaluation of 1 000 autopsies. *Arch Mal Coeur Vaiss* 1996; **89**: 13-18.
- Nava A, Thiene G, Canciani B, *et al.* Familial occurrence of right ventricular dysplasia. A study involving nine families. *J Am Coll Cardiol* 1988; **12**: 1222-1228.
- Kisslo J. Two-dimensional echocardiography in arrhythmogenic right ventricular dysplasia. *Eur Heart J* 1989; **10**: Suppl. D, 22-26.
- Daubert C, Descaves C, Foulgoc JL, Bourdonnec C, Laurent M, Gouffault J. Critical analysis of cineangiographic criteria for diagnosis of arrhythmogenic right ventricular dysplasia. *Am Heart J* 1988; **115**: 448-459.
- Blomstrom-Lundqvist C, Selin K, Jonsson R, Johansson SR, Schlossman D, Olsson SB. Cardioangiographic findings in patients with arrhythmogenic right ventricular dysplasia. *Br Heart J* 1988; **59**: 556-563.
- Peters S, Davies MJ, McKenna WJ. Diagnostic value of endomyocardial biopsies of the right ventricular septum in arrhythmias originating from the right ventricle. *Jpn Heart J* 1996; **37**: 195-202.
- Shoda M, Kasanuki H, Ohnishi S, Umemura J. Recurrence of new ventricular tachycardia after successful catheter ablation in patients with arrhythmogenic right ventricular dysplasia. *Circulation* 1992; **86**: suppl 1, 1-580.
- Haverkamp W, Borggrete M, Chen X, *et al.* Radiofrequency catheter ablation in patients with sustained ventricular tachycardia and arrhythmogenic right ventricular disease. *Circulation* 1993; **88**: suppl 1, 1-353.
- Nimkhedkar K, Hilton CJ, Furniss SS, *et al.* Surgery for ventricular tachycardia associated with right ventricular dysplasia: disarticulation of right ventricle in 9 of 10 cases. *J Am Coll Cardiol* 1992; **19**: 1079-1084.

19. Misaki T, Watanabe G, Iwa T, *et al.* Surgical treatment of arrhythmogenic right ventricular dysplasia: long-term outcome. *Ann Thorac Surg* 1994; **58**: 1380-1385.
20. CAST Investigators. Preliminary report: Effect of encainide and flecainide on mortality in a randomized trial of arrhythmia suppression after myocardial infarction. *N Engl J Med* 1989; **321**: 406-412.
21. Scott Millar RN, Lawrenson JB, Milne DA. Normal left ventricular function does not protect against propafenone-induced incessant ventricular tachycardia. *S Afr Med J* 1993; **83**: 256-259.
22. Pinamonti B, Miani D, Sinagra G, Bussani R, Silvestri F, Camerini F. Familial right ventricular dysplasia with biventricular involvement and inflammatory infiltration. *Heart* 1996; **76**: 66-69.
23. Ledercq JF, Coumel P. Characteristics, prognosis and treatment of the ventricular arrhythmias of right ventricular dysplasia. *Eur Heart J* 1989; **10**: Suppl D, 61-67.
24. Lemery R, Brugaga P, Janssen J, Cheriex E, Dugernier T, Wellens HJ. Nonischemic sustained ventricular tachycardia: clinical outcome in 12 patients with arrhythmogenic right ventricular dysplasia. *Am Coll Cardiol* 1989; **14**: 96-105.
25. Canu G, Atallah G, Claudel JP, *et al.* Prognosis and long-term development of arrhythmogenic dysplasia of the right ventricle. *Arch Mal Coeur Vaiss* 1993; **86**: 41-48.
26. Daubert C, Vauthier M, Mabo P, Laurent M, de Place C, Foulgoc JL. Long term prognosis of arrhythmogenic right ventricular disease: follow-up of 74 patients. *Am Coll Cardiol* 1994; **23**: Abstr. Suppl, 203A.
27. Pinamonti B, Lenarda AD, Sinagra G, Silvestri F, Bussani R, Camerini F. Long-term evolution of right ventricular dysplasia-cardiomyopathy. *Am Heart J* 1995; **129**: 412-415.
28. Kullo IJ, Edwards WD, Seward JB. Right ventricular dysplasia: The Mayo Clinic experience. *Mayo Clin Proc* 1995; **70**: 541-548.
29. Rampazzo A, Nava A, Erne P, *et al.* A new locus for arrhythmogenic right ventricular cardiomyopathy (ARVD2) maps to chromosome 1q42-q43. *Hum Mol Genet* 1995; **4**: 2151-2154.
30. Severini GM, Krajcinovic M, Pinamonti B, *et al.* A new locus for arrhythmogenic right ventricular dysplasia on the long arm of chromosome 14. *Genomics* 1996; **31**: 193-200.

Accepted 6 June 1999.