

Detection of human papillomavirus DNA with *in situ* hybridisation in oral squamous carcinoma in a rural black population

Estrelita Janse Van Rensburg, Willem F. P. van Heerden, Estelle H. Venter, Erich J. Raubenheimer

Intra-oral carcinoma is the third most common malignancy among men in developing countries, and carries a high mortality rate, particularly in Africa, where patients often present initially with lesions at an advanced stage. The present study was undertaken to determine the prevalence of human papillomavirus (HPV) DNA in oral squamous carcinoma in the west of the Northern Transvaal, an area where a large number of new cases has been diagnosed over the past few years. Paraffin blocks from 66 cases (51 men, 15 women; mean age 58,7 years) of oral squamous carcinoma were randomly selected. Blocks contained samples of both tumour and adjacent normal epithelium. The presence of HPV antigen was established by means of immunocytochemistry and HPV DNA by *in situ* hybridisation with radiolabelled probes for HPV-6, 11, 16 and 18. Immunocytochemistry for viral antigen was negative in all the specimens. HPV-18 was detected in normal epithelium adjacent to the tumour in one case only. It appears from our study that HPV is of limited importance in oral squamous cell carcinogenesis in the population studied.

S Afr Med J 1995; 85: 894-896.

Human papillomaviruses (HPVs) have a predilection for squamous epithelium where they induce benign proliferative lesions such as warts on the skin, and papillomas and condylomas on mucosal surfaces.¹ Certain types, especially HPV-16, 18 and 33, have been implicated in squamous cell carcinogenesis because of their ability to immortalise human

epithelial cells after transfection.^{2,3} HPV-16 and 18 are strongly associated with high-grade premalignant lesions and anogenital carcinomas.⁴ Oral HPV infections have not been studied to the same degree as those of the genital tract, but are known to be associated with a variety of oral lesions in man, including papillomas, focal epithelial hyperplasia, hyperkeratotic lesions, lichen planus and leukoplakia.⁵ In view of the obvious oncogenic potential of some HPVs and the close similarity between the oral and genital mucosa, the possibility that certain HPV types may play a causative role in oral cancer does not seem too remote. Certain HPV types have been detected in benign oral lesions, as well as in oral squamous carcinoma.⁶

Studies originating from different geographical areas show a variation in HPV positivity ranging from 0% to 76,4%.⁷⁻¹¹ This difference in positivity is due to different populations studied and different methods used in HPV DNA detection.

According to the Federation Dentaire International, intra-oral cancer, of which squamous cell carcinoma accounts for the majority of cases, is the third most common malignant disease among men in developing countries.¹² The mortality rate remains unacceptably high, particularly in Africa, where advanced lesions are common on presentation. Although oral squamous carcinoma rarely occurs before the age of 50 years, Fleming *et al.*¹³ found a significant difference in age distribution between black and white South African men: 33,4% of the blacks were below the age of 50 years, as opposed to 15,6% of white men. The authors suggest that the black group may have been exposed to carcinogenic agents at an earlier age than the white group.

Our study was undertaken to determine the prevalence of HPV DNA in oral squamous carcinoma at Ga-Rankuwa Hospital, a referral centre for the western Northern Transvaal, an area in which a high number of new cases has been diagnosed over the past few years.

Material and methods

Formalin-fixed paraffin embedded blocks from 66 patients (51 men, 15 women, mean age 58,7 years) with oral squamous carcinoma were randomly selected from the archives of the Department of Oral Pathology at MEDUNSA. These blocks contained samples of both tumour and adjacent normal epithelium. Sections 5 µm thick were cut and used for light microscopy and *in situ* hybridisation. All sections were evaluated for epithelial changes consistent with HPV infection. These include verrucous hyperplasia with hyperparakeratosis and the presence of koilocytes.

Immunocytochemistry

All sections were examined for the presence of HPV structural proteins (group-specific papillomavirus capsid antigens) with an ABC immunoperoxidase kit (Lipshaw Corporation, Detroit).

HPV DNA in situ hybridisation (ISH)

All sections were mounted on 3-aminopropyltriethoxysilane-coated slides,¹⁴ deparaffinised and rehydrated by sequential

Department of Medical Virology, University of Stellenbosch, Tygerberg, W. Cape

Estrelita Janse Van Rensburg, M.MED. (VIROL.)

Department of Oral Pathology and Oral Biology, Medical University of Southern Africa, PO Medunsa, 0204

Willem F. P. van Heerden, M.CH.D.

Erich J. Raubenheimer, M.CH.D.

Department of Tropical Diseases, University of Pretoria

Estelle H. Venter, PH.D.

immersion into xylene and ethanol and digested with proteinase K (0,05 mg/ml) to expose the fixed target DNA. After post-fixation in 4% paraformaldehyde, slides were prehybridised for 30 minutes at 52°C, prior to the application of the denatured probe solution. DNA probes for HPV-6, 11, 16 and 18, cloned in pBR322, were used. These were kindly provided by Dr E.-M. de Villiers of the Human Papillomavirus Reference Center, DKFZ, Heidelberg, Germany. The probes were labelled with ³²p dCTP according to the multiprime DNA labelling system (Amersham, UK). Hybridisation was allowed to take place at 52°C for 16 hours in a humidified chamber. There were two post-hybridisation washes in a 2 x SSPE/50% formamide solution and one in 50% formamide, 0,1% SDS, 2 x SSC; each wash lasted 1 hour at 37°C. Slides were dehydrated through graded ethanol containing 0,3M NH acetate and then dipped in LM-1 emulsion (Amersham, UK). After a 4-day exposure time at 4°C, slides were developed (Ilford, Ciba Geigy), rinsed briefly in water and fixed for 5 minutes in Hypam fixative (Ilford). Sections were counterstained with haematoxylin and eosin before mounting.

Assay sensitivity was confirmed with two known positive control slides (one of cervical intra-epithelial neoplasia and the second, a carcinoma of the vulva positive for HPV-6 and 16 respectively). Assay specificity was confirmed by hybridisation of plasmid vector pBR322 on all sections investigated.

Results

In none of the biopsies were HPV-associated morphological changes found in the normal epithelium adjacent to the carcinoma. HPV-antigen expression could also not be demonstrated by means of the ABC immunoperoxidase technique in any of the tumour sections or in the adjacent normal epithelium.

HPV-18 DNA was detected by *in situ* hybridisation in the normal epithelium adjacent to the carcinoma in a single case (Fig. 1).

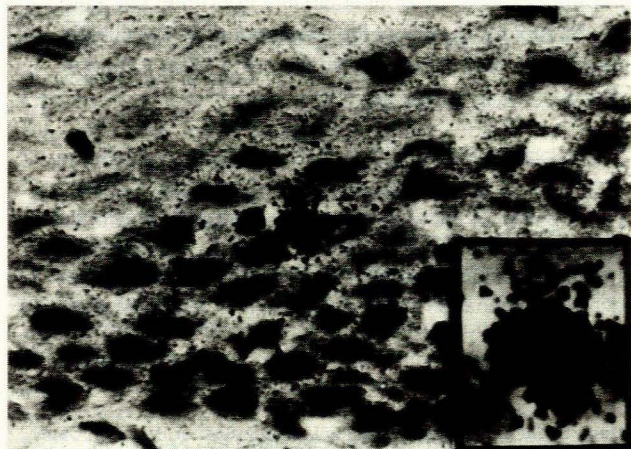


Fig. 1. Micrograph showing the presence of HPV-18 DNA as condensations of black-silver grains superimposed on the nucleus (x 200), with inset of high-power detail of positive cell (x 400).

Discussion

The oral mucosa is continuously exposed to minor trauma, micro-organisms and chemical factors such as tobacco and alcohol, which may act synergistically with HPV, leading to the development of carcinoma.^{15,16}

This study determined the prevalence of HPV infection in tumours and adjacent normal epithelium in cases of oral squamous carcinoma. The detection system used was selected because *in situ* hybridisation is useful for retrospective biopsy screening, as it permits detection, typing and localisation of HPV DNA in paraffin-embedded tissues that are readily available in a department of pathology. Radiolabelled probes, instead of biotinylated ones, were used because of their superior sensitivity.⁹

Viral antigens were not demonstrated in any of our cases by immunocytochemistry. The use of immunocytochemical methods is seriously limited by the fact that HPV antigens are only expressed in productive infections. Therefore, false-negative results may be obtained in infections where viral structural proteins are not likely to be expressed, as in cancers, because viral expression is inversely related to the degree of neoplasia.¹⁷

HPV-18 DNA was found in the normal oral mucosa adjacent to the tumour in only 1 of the 66 cases investigated. Other studies of oral carcinoma found a different pattern with HPV positivity within the tumour but a lower detection rate in the adjacent normal mucosa.^{11,18,19}

HPV detection in oral carcinoma in studies from different geographical regions show a great variation. An American study evaluating 10 squamous carcinomas detected HPV in a single case with ISH and polymerase chain reaction (PCR),⁷ while two other American studies could not detect HPV in any of their specimens with ISH alone.^{8,9} Tsuchiya *et al.*¹⁰ from Japan detected three positives from 30 samples using ISH while 76,4% of oral carcinomas in a Taiwan study were positive for HPV-16 according to the Southern blot technique.¹¹ In the last study mentioned, a high incidence of betel quid chewing and smoking was found in the patients studied.

The low prevalence of HPV in our collection can be explained in several ways: (i) the lesions studied may not have a viral aetiology; (ii) the possibility in the lesions studied of the occurrence of HPV genomic sequences other than the ones used by us as probes, cannot be ruled out; (iii) transformed cells may contain altered viral DNA not detectable by the probes used; and (iv) the method is not sensitive enough to detect low viral copy numbers. The ISH technique is highly sensitive in cases where individual nuclei contain a high copy number of the target DNA but often fails to detect cases in which subgenomic fragments of the viral DNA have been incorporated into the host genome.^{7,20} The extremely sensitive PCR may demonstrate a higher positivity rate than ISH. In a study by Watts *et al.*,²¹ ISH detected HPV in 60% of the oral squamous carcinoma cases examined while PCR could detect it in 90%. The same degree of increased sensitivity was not found in two other studies where results show a high degree of correlation between the two methods used.^{7,19} Although we did not use PCR in the present study, we feel that the outcome would not have been significantly different, given that only 1 case was found positive by means of ISH.

The present study, in which 66 cases of oral squamous cell carcinoma were reviewed retrospectively, is the largest series to have been investigated so far. It appears that in these cases of squamous cell carcinoma, HPV-associated oral infection occurs only rarely in the black population of the western Northern Transvaal.

The authors wish to thank Mrs H. van der Walt for secretarial services and Dr A. Gunders for help in preparing the manuscript. The study was supported by grants from the Poliomyelitis Research Foundation, Sandringham, and the Medical Research Council of South Africa.

REFERENCES

1. Chang F. Role of papillomaviruses. *J Clin Pathol* 1990; **43**: 269-276.
2. Woodworth CD, Bowden PE, Doniger J, et al. Characterization of normal human exocervical epithelial cells immortalized in vitro by papillomavirus types 16 and 18 DNA. *Cancer Res* 1988; **48**: 4620-4628.
3. Woodworth CD, Doniger J, Di Poalo JA. Immortalization of human foreskin keratinocytes by various human papillomavirus DNAs corresponds to their association with cervical carcinoma. *J Virol* 1989; **63**: 159-164.
4. Zur Hausen H. Human papillomaviruses in the pathogenesis of anogenital cancer (Mini-review). *Virology* 1991; **184**: 9-13.
5. Scully C, Cox MF, Prime SS, Maitland NJ. Papillomaviruses: the current status in relation to oral disease. *Oral Med* 1988; **65**: 526-532.
6. Chang F, Syrjänen S, Kellokoski J, Syrjänen K. Human papillomavirus (HPV) infections and their associations with oral disease. *J Oral Pathol Med* 1991; **20**: 305-317.
7. Shroyer KR, Greer RO. Detection of human papillomavirus DNA by in situ hybridisation and polymerase chain reaction in premalignant and malignant oral lesions. *Oral Surg Oral Med Oral Pathol* 1991; **71**: 708-713.
8. Zeus MS, Miller CS, White DK. In situ hybridization analysis of human papillomavirus DNA in oral mucosal lesions. *Oral Surg Oral Med Oral Pathol* 1991; **71**: 714-720.
9. Young SK, Min KW. In situ DNA hybridization analysis of oral papillomas, leukoplakias, and carcinomas for human papillomavirus. *Oral Surg Oral Med Oral Pathol* 1991; **71**: 726-729.
10. Tsuchiya H, Tomita Y, Shirasawa H, Tanzawa H, Sato K, Simizu B. Detection of human papillomavirus in head and neck tumors with DNA hybridisation and immunohistochemical analysis. *Oral Surg Oral Med Oral Pathol* 1991; **71**: 708-713.
11. Chang KW, Chang CS, Lai KS, Chou MJ, Choo KB. High prevalence of human papillomavirus infection and possible association with betel quid chewing and smoking in oral epidermoid carcinomas in Taiwan. *J Med Virol* 1989; **28**: 57-61.
12. Johnson NW. Oro-facial neoplasms: Global epidemiology, risk factors and recommendations for research. Report of the Commission on Oral Health, Research and Epidemiology of the Federation Dentaire International, London, 1990.
13. Fleming D, Shear M, Altini M. Intraoral squamous cell carcinomas in South Africa. *J Dent Assoc South Afr* 1982; **37**: 541-544.
14. Pringle JH, Primrose L, Kind CN, Talbot IC, Lauder I. In situ hybridization demonstration of poly-adenylated RNA sequences in formalin-fixed paraffin sections using a biotinylated oligonucleotide poly (T) probe. *J Pathol* 1989; **158**: 279-286.
15. Wynder EL, Muskinski MH, Spirak JC. Tobacco and alcohol consumption in relation to the development of multiple primary cancers. *Cancer* 1977; **40**: 1872-1878.
16. Pindborg JJ. Epidemiology of oral cancer and precancer. In: Pindborg JJ, ed. *Oral Cancer and Precancer*. Bristol: John Wright & Sons Ltd, 1980: 126-128.
17. Syrjänen KJ. Human papillomavirus (HPV) infections of the female genital tract and their associations with intra-epithelial neoplasia and squamous cell carcinoma. *Pathol Annu* 1986; **21**: 53-87.
18. Howell RE, Gallant L. Human papillomavirus type 16 in an oral squamous carcinoma and its metastasis. *Oral Surg Oral Med Oral Pathol* 1992; **74**: 620-626.
19. Chang F, Syrjänen S, Nuutinen J, Kärjä J, Syrjänen K. Detection of human papillomavirus (HPV) DNA in oral squamous cell carcinomas by in situ hybridization and polymerase chain reaction. *Arch Dermatol Res* 1990; **282**: 493-497.
20. Higgs TW, Moore NJ, Badawi DY, Taub FE. Type-specific human papillomavirus detection in formalin-fixed, paraffin-embedded tissue sections using nonradioactive deoxyribonucleic acid probes. *Lab Invest* 1990; **63**: 557-567.
21. Watts SL, Brewer EE, Fry TL. Human papillomavirus DNA types in squamous cell carcinomas of the head and neck. *Oral Surg Oral Med Oral Pathol* 1991; **71**: 701-707.

Accepted 9 Nov 1993.