



## Endovascular treatment of intractable epistaxis — results of a 4-year local audit

I C Duncan, P A Fourie, C E le Grange, H A van der Walt

**Objective.** Transcatheter embolisation is an accepted and effective treatment for intractable epistaxis. We analysed our success and complication rates and compared these with results from other published series.

**Design.** Retrospective review.

**Setting.** Unitas Interventional Unit, Centurion.

**Methods.** Case record review (57 procedures) and telephonic interviews (36 traceable respondents).

**Outcome measures.** A numerical audit of the success and complication rates for embolisation procedures performed during the 4-year period between July 1999 and June 2003.

**Results.** A total of 57 endovascular embolisation procedures

were performed for intractable epistaxis in 51 patients during this period. Eight patients (15.7%) developed a re-bleed between 1 and 33 days after embolisation, of whom 5 were re-embolised, giving a primary short-term success rate of 86.3% and secondary assisted success rate of 94.1%. Thirty-five of 36 respondents (97.2%) reported no further epistaxis during the long-term follow-up period of 1 - 47 months. The mortality rate was 0%, the major morbidity rate was 2% (1 stroke) and the minor morbidity rate was 25%.

**Conclusion.** Our success and complication rates are acceptable and compare favourably with those reported in other large series.

*S Afr Med J* 2004; 94: 373-378.

Epistaxis is a common condition affecting an estimated 60% of the general population, of whom approximately 6% will seek or require medical assistance.<sup>1</sup> Refractory or intractable epistaxis is defined as recurrent or persistent bleeding after appropriate conservative treatment, or multiple episodes of epistaxis over a short period of time, both requiring medical attention.<sup>2</sup> Intractable epistaxis usually arises from the posterior or superior parts of the nasal cavity, and is therefore not readily controlled by direct pressure, topical cauterisation or anterior nasal packing. Arterial ligation has remained the mainstay of treatment for intractable posterior epistaxis in many centres.<sup>3</sup> Percutaneous embolisation of the internal maxillary artery in patients with nasal haemorrhage was first described by Sokoloff *et al.*<sup>4</sup> in 1974. Currently, endovascular embolisation is an accepted method of treatment for haemorrhage from the nasal cavity or other craniofacial lesions.<sup>5-7</sup>

### Materials and methods

A retrospective audit was done of 57 percutaneous endovascular embolisation procedures in 51 patients performed over the 4-year period between July 1999 and June 2003 at the Unitas Interventional Unit in Centurion. All patients were referred by an otorhinolaryngologist (ENT

specialist) after failed conventional treatment, generally involving local cauterisation and/or nasal packing. Twelve of our patients had also received a blood transfusion before embolisation. We reviewed our procedural data notes, with further clinical data obtained either from initial referral letters or from follow-up notes provided by referring clinicians. Long-term telephonic follow-up was obtained for 38 patients (respondents). Thirteen patients were untraceable during the period of the audit. Of the 38 respondents, 2 had died of unrelated causes since the embolisation; telephonic interviews were conducted with the remaining 36. The collection of data was flawed by incomplete clinical record keeping. The most complete data obtained were for the 36 respondents, as much of the recorded data could be cross-checked and they could also provide missing information in addition to long-term follow-up. The long-term follow-up period varied between 1 and 47 months.

All embolisation procedures were performed using a Phillips V5000 Integris digital monoplane angiography unit. Initial diagnostic arteriograms of the internal carotid artery (ICA) and external carotid artery (ECA) were obtained on each side. The ICA was examined in order to exclude an intracranial aneurysm, arteriovenous shunt or frontal tumour as a possible cause of the bleeding as well as to identify any arterial supply to the nasal cavity from ethmoidal branches of each ophthalmic artery (Fig. 1). The ipsilateral internal maxillary artery (IMAX), defined as that supplying the nasal cavity from which the bleeding was visualised or assumed to arise, was then superselectively catheterised using a microcatheter technique and embolised in all cases bar one. In the latter case ipsilateral

Unitas Interventional Unit, Centurion

I C Duncan, FFRad (D) SA

P A Fourie, MMed Rad D

C E le Grange, NatDipRad (Diag)

H A van der Walt, BSc (Verpleeg)

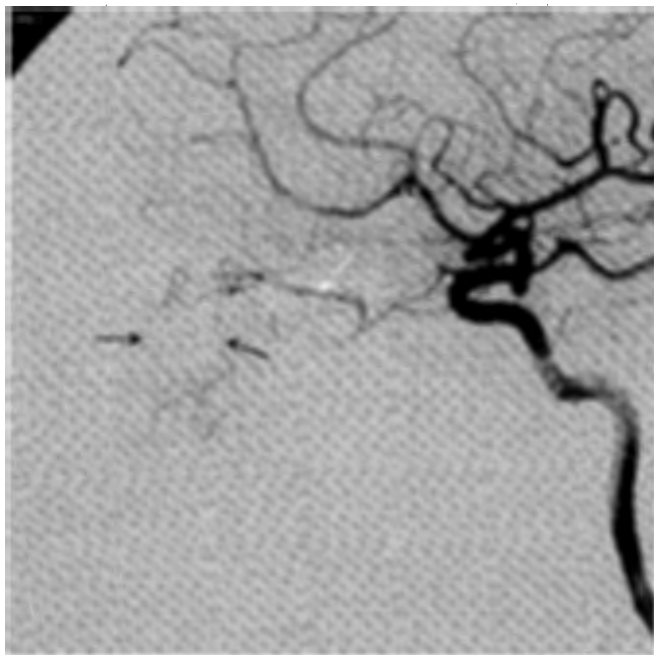
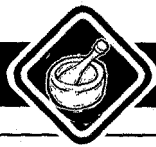

Fig. 1. Selective internal carotid digital subtraction arteriogram showing supply to the superior nasal cavity via the ethmoidal branches (black arrows) of the ophthalmic artery (white arrow).

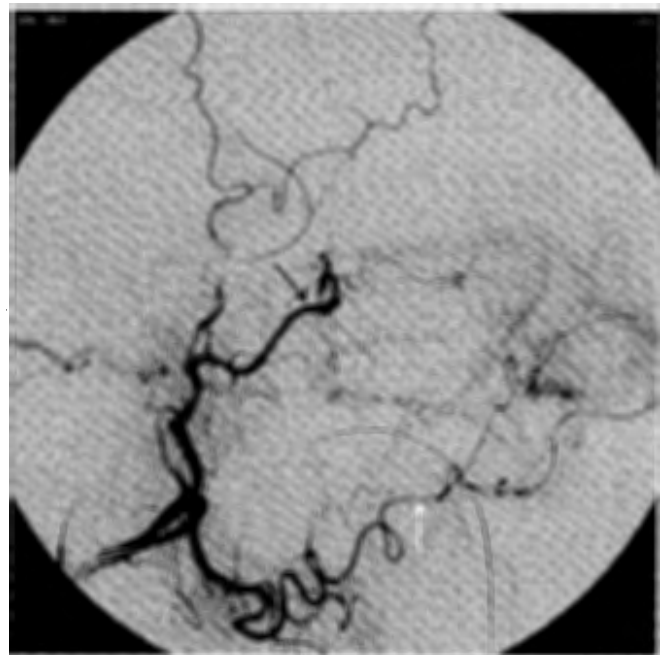

Fig. 2a. Selective external carotid digital subtraction arteriogram showing the arterial supply to the nasal cavity via terminal branches of the internal maxillary artery (black arrow) and facial artery (white arrow).

ECA origin was occluded due to atheromatous disease and a contralateral IMAX embolisation was performed. Other vessels superselectively catheterised and embolised included the ipsilateral facial artery ( $N = 29$ , 51%), the contralateral IMAX ( $N = 27$ , 47.4%) the contralateral facial artery ( $N = 8$ , 14%), the ascending pharyngeal artery ( $N = 1$ , 1.7%) and the accessory meningeal artery ( $N = 1$ , 1.7%). The decision to embolise arteries other than the ipsilateral IMAX was based on the relative contributions of each vessel to the supply of the nasal cavity as well as the potential for collateral supply to the nasal cavity (Fig. 2). During arteriography the actual site of the bleeding usually cannot be identified and often no abnormal vessels are seen in the nasal cavities, although in several cases a nonspecific generalised nasal mucosal 'blush' due to nasal mucosal congestion or arterial tortuosity may be seen (Figs 2b - 2d). The most frequently used embolic agents were microparticles in 56 procedures (98.2%) with particle sizes ranging from 150 to 700  $\mu\text{m}$  in diameter, usually between 250 and 500  $\mu\text{m}$ . Other embolic materials used included cyanoacrylate ( $N = 5$ , 8.8%), platinum microcoils ( $N = 4$ , 7%) and gelatine sponge (Spongistan) ( $N = 4$ , 7%). In all cases where no macroscopic cause of the bleeding such as a pseudoaneurysm could be identified, and where microparticulate embolisation was performed, the desired endpoint of embolisation was a significant visible reduction or cessation of flow in the target vessel(s) (Fig. 3). Where documented the nasal packing was removed in theatre in 56% of cases and afterwards in 44% of cases ( $N = 36$ ).

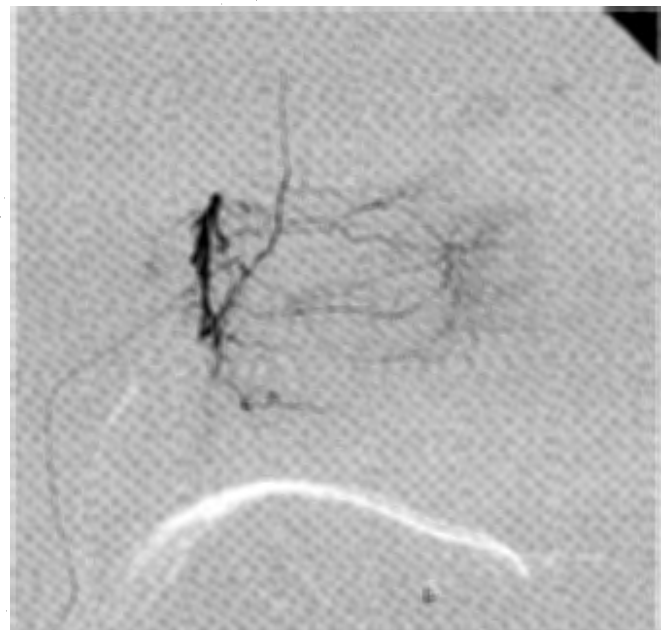

Fig. 2b. Selective internal maxillary arteriogram (same case as Fig. 2a) showing the typical appearance of the nasal arteries before embolisation. No bleeding site is identifiable and the arteries have a normal appearance.

## Results

The male-to-female ratio of our patients was 1.2: 1 (28 men and 23 women), and the mean age was 54.4 years (range: 17 - 83

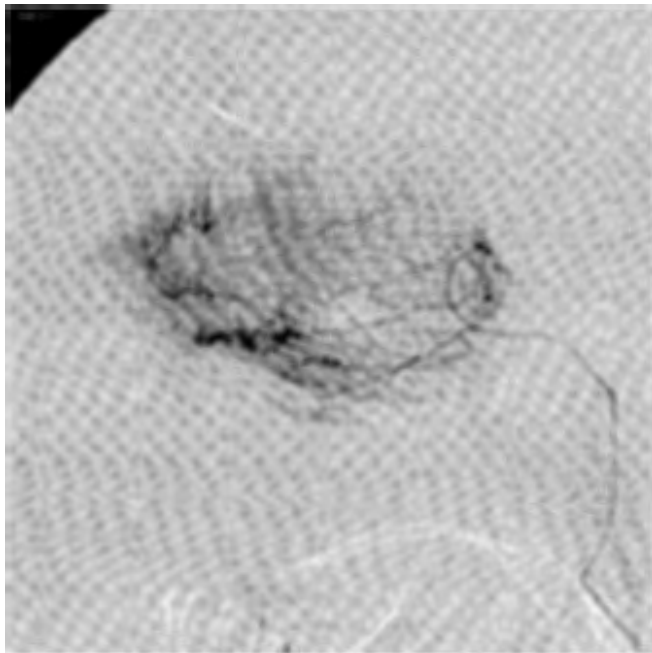
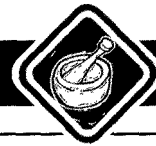

Fig. 2c. In some cases a prominent nasal capillary blush may be seen in keeping with mucosal congestion.

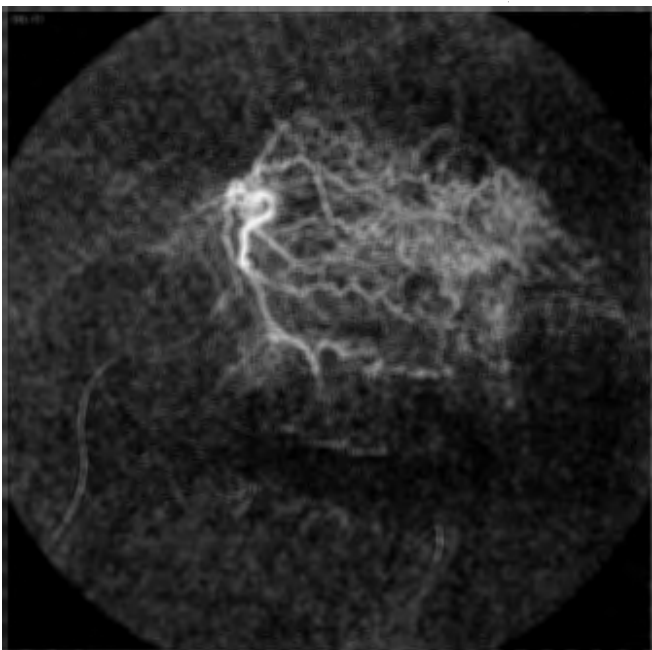


Fig. 2d. In others tortuosity of the intranasal arteries may be seen.

years). Thirty-two cases (63%) were referred between the months of May and September. The causes of epistaxis were deemed idiopathic in 45 (88.2%), related to trauma in 3 (5.9%), post-surgical in 2 (3.9%) and hereditary haemorrhagic telangiectasia (HHT) in 1 (2%). Of the 2 cases related to previous surgery, 1 had recently undergone removal of an

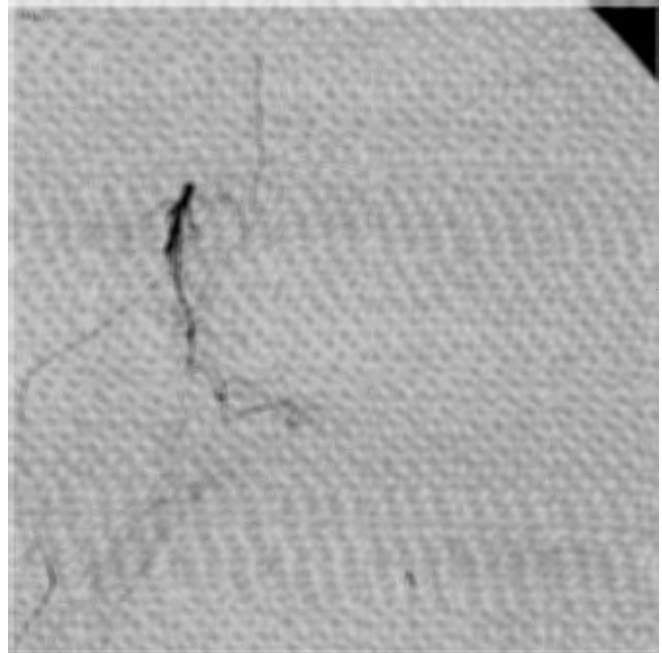


Fig. 3. In the same case as shown in Figs 2a and 2b, a selective internal maxillary arteriogram following microparticulate embolisation shows very little contrast opacification of the nasal branches, indicating a satisfactory angiographical endpoint for embolisation.

osteoma from the sphenoid sinus (with ipsilateral IMAX occlusion seen at angiographic examination), while the second presented with severe bleeding from a large pseudoaneurysm of the distal IMAX following a recent maxillary osteotomy. Identifiable risk factors among the respondent group ( $N = 36$ ) included hypertension in 19 (52.8%), smoking in 9 (25%), anticoagulation/antiplatelet use in 5 (13.9%) and radiation therapy in 1 (2.8%). None of the respondents volunteered any history of alcohol or illicit drug abuse. One patient had previously undergone radiation therapy for a maxillary malignancy deemed inactive at the time of the embolisation. One of the non-respondents developed severe epistaxis at 25 weeks of pregnancy for which no underlying cause was found. One 17-year-old girl with a sideroblastic anaemia for which she had received multiple blood transfusions over a period of several years was referred for a semi-elective procedure, the only case in our series not treated on an emergency basis.

Eight patients (15.7%) developed a re-bleed between 1 and 33 days after the initial embolisation (Table I). Of these, 4 patients (7.8%) underwent a second embolisation procedure and 1 patient with HHT underwent 2 further embolisation procedures in our unit and 1 at another centre. Two patients (3.9%) underwent additional surgical ligation of the ethmoid arteries after which no further bleeding was encountered. One of these had a Le Fort II fracture whereas the second had an idiopathic-type bleed. One patient had a single post-

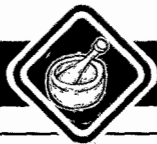

Table I. Re-bleeding after initial embolisation

Patient	Age (years)	Risk factors	Time of re-bleed	Cause of re-bleed	Further treatment	Outcome
1	34	Smoker	2 days	Unknown	Repeat angiogram only	No re-bleed
2	58	Smoker HHT	Multiple re-bleeds over many years	HHT	Total of 3 embolisations performed (+1 at another centre) in 2 years	Eventually well palliated for > 1 year with intraslesional bleomycin
3	50	Warfarin and Disprin (cardiac valve replacement)	1/2 day	Unknown. The PI at time of the rebleed was 75%	Repeat embolisation of ipsilateral IMAX only with microparticles	No re-bleed
4	25	Pregnant (25 weeks)	33 days	Unknown	Repeat embolisation of ipsilateral IMAX only with microparticles	No re-bleed
5	83	Warfarin (pulmonary embolism), PI on admission of 34%	1 day	Significant collateral supply via accessory meningeal artery	Repeat embolisation of ipsilateral IMAX and accessory meningeal artery	No re-bleed
6	36	Le Fort II fracture	2 days	Significant collateral supply via ethmoid arteries	Surgical ligation of ethmoid arteries	No re-bleed
7	55	Hypertension	1/2 day	Significant collateral supply via ethmoid arteries	Surgical ligation of ethmoid arteries	No re-bleed
8	18	Maxillary osteotomy with IMAX pseudo-aneurysm	10 days	Coil migration and recanalisation through coils inserted previously in the IMAX	Repeat embolisation using particles, coils and cyanoacrylate	No re-bleed

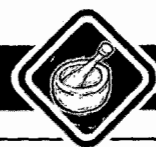HHT = hereditary haemorrhagic telangiectasia; PI = prothrombin index; IMAX = internal maxillary artery.

Table II. Reported success and complication rates since 1995 (N (%))

Study	No. of patients	Success rate	Minor complications	Major complications	Overall complication
Elahi <i>et al.</i> , <sup>7</sup> 1995	57	52 (96)	None reported	3 (6)	3 (6)
Tseng <i>et al.</i> , <sup>2</sup> 1998	114	101 (88)	17 (15)	2 (1.8)	19 (16.8)
Leppanen <i>et al.</i> , <sup>15</sup> 1999	37	33 (89)	4 (8)	0 (0)	4 (8)
Oguni <i>et al.</i> , <sup>16</sup> 2000	37	35 (94.6)	7 (45)	0 (0)	7 (45)
Total	245	221 (90.2)	28 (11.4)	5 (2)	33 (13.4)

procedural re-bleed; angiographic examination was repeated but no further embolisation performed. Therefore, 44 patients (86.3%) responded well to a single embolisation procedure. No further re-bleeds were noted in the 4 patients who underwent a second embolisation procedure, giving a cumulative success rate for embolisation alone of 94.1%. With the exception of the HHT patient, none of the 36 respondents reported a late re-bleed after primary or secondary intervention. There was a 0% mortality rate in our series. There was a single major

complication (2%), namely the development of a right-sided cerebral infarction during attempted replacement of a guiding catheter in a tortuous carotid artery. Minor complications included transient headache in 3 patients (8.3%), transient facial pain or paraesthesia in 2 (5.5%) and local groin haematoma, pain or prolonged anaesthesia in 4 (11%). The total minor complication rate among the respondent group was therefore 25%.



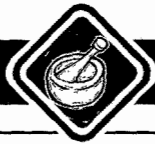## Discussion

Most cases of epistaxis occur in the anterior nasal cavity in the region of the anteroinferior septum known as Little's area. Underlying this is a confluence of arterial territories, namely those of the sphenopalatine artery, the greater palatine artery, the facial artery and the anterior and posterior ethmoidal arteries. This arterial confluence is known as Kiesselbach's plexus.<sup>8</sup> Anterior epistaxis is usually easily controlled by conservative measures including localised pressure, topical cauterisation and vasoconstriction, local infiltration with antifibrinolytic agents and anterior nasal packing.<sup>9</sup> Posterior (and to a lesser degree superior) epistaxis accounts for about 5% of all epistaxis cases and can be extremely difficult to manage. Posterior nasal packing can be done using gauze or balloon catheters. Nasal packing has a reported failure rate of 26 - 52% and a complication rate of 69%. These complications include nasal trauma, vasovagal response, aspiration, displacement of the packing, persistent bleeding, infection, toxic shock syndrome and hypoxia.<sup>9,10</sup> Surgical approaches include transantral ligation of the distal IMAX and ligation of the ethmoid arteries for superior epistaxis.<sup>3</sup> More recently, endoscopic cauterisation and arterial ligation techniques have been described although these are technically more demanding.<sup>11</sup> The endovascular management of epistaxis has become an established alternative to surgical ligation. In a comparison of efficacy between transantral ligation and embolisation in intractable epistaxis, Strong *et al.*<sup>12</sup> reported success rates from the literature of 85% and 90% and average complication rates of 28% and 27% respectively for ligation and embolisation, with success rates of 89% and 94% respectively from their own series. Cullen and Tami<sup>13</sup> showed a failure rate of 21% for embolisation versus 27% for ligation (with or without ethmoid ligation) and an overall complication rate of 16% for embolisation and 18% for IMAX ligation. In their review of the literature, which expanded upon that by Strong *et al.*, they reported a slightly higher failure rate for embolisation (20%) than for IMAX ligation (18%) but a significantly higher complication rate for IMAX ligation (26%) than for embolisation (14%). No difference in major complication rates (5% v. 4%) was noted between the two methods.

The goal of embolisation is simply to reduce the arterial pressure head to the affected region without causing any ischaemic damage to the nasal soft tissues.<sup>7</sup> This in turn allows the body to heal itself. The posterior nasal cavity is supplied mainly via the sphenopalatine artery and greater palatine artery, both being terminal branches of the IMAX. This means that the management of posterior epistaxis largely hinges around control of the sphenopalatine artery. This also explains the equally high rate of success of ipsilateral IMAX embolisation alone. However, there is still a failure rate of 10 - 15% for both embolisation and IMAX/sphenopalatine ligation. Furthermore, as shown by Vitek,<sup>5</sup> the technical success rate of embolisation increases significantly when additional

embolisation of the ipsilateral facial and contralateral IMAX arteries is performed as well. This attests to the importance of collateral vessels in the facial region with collateral blood supply to the posterior nasal cavity, which probably accounts for a significant percentage of failed IMAX ligation and embolisation procedures.<sup>14</sup> The advantage of arteriography is that it can often identify these collateral sources allowing them to be treated simultaneously as well. Over 50% of our cases involved multiple vessel embolisation. Collateral supply to the nasal cavity leading to recurrent haemorrhage occurred in 4 of our cases (Table I). Collateral supply via the ethmoid arteries led to secondary surgical intervention in 2 cases. Another potential complication related to collateral circulation is the presence of intracranial-extracranial arterial anastomoses where inadvertent embolisation through these pathways can lead to ophthalmologic or neurological complications.<sup>6</sup> It is therefore vital to identify these communications during the initial angiographic investigation. Two of our cases with a re-bleed following initial embolisation of the ipsilateral IMAX underwent a second procedure involving a repeat microparticle embolisation of the same vessel, with good outcome. Inadequate embolisation, as with incomplete IMAX ligation, can therefore lead to recurrent bleeding. One patient who had a re-bleed 2 days after embolisation underwent a repeat arteriogram which showed adequate occlusion of the ipsilateral distal IMAX branches. No significant collateral vessels were identified and so no further embolisation was performed. No further bleeding was experienced thereafter. False re-bleeds following embolisation may occasionally be encountered and may be due to retained blood in and around the nasal packing or blood draining from the paranasal sinuses.

We used microcatheter techniques in all cases but 1. Although leading to increased expense and procedural duration and complexity, the use of microcatheters has been reported in reducing the number of local cranial complications, although to date this has not been proved in any randomised study.<sup>15,16</sup> In Table II we reviewed 4 studies conducted in or after 1995, where the routine use of microcatheter techniques was reported. Here we calculated the cumulative success rate of 90.2% and overall complication rate of 13.4% (11.4% minor and 2% major) with microcatheter usage. Therefore although the use of microcatheter techniques does not improve the overall success rate, there is a tendency towards a lesser complication rate. This factor should be weighed up against the additional procedural costs involved per case. Using microcatheters we have noted a lesser frequency of arterial vasospasm that can also prolong and complicate a procedure. One problem that is apparent in the series reported to date is inconsistency in the reporting of minor and major complications and hence variation in the reported figures. Other factors such as improvements in catheter and guidewire design and increased operator experience have also probably contributed to the reduction in complication rates in more recent times.



Other complications related to embolisation for epistaxis that have been reported in other local institutions include ischaemic necrosis of the upper lip (facial arterial embolisation), unilateral trismus (related to deep temporal arterial occlusion) and ischaemic sialadenitis (facial artery embolisation). Further complications described in the literature include facial nerve paralysis, tongue necrosis, tonsillar ulceration, facial atrophy and transient submandibular gland swelling. Other potential complications can be related to the femoral access (pain, bruising, pseudoaneurysm or arteriovenous fistula) or to the use of contrast media (allergic reaction, renal failure). Our single major complication was a stroke related to attempted replacement of a guiding catheter in an extremely tortuous carotid artery.

One advantage of endovascular treatment is that it can be performed under local anaesthesia with sedation if required. Although only 38.6% of our cases were performed under general anaesthesia, our accumulated experience has now led us to utilise general anaesthesia routinely for 2 reasons. Firstly, these patients are generally uncomfortable, with nasal packing *in situ* and occasionally active bleeding during the procedure as well. Prolonged immobilisation on the angiography table may be required during difficult cases. This results in further patient discomfort and reduced co-operation, with movement (voluntary and involuntary) rendering the use of electronic vascular roadmapping useless, further prolonging the procedure and adding to the risk of complications or an incomplete or inadequate procedure. Secondly, we now insist on full airway protection by means of a cuffed endotracheal tube before commencing any embolisation procedure in the head and neck region, where active bleeding is an issue. Regardless of whether or not a general anaesthetic is administered, an anaesthetist is always present for patient monitoring and administration of analgesic or sedative drugs as required.

One subgroup of patients who develop recurrent epistaxis are those with HHT (Osler-Weber-Rendu disease), a genetic multisystemic angiodysplasia. These patients develop fragile nasal mucosal telangiectasias and are prone to repeated and intractable epistaxis in more than 90% of cases. Embolisation is not a definitive treatment for epistaxis in these patients but can control an acute bleeding episode. Because of the known propensity for epistaxis to recur in these patients, Elden *et al.*<sup>16</sup> found that their long-term success rate for embolisation increased from 82% to 90% once the HHT patients in their series were excluded. There is still no definitive treatment available for the nasal manifestations of HHT. We have successfully palliated our patient for more than 18 months using intramucosal injections of bleomycin (unpublished data).

Although embolisation is a good alternative to surgical IMAX ligation (or related procedures), interventional expertise is only available in the major centres in South Africa. Fifteen patients were referred from within the Pretoria area, with 36 others being transferred from other centres, generally from

within a 150 km radius of our unit. In their study of the attitudes of practising otorhinolaryngologists in Ohio, Cullen and Tami<sup>13</sup> found that before publication of their article in 1998, only 16% had referred patients for embolisation, of whom three-quarters were from urban practices and the rest from rural areas. Also, more urban than rural hospitals had embolisation facilities. This finding is mirrored and undoubtedly amplified in South Africa. In their comparison of the cost of IMAX ligation versus that of embolisation, Strong *et al.*<sup>12</sup> found the average cost per case in 1994 for antral ligation to be US\$5 941 versus US\$6 783 for embolisation. Cullen and Tami<sup>13</sup> calculated the average costs in their institution in 1998 to be US\$6 184.55 for IMAX ligation and US\$4 544.85 for embolisation. No comparative figures are available locally.

In conclusion, intractable epistaxis is a debilitating condition and treatment can be extremely difficult. Percutaneous transcatheter embolisation of the nasal arteries is an accepted alternative to surgical intervention, with comparable major and minor complication rates, success rates and overall costs.

Most cases will respond well to a single embolisation procedure, with approximately 10% failing to respond owing to factors such as collateral arterial supply, HHT, etc. These procedures should only be performed by suitably experienced interventional radiologists either under general anaesthesia or at least with full monitoring and anaesthetic backing.

Thanks to Lizl Geldenhuis for her assistance with preparation of this manuscript.

#### References

1. Small M, Murray J, Maran AG. A study of patients with epistaxis requiring admission to hospital. *Health Bull (Edinb)* 1982; **40**: 20-29.
2. Tseng EY, Narducci CA, Willing SJ, Silliers MJ. Angiographic embolization for epistaxis. *Laryngoscope* 1998; **108**: 615-619.
3. Small M, Maran AGD. Epistaxis and arterial ligations. *J Laryngol Otol* 1984; **98**: 281-284.
4. Sokoloff J, Wickbom I, McDonald D, Brahme F, Goergen TG, Goldberger LE. Therapeutic percutaneous embolization in intractable epistaxis. *Radiology* 1974; **111**: 285-287.
5. Vitek JJ. Idiopathic intractable epistaxis: Endovascular therapy. *Radiology* 1991; **181**: 113-116.
6. Kagetsu NJ, Berenstein A, Choi IS. Interventional radiology of the extracranial head and neck. *Cardiovasc Intervent Radiol* 1991; **14**: 325-333.
7. Connors JJ III, Wojak JC. Epistaxis. In: Connors JJ III, Wojak JC (eds). *Interventional Neuroradiology: Strategies and Practical Techniques*. Philadelphia: WB Saunders, 1999: 147-156.
8. Koh E, Frazzini VI, Kagetsu NJ. Epistaxis: Vascular anatomy, origins and endovascular treatment. *Am J Roentgenol* 2000; **174**: 845-851.
9. Tan LKS, Calhoun KH. Epistaxis. *Med Clin North Am* 1989; **83**: 43-56.
10. Schaitkin B, Strauss M, Houck JR. Epistaxis: medical versus surgical therapy — a comparison of efficacy, complications and economic considerations. *Laryngoscope* 1987; **97**: 1392-1396.
11. Pritikin JB, Caldarelli DD, Panje WR. Endoscopic ligation of the internal maxillary artery for treatment of intractable posterior epistaxis. *Ann Otol Rhinol Laryngol* 1998; **107**: 85-91.
12. Strong EB, Bell DA, Johnson LP, Jacobs JM. Intractable epistaxis: Transantral ligation versus embolization: Efficacy review and cost analysis. *Otolaryngol Head Neck Surg* 1995; **113**: 674-678.
13. Cullen MM, Tami TA. Comparison of internal maxillary artery ligation versus embolization for refractory posterior epistaxis. *Otolaryngol Head Neck Surg* 1998; **118**: 636-642.
14. Hacıen-Bay L, Rosenbloom JS, Pile-Spellman J, *et al.* Anastomoses in recurrent epistaxis. *J Vasc Interv Radiol* 1997; **8**: 535-538.
15. Leppanen M, Seppanen S, Loranne J, Kuoppala K. Microcatheter embolization of intractable idiopathic epistaxis. *Cardiovasc Intervent Radiol* 1999; **22**: 499-503.
16. Elden L, Montanera W, Terbrugge K, Willinsky R, Lasjaunias P, Charles D. Angiographic embolization for the treatment of epistaxis: A review of 108 cases. *Otolaryngol Head Neck Surg* 1994; **111**: 44-50.
17. Elahi MM, Panes LS, Fox AJ, Pelz DM, Lee DM. Therapeutic embolization in the treatment of epistaxis. *Arch Otolaryngol Head Neck Surg* 1995; **121**: 65-69.
18. Oguni T, Korogi Y, Yasunaga T, *et al.* Superselective embolisation for intractable idiopathic epistaxis. *Br J Radiol* 2000; **73**: 1148-1153.

Accepted 26 January 2004.