



## References

- Wongsrichanalai C, Pickard AL, Wernsdorfer WH, Meshnick SR. Epidemiology of drug-resistant malaria. *Lancet Infect Dis* 2002; **2**: 209-218.
- Arrosen B, Bengtsson E, Bjorkman A, Pehrson PO, Rombo L, Walhgren M. Chloroquine resistant falciparum malaria in Madagascar and Kenya. *Ann Trop Med Parasitol* 1981; **75**: 367-373.
- Deloron P, Le Bras J, Ramanamirija JA, Coulanges P. *Plasmodium falciparum* in Madagascar: *in vivo* and *in vitro* sensitivity to seven drugs. *Ann Trop Med Parasitol* 1985; **79**: 357-365.
- Randrianarivojosia M, Raharimalala L, Randriamanantena A, Jambou R. Drug resistance of *Plasmodium falciparum* in coastal regions of Madagascar. *Med Trop* 2000; **60**: 243-249.
- Ariey F, Randrianarivojosia M, Duchemin JB, *et al.* *Plasmodium falciparum* pfcr1 K76T mutation mapping: a useful tool for malaria control strategy in Madagascar. *J Infect Dis* 2002; **185**: 710-712.
- World Health Organisation. *International Travel and Health*. Geneva: WHO, 2002: 193.
- Department of Health, Republic of South Africa. *Guidelines for the Prophylaxis of Malaria*. Pretoria: Government Printer, 1996: 1-15. BB7128/50 000.
- Jeanne I, Randremanana RV, Robert V, *et al.* Madagascar biogeography. In: *Malaria Research Group, eds. Madagascar Malaria Map*. 1st ed. Antananaviro: Institut Pasteur de Madagascar, 2002: 3-10.
- Warrell DA, Molyneux ME, Beales PF. Severe and complicated malaria. *Trans R Soc Trop Med Hyg* 1990; **84**: Suppl. 2, 1-65.
- Le Bras J, Deloron P. *In vitro* study of drug sensibility of *Plasmodium falciparum*: An evaluation of a new semi-microtest. *Am J Trop Med Hyg* 1983; **32**: 447-451.
- Basco LK, Le Bras J. *In vitro* susceptibility of Cambodian isolates of *Plasmodium falciparum* to halofantrine, pyronaridine and artemisinin derivatives. *Ann Trop Med Parasitol* 1994; **88**: 131-136.
- Parzy D, Doerig C, Pradines B, Rico A, Fusai T, Doury JC. Proguanil resistance in *Plasmodium falciparum* African isolates: assessment by mutation-specific polymerase chain reaction and *in vitro* susceptibility testing. *Am J Trop Med Hyg* 1997; **57**: 646-650.
- Randrianarivojosia M, Raharimalala LA, Randrianasolo L, *et al.* Madagascan isolates of *Plasmodium falciparum* showing low sensitivity to artemether *in vitro*. *Ann Trop Med Parasitol* 2001; **95**: 237-243.
- Rason MA, Ariey F, Rafidimanantsoa L, Andrianantenaina BH, Sahondra Harisoa JL, Randrianarivojosia M. Monitoring the drug-sensitivity of *Plasmodium falciparum* in coastal towns in Madagascar by use of *in vitro* chemosensitivity and mutation detection tests. *Parasite* 2002; **9**: 247-253.
- Randrianarivojosia M, Ratsimbaoa A, Randrianasolo L, Randrianarijaona A, Jambou R. *In vitro* sensitivity of *Plasmodium falciparum* to chloroquine, halofantrine, mefloquine and quinine in Madagascar. *East Afr Med J* 2002; **79**: 237-241.
- Jambou R, Raharimalala L, Milijaona R, *et al.* Etude de la chimiosensibilité de *Plasmodium falciparum* à Madagascar: 2- Efficacité et tolérance de la quinine base 250 mg (Surquina) dans le traitement de l'accès palustre simple. *Arch Inst Pasteur Madagascar* 1998; **64**: 56-61.
- Trape JE, Pison G, Spiegel A, Enel C, Rogier C. Combating malaria in Africa. *Trends Parasitol* 2002; **18**: 224-230.
- Assimadi JK, Gbadoé AD, Agbodjan-Djossou O, *et al.* Intravenous quinine treatment of cerebral malaria in African children: comparison of a loading dose regimen to a regimen without loading dose. *Arch Pediatr* 2002; **9**: 587-594.
- Kofoed PE, Co F, Poulsen A, *et al.* Treatment of *Plasmodium falciparum* malaria with quinine in children in Guinea-Bissau: one daily dose is sufficient. *Trans R Soc Trop Med Hyg* 2002; **96**: 185-188.
- Athan E, Durrheim DN, Barnes K, Mngomezulu NM, Mabuza A, Govere J. Effectiveness of short-course quinine and single-dose sulfadoxine-pyrimethamine in the treatment of *Plasmodium falciparum* malaria in Mpumalanga Province, South Africa. *S Afr Med J* 2001; **91**: 592-594.
- World Health Organisation. *The Use of Antimalarial Drugs. Report of a WHO Informal Consultation*. WHO/CDS/RBM/2001.33: 62-66.
- Milijaona R, Jambou R, Raharimalala L, Ranaivo L, Rason MA, Roux J. Mefloquine resistant strains of *Plasmodium falciparum* in Madagascar: impact for travellers and public health. *Ann Trop Med Parasitol* 2000; **94**: 313-317.
- Kublin JG, Dzinzalamala FK, Kamwendo DD, *et al.* Molecular markers for failure of sulfadoxine-pyrimethamine and chlorproguanil-dapsone treatment of *Plasmodium falciparum* malaria. *J Infect Dis* 2002; **185**: 380-388.

Accepted 23 May 2003.

## Oral trimethoprim-sulfamethoxazole in the treatment of cerebral toxoplasmosis in AIDS patients — a prospective study

P Francis, V B Patel, P L A Bill, A I Bhigjee

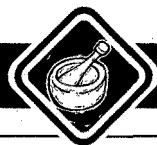Toxoplasma encephalitis is the commonest cause of intracranial mass lesions in AIDS patients. Effective therapy includes pyrimethamine plus sulfadiazine, clindamycin with pyrimethamine, and co-trimoxazole. This study

examines the efficacy of oral co-trimoxazole in 20 AIDS patients with toxoplasmosis and seeks to confirm the experience of Torre *et al.*

*S Afr Med J* 2004; **94**: 51-53.

Toxoplasmosis is the most frequent cause of focal cerebral lesions in patients with AIDS.<sup>1</sup> Current therapy for acute cerebral toxoplasmosis is a combination of pyrimethamine plus sulfadiazine.<sup>2</sup> Alternative agents include clindamycin, clarithromycin and azithromycin.<sup>3,4</sup> In addition to the significant adverse effect profile of the pyrimethamine combination, necessitating folinic acid replacement, none of these agents is available in intravenous form in most public

service hospitals within the province of KwaZulu-Natal. The combination of trimethoprim-sulfamethoxazole (co-trimoxazole) has been shown to possess antitoxoplasmic activity *in vitro*<sup>3</sup> and *in vivo*.<sup>5,6</sup> The latter study,<sup>6</sup> a retrospective appraisal of intravenous therapy, showed a favourable outcome in 87% of treated patients. The aim of the present study was to prospectively evaluate the efficacy of oral co-trimoxazole in acute cerebral toxoplasmosis.



## Methods

HIV-positive patients referred to the neurology unit with radiological lesions suggestive of toxoplasmosis (multiple lesions with rim enhancement, basal ganglia location, extensive surrounding oedema) were entered into the study. Computed tomography (CT) scans were performed on admission, before commencing therapy. Repeat scans were done 2 - 4 weeks later, except when neurological deterioration necessitated an earlier scan. Patients qualifying for entry into the study were treated with trimethoprim-sulfamethoxazole (co-trimoxazole 80 mg and 400 mg respectively). An induction dose of 2 tablets 4 times daily for 1 month was followed by 2 tablets 12-hourly for life in the absence of antiretroviral therapy and a CD4 count below 200 cells/ $\mu$ l. This dose is comparable with the international literature which cites doses of 10 and 50 mg/kg/day of trimethoprim-sulfamethoxazole respectively. Clinical improvement was taken to indicate diagnostic accuracy. Non-responders were referred to the neurosurgeons for a stereotactic biopsy. Patients who refused consent for a biopsy were started on antituberculosis treatment with or without dexamethasone. All non-responders were excluded from further statistical analysis. Treatment efficacy was ascertained by clinical and/or radiological improvement. Serological tests included HIV enzyme-linked immunosorbent assay (ELISA) and *Toxoplasma gondii* antibodies, while CD4 cell counts were available in 7 patients. In the latter phase of the study, magnetic resonance imaging (MRI) scans were also done.

## Results

Twenty patients completed the study. There was an equal number of male and female patients. The mean age at presentation was 32 years. Hemiparesis was the commonest presenting symptom (77%), followed by mental status changes (62%) and seizures (23%). All patients were HIV-positive. CD4 counts were available for 7 patients. These ranged from 1 cell/ $\mu$ l to 78 cells/ $\mu$ l. *T. gondii* antibodies were positive in 8 of 20 patients. All patients showed complete or partial clinical and radiological improvement (Figs 1a, b, 2a, b). The improvement was sustained on the selected maintenance regimen of 2 tablets 12-hourly. However, not all patients continue to attend for follow-up so the long-term outcome remains speculative. No significant cutaneous side-effects were noted in our study group, although a few developed minor gastrointestinal upset.

## Discussion

This study establishes the efficacy of oral co-trimoxazole as therapy for acute cerebral toxoplasmosis in the doses described. This has significant utility in the public sector. It is recommended that oral co-trimoxazole be implemented as first-line therapy in cases of suspected cerebral toxoplasmosis.

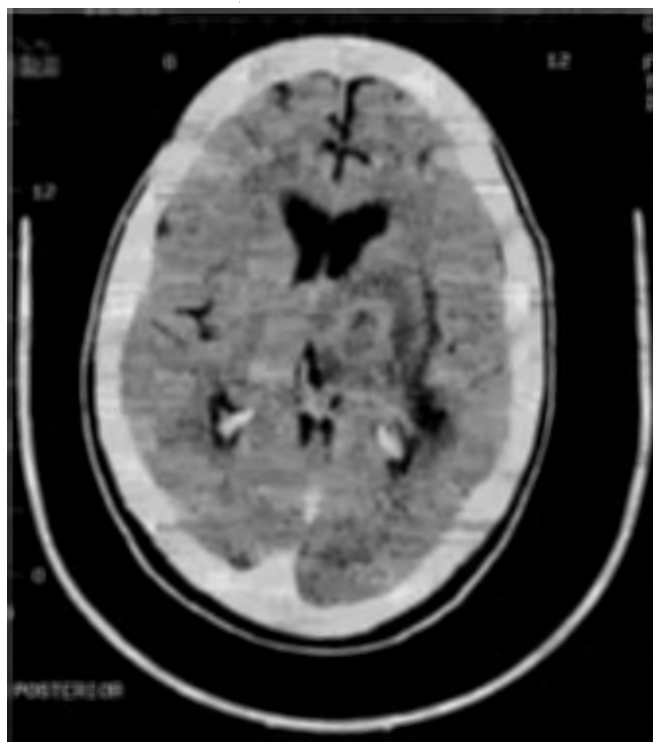

Fig. 1a. Pre-treatment contrast-enhanced CT scan showing a hypodense lesion in the left basal ganglia with rim enhancement and surrounding oedema, causing effacement of the third ventricle and midline shift.

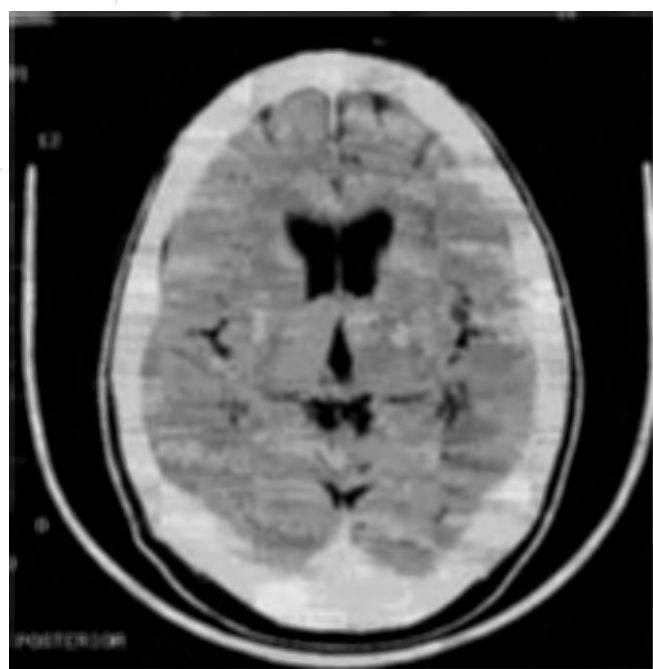


Fig. 1b. Post-treatment contrast-enhanced CT scan of the same patient showing resolution of the oedema, decrease in contrast uptake and residual hypodensity.

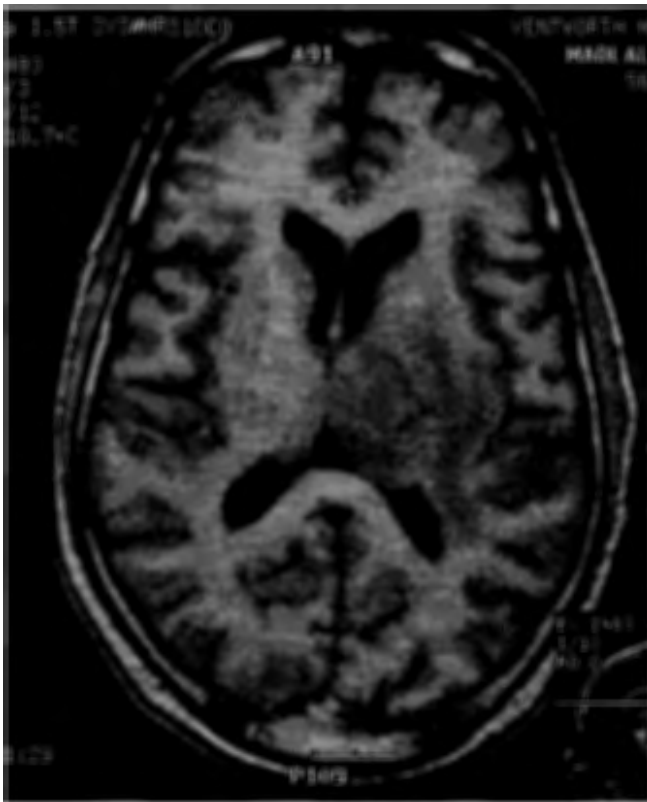
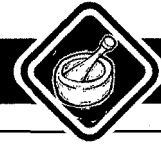
Fig. 2a. Pre-treatment T1 MRI scan showing hypodense lesion in the left basal ganglia with mass effect and midline shift.

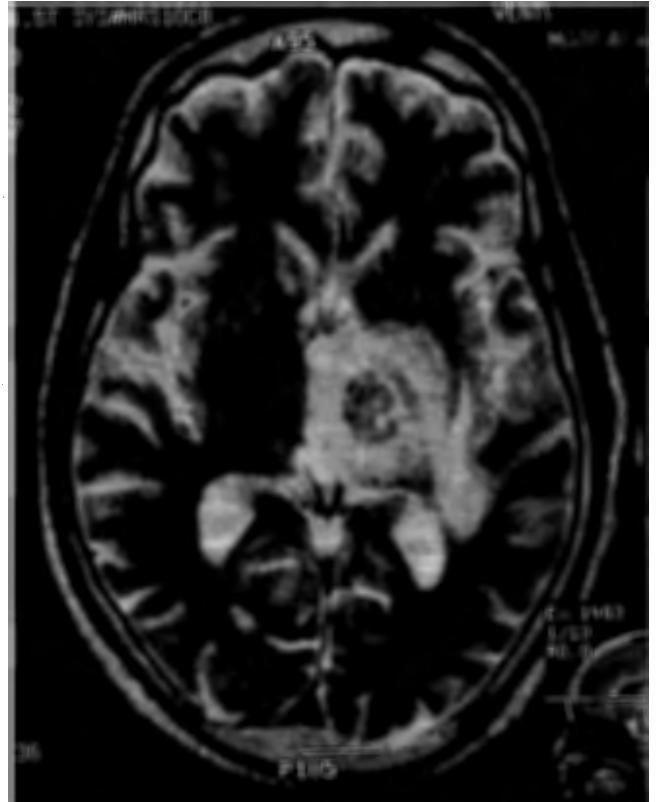


Fig. 2b. T2 MRI picture of the same area showing central hypodensity and surrounding high signal.

A limitation of this study is that many of the non-responders declined a biopsy and were treated empirically. Hence the aetiology of these lesions remains hypothetical. It is therefore unclear whether all non-responders have an alternative diagnosis or whether there is a sub-group of cerebral toxoplasmosis that is unresponsive to co-trimoxazole therapy.

## Conclusion

Oral co-trimoxazole is effective for acute toxoplasma encephalitis in doses of 2 tablets 4 times daily for 1 month followed by 2 tablets twice daily as secondary prophylaxis for life. Lifetime prophylactic therapy for toxoplasmosis would only apply if patients are not receiving antiretroviral therapy with the CD4 count being under 200 cells/ $\mu$ l.

## References

1. Bhigjee AI, Naidoo K, Patel VB, Govender D. Intracranial mass lesions in HIV positive patients: the KZN experience. *S Afr Med J* 1999; **99**: 1284-1288.
2. Lepout C, Raffi F, Matheron S. Treatment of central nervous system toxoplasmosis with pyrimethamine-sulfadiazine combination in 35 patients with the acquired immunodeficiency syndrome. Efficacy of long-term continuous treatment. *Am J Med* 1988; **84**: 94-100.
3. Georgiev VT. Opportunistic nosocomial infections. Treatment and developmental therapeutics. *Toxoplasmosis. Med Res Rev* 1993; **13**: 529-568.
4. Haverkos HW. Assessment of therapy of toxoplasma encephalitis. The TE study group. *Am J Med* 1987; **82**: 907-914.
5. Torre D, Speranza F, Martegani R, Zeroli C, Banfi M, Airolidi M. A retrospective study of treatment of cerebral toxoplasmosis in AIDS patients with trimethoprim-sulphamethoxazole. *J Infect* 1998; **37**: 15-18.
6. Torre D, Casari S, Speranza F, et al. The Italian collaborative group. Randomised trial of trimethoprim-sulfamethoxazole versus pyrimethamine-sulfadiazine for therapy of toxoplasma encephalitis in patients with AIDS. *Antimicrobial Agents Chemother* 1998; **42**: 1346-1349.

Accepted 3 November 2003.