



## The utility of computed tomography for recent-onset partial seizures in childhood

George H Swingler, Anthony T R Westwood, Karen Iloni

**Objectives.** To determine the diagnostic yield of computed tomography (CT) of the head in children presenting for the first time with partial seizures in a region with a high prevalence of tuberculosis and neurocysticercosis.

**Design.** Prospective cohort study.

**Setting.** The secondary-level ambulatory service of Red Cross Children's Hospital, Cape Town.

**Subjects.** Children aged 6 months - 12 years with a first partial seizure.

**Outcome measures.** Abnormal CT findings; clinically unsuspected abnormal CT findings.

**Results.** Of 118 enrolled children, CT findings were available for 94 (80%). Sixteen (33%) of 49 children scheduled to return later for an initial CT scan failed to do so. Thirty-two scans (34%) were reported normal, 45 (48%) showed single or multiple granulomas, and 17 (18%) showed other findings. All

8 children with persistent specific CT findings were suspected of having the condition before CT scan. Of 68 cases with prospectively recorded clinically expected CT findings, normal scans were expected in 2 cases (3%) and occurred in 33 cases (49%).

**Conclusions.** Routine CT scan for children presenting with a first partial seizure in an area with a high prevalence of neurocysticercosis failed to identify findings other than neurocysticercosis that meaningfully altered clinical management. Assuming a 70% relative reduction of seizures with albendazole treatment for neurocysticercosis, routine CT scanning in the study population would require 11 scans and 5 courses of albendazole to prevent 1 child from having seizures, compared with no CT scans and 11 courses of albendazole with blanket use of albendazole.

*S Afr Med J* 2006; **96**: 941-944.

It is widely agreed that neuroimaging is not required for all children with seizures.<sup>1-4</sup> Suggested selective indications for neuroimaging include partial seizures because of a higher prevalence of abnormalities, including tumours, associated with such seizures.<sup>1-4</sup> An association of partial seizures with treatable lesions has been observed in adults,<sup>5,6</sup> but partial seizures are more common in children than in adults<sup>5,7</sup> and the clinical spectrum and aetiology of seizures in children are very different. It has been found that childhood partial seizures are more likely to involve abnormal neuroimaging.<sup>8-10</sup>

When neuroimaging is required, magnetic resonance imaging (MRI) is regarded as the investigation of choice in most circumstances in industrialised countries.<sup>1-4,11</sup> However access to MRI in low- and middle-income countries is extremely limited. Computed tomography (CT) is available in some settings, but availability remains limited.

Several studies<sup>10,12,13</sup> have examined the diagnostic yield of CT in children with a first partial seizure. Although 4% of children required further diagnostic workup in one study,<sup>12</sup> it is not reported whether this work-up was followed by therapeutically important decisions. In another study,<sup>13</sup> 14 (21%) of 66 children who had CT performed had abnormal findings.

*School of Child and Adolescent Health, University of Cape Town*

**George H Swingler**, FCP (SA), PhD

**Anthony T R Westwood**, FCP (SA), MD

**Karen Iloni**, MSc, MB BCh, DCH (SA), MRCP (UK)

*Corresponding author: George H Swingler (swingler@ich.uct.ac.za)*

Two were of 'immediate therapeutic significance', but both findings were predictable from clinical history or examination. The third study<sup>10</sup> found abnormalities in 19 (18%) of 107 CT scans, but it was not reported whether these abnormalities had been suspected clinically. All three studies were retrospective or contained large retrospective elements. This is likely to have led to unrepresentative samples of children receiving scans and potential biases in the extraction of clinical data from clinical records, particularly in assessing changes in clinical management. The importance of partial seizures, or of specific clinical features in such seizures, as predictors of therapeutically important CT findings is therefore not clear.

These three studies were conducted in industrialised countries and have limited applicability to areas of the developing world with a high prevalence of parasitic brain cysts and tuberculosis (TB) and limited access to CT. Of a group of 23 neurologically normal Indian children with partial seizures (65% with first seizures), 35% had abnormal CT scans, but the patients were a selected group and not consecutive because of cost constraints.<sup>15</sup>

In Cape Town a strong impression was gained that in children over 2 years of age with a single partial seizure and no underlying neurological deficit, the overwhelming majority of therapeutically important CT abnormalities were those of neurocysticercosis or TB. The CT features of neurocysticercosis and TB are often difficult to differentiate, and our practice had been to exclude TB (using chest radiography and skin testing) and to manage the remaining patients for neurocysticercosis.



At the time that the study was planned there was little convincing evidence to support the use of albendazole for neurocysticercosis. If there were no other clinically significant causes of the seizures in this group of children, it would then have been rational to exclude TB and manage all remaining patients conservatively, as if they had normal scans or neurocysticercosis, without performing CT. Such a policy would have had considerable beneficial resource implications, particularly for patients referred long distances for scans, and would free up limited CT facilities for more fruitful investigations.

## Objective

To determine the diagnostic yield of head CT scans in children presenting for the first time with partial seizures in a region with a high prevalence of TB and neurocysticercosis.

## Methods

### Participants

Children aged 6 months - 12 years presenting for the first time with partial seizure to the secondary-level ambulatory service of Red Cross Children's Hospital, Cape Town, were prospectively enrolled from 12 October 1999 to 31 December 2002. Details of history and clinical examination, as listed in Table I, were recorded by the clinician caring for the child on a pro forma record sheet adapted to form part of the routine clinical record. In children whose CT findings were not already known the clinicians also recorded their expected CT findings. The investigators extracted the CT findings from the formal radiological report, and extracted details of actual clinical management and follow-up from the routine clinical notes.

CT findings were categorised as normal, granuloma (single or multiple, with or without calcification), incidental findings without clinical significance (reported as such or ignored by the clinicians), findings of uncertain significance, and specific findings other than granuloma.

Agreement between the clinicians' expected findings and the actual CT findings was adjusted for chance agreement using the kappa statistic. A planned multiple regression analysis to identify clinical predictors of specific scan findings was not performed because it was judged not to be clinically meaningful, given the small number and very heterogeneous nature of findings other than granuloma.

### Ethical approval

The study was approved by the Research Ethics Committee of the University of Cape Town.

## Results

One hundred and eighteen children were enrolled. CT scan findings were available for 94 (79.7%). The reasons for loss

to follow-up of other participants are shown in Fig. 1, and were mainly due to missed appointments for the CT scan. The clinical characteristics of children for whom CT scans were performed are shown in Table I.

Of the 95 children who had CT scans, 32 (34%) were reported as normal, 45 (48%) showed single or multiple granulomas, and 17 (18%) showed other findings, while in 1 case no record of the findings was traceable. A breakdown of the findings is shown in Table II.

**Table I. Characteristics of children with CT scan reports**

	N	(%)
Age in months (median, IQ range)	94	64, 33 - 99
Gender (male)	94	46 (49)
Complex seizure	85	68 (80)
Right-sided seizure	92	47 (51)
Duration of seizure in minutes (median, IQ range)	73	30, 10 - 60
Fever (reported by caregiver)	93	16 (17)
Preceding headache	87	17 (20)
Preceding vomiting	91	20 (22)
Tuberculosis contact	92	12 (13)
Developmental delay	91	5 (6)
Developmental regression	92	0
Recent change in behaviour or school performance	91	1 (1)
Papilloedema (when fundi seen)	42	0
Neck stiffness	91	5 (6)
Cranial nerve palsy	93	5 (5)
Hemiplegia	93	6 (6)
Cranial nerve palsy or hemiplegia	93	9 (10)

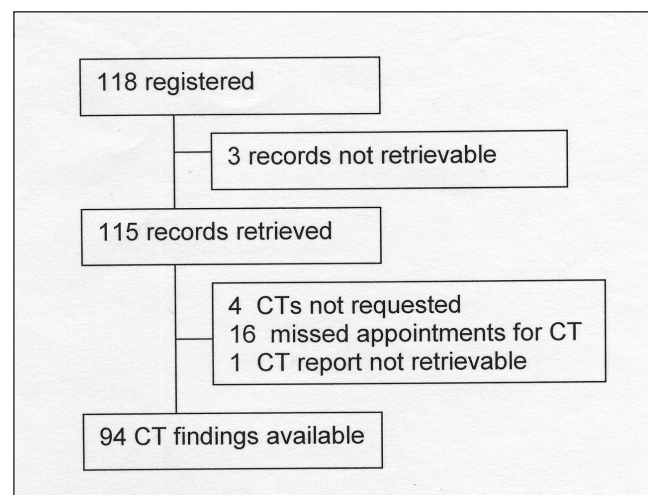


Fig. 1. Lost to follow-up.



**Table II. Findings on CT scan**

	N (%)	95%CI
Reported as normal	32 (34)	24 - 44%
Granuloma	45 (47)	
Single	26 (27)	37 - 58%
Single with calcification	3 (3)	
Multiple	4 (4)	
Multiple with calcification	11 (17)	
Calcification only	1 (1)	
Other	17 (18)	11 - 27%
Incidental findings reported as not clinically significant or ignored by clinicians*	5 (5)	
Findings of uncertain significance, discharged after follow-up*	4 (4)	
Specific	8 (8)	
No report <sup>†</sup>	1 (1)	
Total	95	

\*Categorised as normal in subsequent analyses.  
<sup>†</sup>Excluded from subsequent analyses.

There were findings of uncertain significance on 4 scans that resolved on follow-up. These were ill-defined lesions that disappeared or were judged insignificant after repeat CT scan. Of the 8 children with specific CT findings, all were suspected of having the condition before CT scan (Table III).

Of 68 cases where the clinician recorded the expected CT finding (normal, granuloma or other) and a CT report was available, expected findings agreed with CT findings in 31 cases (46%). Chance-adjusted agreement (kappa) was 16% (95% confidence interval (CI): -2 - 34%) (Table IV). A normal scan was expected in 2 cases (3%) and occurred in 33 cases (49%). 'Other' findings were expected in 17 cases (25%), and occurred in 5 cases (7%). Granuloma was expected in 49 cases (72%), and occurred in 30 cases (44%).

Of the 49 children scheduled to return at a later date for the initial CT scan, 16 (33%) failed to do so.

## Discussion

None of the children in this study had a meaningfully abnormal CT finding other than neurocysticercosis that was not clinically suspected before CT. Routine CT scanning did not meaningfully change the clinical management of 94 children aged 6 months - 12 years with a first presentation for partial seizure. From this sample the upper 95% confidence limit for such management change is 3.85%. That is, even at the highest CT yield that might plausibly be expected from this population, 26 CT scans would be needed to detect 1 clinically meaningful unsuspected abnormality other than neurocysticercosis.

**Table III. Specific findings on CT scan, other than granuloma**

	N	Clinical details
Atrophy	1	Developmental delay, attending special school
Tuberculous meningitis	3	Diagnosis clinically suspected in all 3 cases
Mass lesion	1	Final diagnosis tuberculous meningitis with tuberculoma. Diagnostic work-up for tuberculosis had been started before CT scan
Acute glomerulonephritis with hypertensive encephalopathy	1	Clinical diagnosis before CT scan
Fracture through ethmoid sinus	1	Fracture visible only on special CT views requested because of clinical suspicion
Benign hydrocephalus	1	Previous CT scan for macrocephaly
Total	8	

**Table IV. Agreement between clinically expected and actual CT findings (N)**

Clinical expectation	CT findings			
	Normal	Granuloma	Other	Total
Normal	2	0	0	2
Granuloma	21	26	2	49
Other	10	4	3	17
Total	33	30	5	68

There was poor agreement between clinicians' expectation and actual scan findings – only 16% after adjustment for chance agreement. The main areas of disagreement were the clinicians' overestimate of the probability of granulomata and other specific findings, and an underestimate of the probability of a normal scan, present in 49% of cases but expected in only 3%. The falsely high expectation of abnormal findings (regardless of their potential impact on clinical management) is a potential barrier to the successful implementation of guidelines for more rational use of CT scans in this context.

An incidental finding of concern in this study is the large proportion of patients lost to follow-up. One-third of children for whom outpatient CT appointments were made did not attend for the scan. If CT scans are performed, systems must be in place to ensure maximal follow-up. Routine CT scanning for partial seizure may in itself contribute to the drop-out rate by adding to pressure on existing services and extending waiting times for the procedure.



The strengths of this study include prospective enrolment that enabled more accurate collection of clinical data. The sample also included a meaningful spectrum of patients from a specified clinical setting. Retrospective folder review to measure subsequent management was unavoidable if clinical management was not to be interfered with. A weakness of the study is that children were enrolled and examined by a large number of clinicians involved in their routine care. This may have detrimentally affected the quality of clinical data and resulted in some missing data.

Although clinicians' expectations were a very poor predictor of CT findings, the CT findings had virtually no impact on diagnosis, except in the common case of granuloma. The impact of a CT finding of neurocysticercosis depends on the effectiveness of treatment for neurocysticercosis. If treatment is ineffective, the CT scan appears to have little impact on clinical management, and appears unnecessary in the absence of the clinical suspicion of a specific finding other than granuloma. If treatment with albendazole is effective, the blanket use of albendazole in all patients presenting with partial seizures may result in fewer harmful effects than incurred with routine CT scanning (e.g. radiation dose, use of scarce resources, anxiety due to inconsequential incidental findings). Assuming that a recent imprecise estimate of the effect of albendazole on reducing the number of children with seizures in the first 6 months is correct (odds ratio 0.30, 95% CI: 0.1 - 0.9),<sup>14</sup> i.e. that albendazole reduces the risk of subsequent seizures from 33% to 13%, routine CT scanning would require 11 scans and 5 courses of albendazole in our setting to prevent 1 additional child from having seizures, compared with no CT scans and 11 courses of albendazole with blanket use of albendazole.

On the basis of our findings, we are restricting the use of CT scanning in children over the age of 2 years who present to the hospital with a first focal seizure and no neurological history and no physical signs that cannot be explained by the seizure itself. Investigations are limited to a chest radiograph and tuberculin skin test. Management includes a single dose of albendazole for treatment of possible intestinal tapeworm.

The applicability of the findings of this study to other settings depends on the prevalence of the underlying pathologies. The findings appear to be broadly applicable to settings with a high prevalence of neurocysticercosis and

tuberculous meningitis. Health system issues such as loss to follow-up may occur elsewhere, suggesting that local audit may be necessary.

In summary, routine CT scan for children presenting with a first partial seizure in an area with a high prevalence of neurocysticercosis failed to identify findings other than neurocysticercosis that meaningfully altered clinical management. If treatment of neurocysticercosis with albendazole is judged to be worthwhile, the benefits of routine screening to identify patients with granulomata would depend on the prevalence of neurocysticercosis, and the trade-off between the benefits of albendazole and the harmful effects of CT scans and/or albendazole.

Funding for the study was received from the University of Cape Town.

#### References

1. Hirtz D, Ashwal S, Berg A, *et al.* Practice parameter: evaluating a first nonfebrile seizure in children: report of the quality standards subcommittee of the American Academy of Neurology, The Child Neurology Society, and The American Epilepsy Society. *Neurology* 2000; **55**: 616-623.
2. Cincinnati Children's Hospital Medical Center. *Evidence Based Clinical Practice Guideline for First Unprovoked Seizure for Children 2 to 18 Years of Age*. Cincinnati, Ohio: Cincinnati Children's Hospital Medical Center, 2002.
3. National Institute for Clinical Excellence. *The Epilepsies. The Diagnosis and Management of the Epilepsies in Adults and Children in Primary and Secondary Care*. London: National Health Service, 2004.
4. Scottish Intercollegiate Guidelines Network. *Diagnosis and Management of Epilepsies in Children and Young People. A National Clinical Guideline*. Edinburgh: National Health Service, 2005.
5. Hopkins A, Garman A, Clarke C. The first seizure in adult life. *Lancet* 1988; **1**: 721-726.
6. Young AC, Costanzi JB, Mohr PD, St Clair Forbes J. Is routine computerised axial tomography in epilepsy worth while? *Lancet* 1982; **2**: 1446-1448.
7. Warden CR, Brownstein DR, Del Beccaro MA. Predictors of abnormal findings of computed tomography of the head in pediatric patients presenting with seizures. *Ann Emerg Med* 1997; **29**: 518-523.
8. Gandon Y, Baraton J, Aicardi J, Goutieres F. Efficacy of scanography in convulsions and epilepsy in children. *La Semaine de Hopitanx* 1983; **59**: 2107-2112.
9. Berg AT, Testa FM, Levy SR, Shinnar S. Neuroimaging in children with newly diagnosed epilepsy: A community-based study. *Pediatrics* 2000; **106**: 527-532.
10. Garvey MA, Gaillard WD, Rusin JA, *et al.* Emergency brain computed tomography in children with seizures: who is most likely to benefit? *J Pediatr* 1998; **133**: 664-669.
11. Commission on Neuroimaging of the International League Against epilepsy. Recommendations for neuroimaging of patients with epilepsy. *Epilepsia* 1997; **38**: 1255-1256.
12. McAbee GN, Barasch ES, Kurfist LA. Results of computerised tomography in 'neurologically normal' children after initial onset of seizures. *Pediatr Neurol* 1989; **5**: 102-106.
13. Maytal J, Krauss JM, Novak G, Nagelberg J, Patel M. The role of brain computed tomography in evaluating children with new onset of seizures in the emergency department. *Epilepsia* 2000; **41**: 950-954.
14. Kalra V, Dua T, Kumar V. Efficacy of albendazole and short-course dexamethasone treatment in children with 1 or 2 ring-enhancing lesions of neurocysticercosis: a randomized controlled trial. *J Pediatr* 2003; **143**: 111-114.
15. Vidwas AS, Shah MD. Study of EEG and CT scan in neurologically normal cases of focal convulsions. *J Trop Pediatr* 1989; **35**: 113-116.

Accepted 26 May 2006.