

Henshaw EB
Ntia HU
Archibong JE

Dyschromatosis symmetrica hereditaria: Report of a sporadic case in a Nigerian child

DOI:<http://dx.doi.org/10.4314/njp.v41i4.20>

Accepted: 24th July 2014

Henshaw EB (✉)
 Dermalology unit,
 Department of Medical,
 Faculty of Medicine / Dentistry
 University of Calabar, Nigeria.

Ntia HU
 Department of Paediatric,

Archibong JE
 Department of Medicine,
 University of Calabar Teaching Hospi-
 tal Calabar, Nigeria.

Abstract Dyschromatosis symmetrica hereditaria (DSH) is one of a group of reticulate pigment disorders of the skin. It is a rare autosomal dominantly inherited genodermatosis, presenting as mottled admixtures of hypopigmented and hyperpigmented macules on the dorsa of the extremities. It is predominantly found among persons of Oriental origin. We hereby document the first case of dyschromatosis symmetrica hereditaria in a four year old Nigerian boy who presented

with progressive symmetric dyschromic lesions on the dorsa of the hands and feet, with no family history of similar lesions. The diagnosis was confirmed by the typical histologic finding of basal hyperpigmentation with normal number of melanocytes and absence of melanin incontinence from a hyperpigmented lesion

Keywords: Dyschromatosis Symmetrica Hereditaria, Nigerian, Sporadic

Introduction

Dyschromatosis symmetrica hereditaria (DSH) (aka. Reticulate acropigmentation of Dohi) is a rare genodermatosis which was first described in Japan¹ and has been more widely reported among Asian populations²⁻⁴. There have also been few reports among Caucasians and in some Middle Eastern countries⁵⁻⁷. It presents with asymptomatic symmetrical reticular admixtures of hyperpigmented and hypopigmented macules on the dorsa of the hands and feet, and sometimes with freckle-like macules on the face. The condition usually starts in infancy or childhood and progressively increases until adolescence when it stops spreading. Various therapeutic agents have been employed in the treatment of this condition including topical steroids, calcipotriol and psoralen plus UVA (PUVA), but none has been effective. This report aims to acquaint clinicians on the existence of DSH in Nigeria, thus increasing the list of differential diagnoses of pigmentary disorders in our environment. It will also add to the existing global body of knowledge.

Case Report

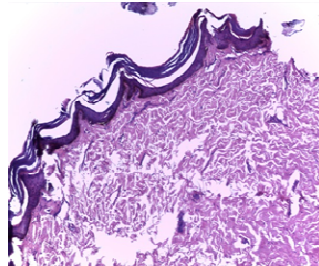
A four year old boy of the Igbo tribe in South-eastern Nigeria was brought by an overtly anxious mother to the paediatric dermatology clinic of the University of Calabar Teaching Hospital (UCTH) with a history of progressively increasing symmetrical mottled hypopigmented and hyperpigmented lesions on the dorsa of both hands and feet which started when he was one year old. There was no associated pruritus, localized abnormality of sweating, neither was there contact with any

melanotoxic chemicals nor any preceding inflammatory skin disorder such as pityriasis alba, pityriasis lichenoides chronica or psoriasis in the affected area prior to the appearance of the pigmentary changes. The lesions were limited to the dorsa of the hands and feet, did not affect the palms, soles, face, axilla, trunk or mucous membrane. (Figure 1) There were no similar lesions in parents, siblings or other known family members and he is the product of a non-consanguineous marriage. His delivery was normal, with attainment of normal developmental milestones. There were no other systemic symptoms, no evidence of photosensitivity, and his general health was good with a weight of 84.4% of the expected. Examination of the hands and feet revealed reticulate hyper and hypopigmented macules extending proximally from the dorsal surfaces of the fingers and toes to the wrists and ankles respectively, the skin texture was normal and there were no pits or breaks in the linear ridges of the palms. There were no similar lesions on other parts of the body. Systemic examination was essentially normal, full blood count and urinalysis yielded no abnormality and biopsy of a hyperpigmented macule showed focal reticulated papillomatosis alternating with epidermal atrophy. There was basal hyperpigmentation with normal number of melanocytes and absence of melanin incontinence. (Figure 2) Based on the typical clinical presentation and suggestive histologic finding a diagnosis of Dyschromatosis symmetrica hereditaria was made. The family was informed about the natural history of DSH and counselled on their expectations regarding treatment and resolution, and patient was given a yearly appointment

Fig 1: Mottled hyper- and hypopigmentation on the dorsa of the feet

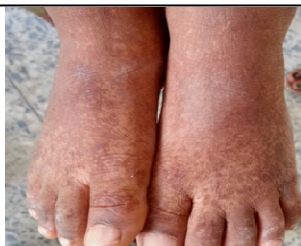

Fig 2: Photomicrograph of biopsied lesion from dorsum of the hand. (H & EX 10)



Discussion

Dyschromatosis symmetrica hereditaria is a rare genetic disorder of skin pigmentation, which was initially thought to be a Japanese-specific genodermatoses. It is often shown to have an autosomal dominant pattern of inheritance⁴; however, there have been reports of autosomal recessive⁷ and sporadic cases⁵. The latter which is the mode seen in our index patient, with no known family history of the condition. Mutations occur in the RNA-specific adenosine deaminase gene (ADAR1), and more than 122 of such mutations in this gene have been reported⁸. It phenotypically presents as pinpoint or pea-sized symmetrical mottled hypo- and hyperpigmented macules, typically in an acral distribution. There may be associated freckle-like macules on the face, extension of acral lesions proximally and lesions on the chest^{3,4}. Onset of DSH is usually in infancy and childhood, with progression and eventual stabilization prior to adolescence and this lasts for life, however, Gaiowski⁹ reported a late onset presentation, with acral lesions beginning at the age of 26 years.

A number of other reticulate pigmentary disorders exist which must be differentiated from DSH, they include: dyschromatosis universalis hereditaria (DUH), which in contrast to DSH has a more widespread distribution; reticulate acropigmentation of Kitamura (RAK) which presents with mottled solely hyperpigmented lesions also on the dorsal extremities with associated palmar

pits and breaks in dermatoglyphics; Dowling-Degos disease which has a similar clinical presentation with RAK, but lesions are found in the flexures and large body folds and Galli-Galli disease with a distinctive histologic finding of suprabasal acantholysis¹⁰. The typical histopathologic finding in DSH is, increased melanin pigment in the basal layer and throughout the epidermis in hyperpigmented lesions, and reduced or absent melanin in hypopigmented lesions, all with normal number of melanocytes. In addition to the above findings our patient also had epidermal atrophy which is not a distinctive feature of DSH, however Peng et al⁴ reported a case of DSH, howbeit with focal epidermal atrophy on histology, mutation analysis confirmed the diagnosis of DSH. Epidermal atrophy is more commonly found in acropigmentation of Kitamura (RAK), however, there is often an increase in the number of basal melanocytes (which was not observed in our patient's histology) and the clinical picture is also different. DSH has been associated with a number of disease entities, including dystonia, mental retardation, neurofibromatosis, seizure, autism, urticaria, mood disorder, β thalassemia and polydactyly^{4,6,11} but none of these associations have been consistent. There was no similar or novel association in our patient. Treatment of DSH has included the use of topical steroids, pimecrolimus, calcipotriol and Psoralen plus UVA (PUVA) all of which have not led to resolution of the condition^{5,7}.

Conclusion

In conclusion, this report has documented the existence of dyschromatosis symmetrica hereditaria in Nigeria; a condition which may be misdiagnosed as vitiligo, leading to the unnecessary use of potentially harmful and/or expensive therapies by clinicians^{5,7}.

It is hoped that our report has increased the list of differentials of pigmentary disorders in our environment, where most hypopigmentary lesions are often considered to be leprosy by the lay public. (a condition associated with a high degree of stigmatization). We have also highlighted the need for follow-up of children with DSH for the future documentation of known or novel associations

Conflict of interest: None

Funding: None

References

1. Toyama I. An unknown disorder of hyperpigmentation. *Jap J DermatolUrol* 1910 ; 10 : 644(In Japanese)
2. Oyama M, Shimizu H, Ohata Y, Tajima S, Nishikawa T. Dyschromatosissymmetricahereditaria (reticulate acropigmentation of Dohi): report of a Japanese family with the condition and a literature review of 185 cases. *Br J Dermatol*1999; 140(3): 491-6.
3. He PP, He CD, Cui Y et al. Refined localization of dyschromatosissymmetricahereditaria gene to a 9.4-cM region at 1q21-22 and a literature review of 136 cases reported in China. *Br J Dermatol* 2004;150(4):633-9
4. Peng AC, Chen Y, Chao S. Dyschromatosissymmetricahereditaria: A retrospective case series and literature review. *DermatologicaSinica* 2013; 31: 19-24
5. Consigli J, Gomez Zanni C, Ragazzini L, Daniello C. Dyschromatosissymmetricahereditaria: report of a sporadic case. *Int J Dermatol* 2010;49: 918-20
6. El Darouti M, Marzouk SA, Fawzi M et al. Reticulate acropigmentation of Dohi: A report of two new associations. *Int J Dermatol* 2004;43:595-6

-
7. Alfadley, A., Al Ajlan, A., Hainau, B., Pedersen, K.-T., Al Hoqail, I. Reticulate acropigmentation of Dohi: a case report of autosomal recessive inheritance. *J Am. Acad. Derm* 2000; 43: 113-117
 8. Lai ML, Yang LJ, Zhu XH, Li M. A novel mutation of the DSRADgene in a Chinese family with dyschromatosis asymmetrica hereditaria. *Genet Mol Res* 2012;11: 1731-7
 9. Gaiowski CB, Serafini SZ, Werner B, Deonizio JMD. "Dyschromatosis asymmetrica hereditaria of late onset?" Case Reports in Dermatological Medicine, vol. 2014, Article ID 639537, 3 pages, 2014. doi:10.1155/2014/639537
 10. Müller CSL, Tremezaygues L, Pfohler C, Vogt T. The spectrum of reticulate pigment disorders of the skin revisited. *Eur J Dermatol* 2012; 22(5): 596-604
 11. Tan HH, Tay YK. Neurofibromatosis and reticulate acropigmentation of Dohi: A case report. *Pediatr Dermatol* 1997; 14: 296-8