

**Johnson A-W BR  
Abdulkarim A A  
Adedoyin O T  
Adegboye A O  
Amole A O D**

## Anhidrotic ectodermal dysplasia: a case report in a Nigerian child and literature review

DOI:<http://dx.doi.org/10.4314/njp.v39i2.9>

Received:16th December 2011

Accepted:3rd January 2012

Abdulkarim AA (✉)  
Johnson A-W BR, Adedoyin O T,  
Adegboye A O  
Department of Paediatrics and  
Child Health,  
Amole A O D  
Department of Radiology  
University of Ilorin Teaching  
Hospital,  
PMB1459 Ilorin, Nigeria.  
E-mail : aishaakarim@yahoo.com  
Tel: +2348033734509

**Abstract** This report of Hereditary anhidrotic ectodermal dysplasia (HAED), a genetic disorder characterized by abnormalities of structures of ectodermal origin, was informed by its rarity, and its import for survival in a tropical environment. The five-year old male was first seen on account of inability to cut the front teeth, and a persistent offensive nasal discharge. He had heat intolerance and inability to perspire from early infancy. Pedigree evaluation revealed that both parents are Nigerians and unrelated, but the maternal front dentition was visibly defective. A 19-year old female sibling needed dentures at 10 years of age, while the father was one of two survivors out of 12 children, eight of whom were males. Findings included hypotrichosis; “saddle-nose” deformity and an

offensive nasal discharge; the skin was thin, warm and dry; he had no incisors and canines, but had a single erupted premolar on either side and radiographic evidence of unerupted premolars was found. Genetic counseling and parental anticipatory guidance were offered, as was antimicrobial treatment for the co-morbid atrophic rhinitis. Dentures were deferred on the dentist's advice.

This case report of HAED in a Nigerian was aimed at raising the local index of clinical suspicion by highlighting the reality of rarities, even with inadequate diagnostic support. The diagnostic parameters, literature review and the management strategies are discussed.

**Key words:** Anhidrotic ectodermal dysplasia; hypotrichosis; oligodontia; Nigeria

### Introduction

Hereditary ectodermal dysplasia (HED) is a rare condition characterized by varying defects in the development of structures derived from the embryonic ectoderm, except those of the neural plate.<sup>1,2</sup> The two major clinical variants of HED are differentiated based on the presence or otherwise of significant anhidrosis.<sup>2</sup> Although autosomal dominant forms had been suggested in some pedigrees, the mode of inheritance of HAED is frequently X-linked recessive.<sup>1-6</sup> Characteristic features include oligodontia involving the deciduous teeth (with few or no permanent teeth), hypotrichosis, and paucity or absence of the sweat glands with resultant severe thermoregulatory consequence(s) of anhidrosis, heat intolerance and/or recurrent fever.<sup>1-5</sup> Additionally, there is a fairly characteristic craniofacial appearance.

Conjunctivitis, chronic atrophic rhinitis, and hoarseness constitute the clinical consequences of dysplastic lachry-

mal glands and a mucosal defect affecting the pharynx/upper respiratory tract respectively.<sup>1-6</sup> Rarely, dysplastic nails, hypoplastic mammary glands and cornea have been documented.<sup>1,3,5</sup>

Against the background of the well known Darwinian concept of “Survival of the fittest”, the evolutionary import of a primary failure of sweating in the hot tropical environment is self-evident. Indeed, a conceivable “reverse” selection pressure may explain the rarity of the anhidrotic variety in the tropical environment.

Furthermore, ubiquitous tropical childhood infections with potentially life-threatening consequences like hyperpyrexia, complex febrile convulsion, heat stroke, and brain damage may have contributed to the rarity of the disorder in the tropics.<sup>3,6</sup> The current body of knowledge on HAED is based largely on reports of Caucasians living in the cooler temperate environment. Although some of the earlier observations on this disorder emanated from the Hindus, Tamils and Sinhalese commu-

nities of the Asian subcontinent,<sup>7</sup> to the best of the authors knowledge, only four reports in probands of Negro ancestry exist in accessible English literature<sup>5,6,8,9</sup>.

In a local report, the focus was on the oral manifestations and orthodontic management, rather than the holistic clinical characteristics.<sup>11</sup> We report HAED in an indigenous African as well as provide a critical review of the diagnostic prerequisites of the disease.

### Case report

The proband, SA (Reg. No. 195484) was a five-year old male Nigerian, who was brought for consultation to the University of Ilorin Teaching Hospital (UIH) by his 41-year old mother. The principal concern was the child's inability to cut the front teeth at his age. The first set of teeth were the upper pre-molars which did not appear until age three years, and at presentation he had cut two on either side of the upper and lower jaws. Further questioning revealed he had heat intolerance and suffered from recurrent fever since birth with frequent afternoon exacerbation during dry season. Furthermore, he has never been noticed to perspire, even when the environment was hot. Over the years, parents have learnt to maintain cooling outdoors with regular body sponging using a towel soaked in cold water. At home, frequent discomforts associated with heat intolerance have been kept to a minimum by using air-conditioners. He had thrice been hospitalized for febrile illnesses without any specific causes found and these have coincided with long periods of power outages and whenever he had to stay outdoors for long periods during the hot dry season.

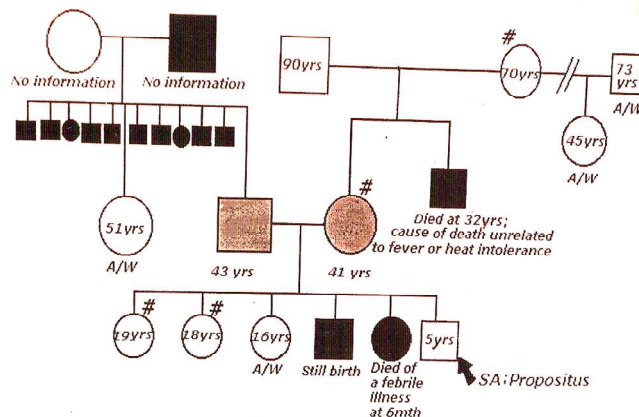
Other recurrent symptoms since early infancy included stuffy nostrils frequently associated with foul smelling nasal discharge, ozaena and occasional nighttime episodic cough.

The skin has been dry and scaly since birth, necessitating frequent change of expensive body cream and lotions. Scalp hair has remained sparse, straight and silky despite the absence of Fulani or Arab ancestry. Since he was weaned at about the age of one year, feeds have been restricted to pulverized foodstuffs, to obviate the need for chewing. Although he was once registered at a Nursery school at about the age of three years, the parents have had to withdraw him from school because of frequent paroxysms of pyrexia, jeers from older pupils and "embarrassing stares" from teachers and other parents.

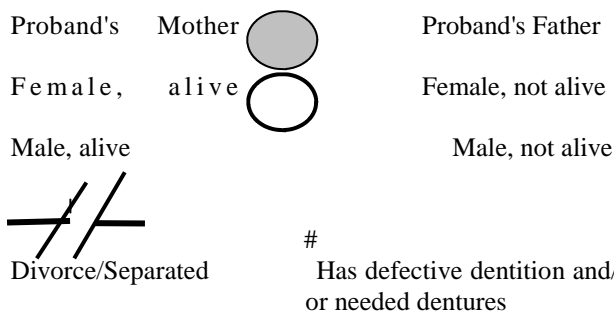
Family, Social and Pedigree History: The parents are unrelated by blood and are of above-average socio-economic status. The father is a career diplomat, while the mother, a polytechnic graduate, has a successful business outfit. The patient is the fourth of five children. One of the older siblings, a 19 year old female, required a set of orthodontic prosthesis following absence of the front teeth at the age of 11 years. She had no other overt features of HAED but the skin has also been relatively dry and rough from early childhood. Fur-

ther questioning revealed that neither parent had heat intolerance, inability to sweat or silky hair but the mother's dentition was obviously defective with poor gum anchorage and uneven spaces. She however never required dentures and could not recall having a similar delay in teeth eruption. Figure 1 summarizes the available data from the family study.

Fig 1



Key: A/W = Alive and Well



Physical examination revealed an intelligent but rather shy child with a satisfactory weight of 21kg, a normal standing height of 109.5cm and a normal occipitofrontal circumference of 51cm for the age. The upper to lower body segment ratio was normal at 1.08:1. The temperature was 37.7°C in the air-conditioned consulting room. The identifying physical findings of HAED are shown in Figure 2 there was depression of the nasal bridge giving a saddle appearance, the eye lashes were sparse, and the eye brows were virtually absent. The palpebral fissures are normal. His hair was straight, silky and scanty with areas of visible scalp skin. The lips were moderately everted and the skin (including the axillary area) was thin and dry. Neither jaw contained incisors, canines or molars (Figure 3A but four rather rudimentary and shaky premolars, (one in each jaw on either side) was evident. Other obvious abnormalities included periorbital darkening and pectus carinatum. There was no other abnormality observed on systemic examination.

Fig 2

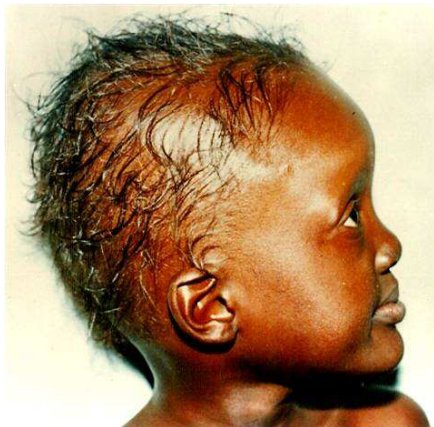

Fig 3A

Close-up views (lateral ) of the proband showing a rather prominent forehead and saddle-like depression of the nasal bridge, sparse/absent eye lashes and brows, straight, silky and scanty hair, glossy skin, as well as the moderately everted lips. A minimal deformity in the upper pole of the auricle (pinna) is also evident (lateral view).

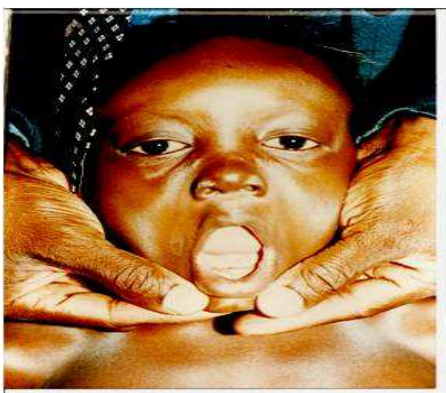

Fig 3A

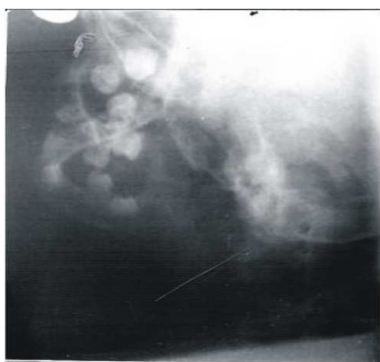

Fig 3B

Oral photograph (A) and a Lateral view of the skull radiograph (B). Note “empty” anterior segment of the gum, devoid of incisors and canines in the oral photograph, and the radiographic evidence of rudimentary/unerupted posterior teeth (3B). The peri-orbital linear wrinkles are also evident in the oral photograph (Fig. 3A).

## Investigations and Results

Radiograph of the jaws showed a few more un-erupted buds of additional premolars (Figure 3B).

The thyroid function test results were within normal limits; T3 was 1.3mg/ml (reference range: 0.8-2.1); T4 11.50 (international units/ml (reference range 0.2-5.0). There were no facilities for DNA analysis. However, extensive text reference coupled with the clinical findings and pedigree data were consistent with those of the rare HAED with a sex-linked pattern of inheritance. The mother was intimated with the diagnosis and informed about the likely mode of inheritance as well as the available therapeutic measures and preventive options. As at the last clinic visit some eight months ago the child was doing well except for the recurrent cold and heat intolerance. He had still not cut additional teeth.

## Discussion and literature review

The earliest communication on HAED was credited to Darwin in his reference<sup>13</sup> to Wedderburn's report in 1838 of "...a Hindu family in Scinde, in which ten men, in the course of four generations, were furnished in both jaws taken together, with only four small and weak incisor teeth, and with eight posterior molar." That the disorder is inherited in an X-linked fashion, can be inferred from Thunam's 1848 report<sup>14</sup> of HAED in two first cousins; a carrier state was correctly presumed in their common maternal grandmother. However, the current designation as hereditary ectodermal dysplasia of the anhidrotic type, reportedly pioneered by the 1929 clinicopathological expose of Weech<sup>1</sup> was informed by the need to distinguish it from the presumably more common hidrotic form, as well as the phenotypical mimicry of congenital syphilis. Clouston's subsequent reports<sup>15,16</sup>, predicated on a long-term study of several families in Canada,<sup>14,15</sup> constituted the earliest attempt at evolving an acceptable classification of the disease into the presumably common hidrotic type with an autosomal dominant inheritance pattern, and the X-linked anhidrotic variety. Clouston's view was corroborated by the subsequent observations of Williams and Fraser<sup>17</sup> in a study of several generations of Clouston's original probands.

The discriminatory features, natural history, and management issues of the two major forms was the focus of a comprehensive review by Blattner.<sup>2</sup> In a more recent discussion of the subject, Frire-Maia and Pinheiro<sup>18</sup> suggested there may indeed be over 121 varieties of the condition with overlapping features.

There is a paucity of reports in black Africans and Africans in diaspora and the current report constitutes to the best of our knowledge, the fifth report in a Negro family, and perhaps the third in an indigenous black African. Familusi et al<sup>6</sup>, had contended that despite the rarity of this condition in blacks, the survival of the AED

mutant gene over the ages implies some unidentified advantage of biological fitness in female carriers. The recognition of the current case despite the investigative limitations and the need for an early recognition and appropriate treatment/domestic manipulation constitute a few of the reasons for this report.

The clinician's acquaintance with the diagnostic parameters is indispensable for early recognition of HAED. The four characteristic features of HAED are identified as anhidrosis or hypohidrosis, dental abnormalities, hypotrichosis, and the characteristic facies all too well demonstrated by the present case.<sup>2,18</sup> Anodontia or oligodontia, obviously the most important parental concern in this case, is undoubtedly a near-universal clinical pointer of the disease and is demonstrated by the present case in whom the oligodontia is fairly severe. Whereas a presumptive diagnosis of EDA can be made from the clinical parameters and pedigree study, investigative strategies are aimed at confirming hypohidrosis following a thermal stress, characterizing the oligodontia, and as a prerequisite for a valid genetic counseling, ascertaining the genetic basis of the disorder. The latter involves detecting maternal carrier-state, and providing prenatal diagnosis. Hypohidrosis may be confirmed by demonstrating decreased or absent sweat pores in palmar/finger tips' ridges, or the back (using the iodine-starch test), after environmental heat exposure, or subcutaneous pilocarpine-induced (5mg) iontophoresis.<sup>4,5,7</sup>

The consequence of the sweating-related thermoregulatory defect is more likely to provoke a search for an infective aetiology, or an immune deficiency. Indeed, in the current five-year old case, the parents had long learnt to cope with this recurrent fever using simple physical measures. Although we were unable to confirm the extent of the sweating defect, hypohidrosis (as against anhidrosis) is conceivably the more likely defect in indigenous Africans. Also, the presence of features of atrophic rhinitis in our proband (with a long-standing mucopurulent nasal discharge) constitutes a clinical correlate of the mucosal defect/atrophy associated with HAED.

Whereas the hereditary basis of HAED had never been in doubt, the possible patterns of inheritance remains contentious. An X-linked recessive mode (EDA 1 mutation) remains the most popular, but autosomal dominant or recessive patterns (EDAR, EDARADD and WNT10A mutations) have been suggested in some pedigrees.<sup>15-19</sup> The current report in a male child could suggest the X-linked variant, however a recent report showed that only the WNT10A mutation carriers displayed distinctive dental phenotypes and no facial dysmorphism as is reported in the female members of the index family.

Autosomal dominant variant with variable penetrance may also be an option.<sup>20</sup> Due to the limitations in genetic analysis, these cannot be further explored. There is currently no specific therapy for HAED, but given the compatibility with a normal life-span, parental genetic counseling and anticipatory guidance particularly with respect to temperature control and the related prevention of febrile seizures and brain damage constitute important management issues.<sup>4</sup>

In those with dysplastic or atrophic lachrymal glands, synthetic tears may be required to forestall conjunctival and corneal xerosis, while the ozaena associated with atrophic rhinitis would benefit from periodic nasal irrigation and, as was carried out in this case, and antimicrobial therapy after appropriate microbiologic studies.<sup>4</sup> As was the case in an earlier local report, the provision of dentures was deferred on the advice of the dentist till an older age as it would forestall the need for subsequent alteration and replacement with growth.<sup>11</sup>

Conflict of interest: none  
Funding: none

## References

1. Weech AA. Hereditary ectodermal dysplasia (Congenital ectodermal defect): A report of two cases. *Am J Dis Child* 1929;37: 766.
2. Blattner RJ. Hereditary ectodermal dysplasia. *J Pediat* 1968; 73: 444-452.
3. McKusick VA. Ectodermal dysplasia 1, Anhydrotic; ED1 (Ectodermal dysplasia, Anhydrotic [EDA, EDA1; Christ-Siemens-Touraine syndrome [CST syndrome]; Ectodermal dysplasia, hypohidrotic[HED], Ectodermal dysplasia, hypohidrotic, X-linked [XHED; XLHED]. Online Mendelian Inheritance in Man 1986-2008. Copyright©, John Hopkins University, <http://www.ncbi.nlm.nih.gov/entrez/dispmim.cgi?id=305100> (Accessed,May4,2008).
4. Darmsadt GL, Sidbury R. Ectodermal dysplasias In: Behrman RE, Kliegman RM, Jenson HB, editors. Nelson Textbook of Pediatrics (17th ed.). Philadelphia, Saunders: An Imprint of Elsevier 2004: 2166-2167.
5. Metson BF, Williams BK. Hereditary ectodermal dysplasia of the anhydrotic type. Report of a case in a Negro *J Ped* 1952; 40: 303-9.
6. De Jager H. Congenital anhydrotic ectodermal dysplasia: case report. *J Path Bact* 1965; 90: 321-25.

7. Familusi JB, Jaiyesimi F, Ojo CO, Attah E'B. Hereditary anhidrotic ectodermal dysplasia: Studies in a Nigerian Family. *Arch Dis Child* 1975; 50: 642-647.
8. Thadani KI. The toothless men of Sindh. *J Hered* 1934; 25: 483-484.
9. De Silva PCC. Hereditary anhidrotic ectodermal dysplasia of anhydrotic type. *Quart J Med* 1939; 8: 97-102
10. Sehgal D, Chawla V, Maguire MJ. Hereditary anhidrotic ectodermal dysplasia in a Zambian Family. *E Afr Med J* 1981; 58: 374-77.
11. Denloye OO, Dosunmu OO, Aderinokun GA, Onadeko MO. Ectodermal dysplasia with hypodontia in a set of Nigerian twins - A case report. *Afr J Med med Sci* 1996; 25: 299-301.
12. Johnson A-WBR, Mokuolu OA. Russell-Silver syndrome in a Nigerian infant with intrauterine growth retardation: a case report and review of literature. *J Natl Med Assoc* 2001; 93(5): 185-94.
13. Darwin C. The variation of animals and plants under domestication (2nd edn.). London John Murray 1875:319.
14. Thurnam J. Two cases in which the skin, hair and teeth were very imperfectly developed. *Proc R M Chir Soc (Lond)* 1848;31:71-82.
15. Clouston HR. A hereditary ectodermal dystrophy. *Canad Med Assoc J* 1929; 21: 18-21.
16. Clouston HR. The major forms of hereditary ectodermal dysplasia: With an autopsy and biopsies on the anhydrotic type. *Canad Med Assoc J* 1939; 401: 1-6.
17. Williams M, Fraser FC. Hydrotic ectodermal dysplasia - Clouston's family revisited. *Canad Med Assoc J* 1967; 96: 36-40.
18. Freire-Maia N, Pinheiro M. So-called "anhidrotic ectodermal dysplasia." *Int J Derm* 1980; 19: 455-456
19. Clauss F, Maniere MC, Obry F, Waltmann E, Hadj-Rabia S, Bode-mer C et al. Dento-craniofacial phenotypes and underlying molecular mechanisms in hypohidrotic ectodermal dysplasia (HED): a review. *J Dent Res* 2008; 87(12): 1089-1099
20. Cluzeau C, Hadj-Rabia S, Jambou M, Mansour S, Guigue P, Mas-moudi S et al. Only four genes (EDA 1, EDAR, EDARADD, and WNT10A) account for 90% of hypohidrotic/anhidrotic ectodermal dysplasia cases. *Hum Mutat* 2011; 32(1): 70-72