

CASE REPORT

Bilateral Serous Retinal Detachment as a Complication of Hemolysis, Elevated Liver Enzymes and Low Platelets Syndrome

Akshay J. Bhandari, Surekha V. Bangal, Dipti D. Padghan, Pratik Y. Gogri

Department of Ophthalmology, Pravara Institute of Medical Sciences and Rural Medical College, Loni, Ahmednagar, Maharashtra, India

ABSTRACT

Preeclampsia is an obstetric disease of unknown cause that affects approximately 5% of pregnant women. The visual system may be affected with variable intensity. Bilateral, serous, nonrhegmatogenous retinal detachment is a rare complication of toxemia of pregnancy, and its pathogenesis is related to the choroidal ischemia secondary to an intense arteriolar vasospasm. In the vast majority of the cases, the detachment occurs concomitantly with hypertensive retinopathy. The majority of patients have a complete recovery of vision with clinical management and surgery is unnecessary. This is a case report of a 23-year-old patient who developed the severe form of preeclampsia and hemolysis, elevated liver enzymes and low platelets syndrome in her third pregnancy. She had progressive blurred vision, until she could see fingers up to 3 meter. Ophthalmic examination diagnosed bilateral retinal detachment. With blood pressure control at postpartum, the patient had her retina reattached, and recovery of vision.

Keywords: Eclampsia, exudative retinal detachment, preeclampsia

INTRODUCTION

Pregnancy induced hypertension is defined as the hypertension that develops as a direct result of gravid state. It includes Gestational hypertension; preeclampsia and Eclampsia.^[1] The visual system may be affected with variable intensity. Retinal detachment is a rare complication of preeclampsia, affecting 1–2% of patients with its severe form and 10% of those with eclampsia.^[2] Choroidal ischemia consequent to terminal arteriolar vasospasm affects the retinal pigment epithelium and leads to the breakdown of the blood-retinal barrier, leakage of proteins and fluid from the choriocapillaries into the subretinal space and exudative retinal detachment.^[3] The majority have

a complete recovery within weeks after delivery, and there is no need for any intervention.^[4,5]

CASE REPORT

A 23-year-old booked registered case of gravida 3; parity 2 was admitted at 32 weeks gestation with pedal swelling, mild headache for 8 days and blurring of vision, which commenced 6 h prior to presentation. Her previous medical, obstetrical and menstrual history was unremarkable. Patient did not have a history of any systemic disease. General examination showed a fully conscious patient with blood pressure (BP) of 160/96 mm Hg, normal tendon reflexes with presence of bilateral pedal edema. Abdominal examination revealed a gestational size of 32 weeks, longitudinal lie of fetus and cephalic presentation. Ultrasonography confirmed a singleton, live pregnancy. Ophthalmic examination revealed visual acuity of finger counting at 3 meter in both eyes, which did not improve with pinhole. Anterior segment examination of both eyes was normal. Indirect ophthalmoscopy showed normal optic

Access this article online

Quick Response Code



Website:

www.nigerianjournalofophthalmology.com

DOI:

10.4103/0189-9171.154616

Address for correspondence

Dr. Akshay J Bhandari, Department of Ophthalmology, Pravara Institute of Medical Sciences and Rural Medical College, Loni - 413 736, Ahmednagar, Maharashtra, India. E-mail: kiwis143@gmail.com

disks (ODs), macula, and tortuous retinal vessels. Bilateral exudative retinal detachments (RD) were detected superotemporal and inferotemporal to the ODs involving the macula [Figures 1 and 2]. Fundus photography was not carried out on that day due to the critical condition of the patient. Laboratory tests including coagulation screen, serum electrolytes and renal function tests were normal. Platelet count was 40,000 with elevated liver enzymes. Urinalysis showed 3 + proteinuria. Patient was started on nifedipine for the control of BP. However, the cervical assessment revealed a Bishop's score of 7, which is favorable for vaginal delivery, and she went into spontaneous labor after induction. She had a normal vaginal delivery of a baby girl, weighing 1716 g with good Apgar score. The following day (the 1st day postpartum), the ophthalmic review revealed a significant reduction in the extent and height of the RD. She was discharged after 1-week, in good condition. 1-month later, complete resolution of the RD without sequelae was revealed. Patient was having visual acuity of 6/9 and 6/6 in eyes, 1-week and 1-month after delivery respectively.

DISCUSSION

Preeclampsia is an obstetric disease of unknown cause that affects approximately 5% of pregnant women. It can occur anytime after 20 weeks of gestation and up to 6 weeks postpartum.^[1] It is characterized by the presence of elevated BP, proteinuria >0.3 g in 24 h and edema. In its severe form there are observed elevated BP (>160/110 mmHg, or an increase in 30 mmHg in diastolic pressure), proteinuria >2 g in 24 h, central nervous system disturbances, irritability, headache, vomits, oliguria, elevated BUN, pain in the right upper quadrant and/or epigastrium, visual spots and fundoscopic changes. Hemolysis elevated liver

enzymes and low platelets syndrome may occur in a patient with a severe form and is characterized by thrombocytopenia, hemolysis and elevated liver enzymes.^[1] The development of seizures in a pregnant woman with preeclampsia makes the diagnosis of eclampsia and usually leads the patient to coma. Retinal detachment is a rare complication of preeclampsia, affecting 1–2% of patients with its severe form and 10% of those with eclampsia. It is usually bilateral, bullous and serous. The majority of patients, who manifest serous detachment during pregnancy with clinical management, have a complete recovery within weeks after delivery.^[4] This case shows the good clinical outcome of retinal detachment in preeclampsia clinically managed. It is useful for the ophthalmologists to be aware that retinal detachment may present in the absence of other hypertensive retinal changes. Finally, the favorable prognosis and natural course of this clinical condition should always be emphasized to the patient relieving them from unnecessary distress.

CONCLUSION

Exudative retinal detachment is an unusual but well-documented complication of hypertensive disorder in pregnancy.^[5] Frequent follow-up, monitoring and control of BP is necessary to prevent and diagnose the cases of retinal detachment so that emergency obstetrical intervention can be done to prevent the further complications. Retinal changes progress with severity of pregnancy induced hypertension. Ocular examination reveals important objective information concerning the disorder. It is essential to examine each and every patient of preeclampsia and eclampsia for ocular manifestations, which should be helpful for obstetrician in the management of patient.

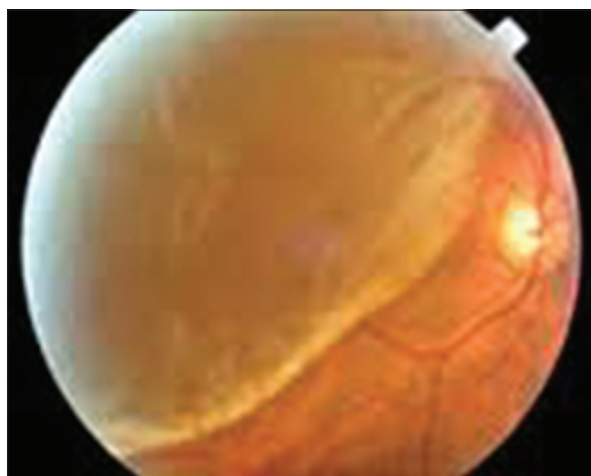


Figure 1: Right eye showing exudative retinal detachment

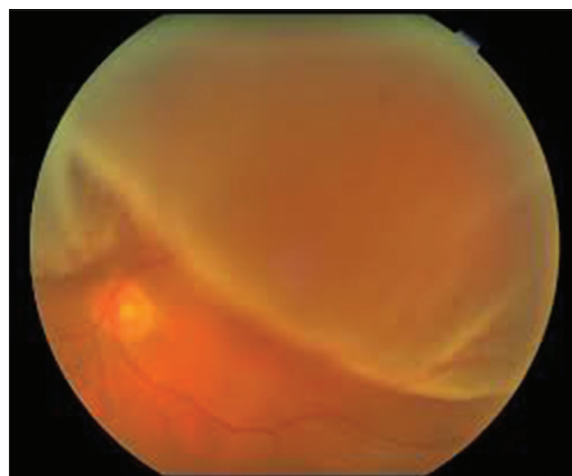


Figure 2: Left eye showing exudative retinal detachment

REFERENCES

1. Pritchard JA, MacDonald PC, Grant NF. Williams Obstetrics. 17th ed. Norwalk: Appleton-Century-Crofts; 1985. p. 119-37.
2. Aburymra S. Doenças retinianas da gravidez. In: Retina e Vítreo. Clínica e Cirurgia. Sociedade Brasileira de Retina e Vítreo e Conselho Brasileiro de Oftalmologia ed. São Paulo: Editora Roca; 2000. p. 584-5.
3. Landau D, Seelenfreund MH, Tadmor O, Silverstone BZ, Diamant Y. The effect of normal childbirth on eyes with abnormalities predisposing to rhegmatogenous retinal detachment. Graefes Arch Clin Exp Ophthalmol 1995;233:598-600.
4. Wang CL. Exudative retinal detachment in the pregnancy-induced hypertension syndrome. Zhonghua Yan Ke Za Zhi 1992;28:77-9.
5. Lee C, Hsu TY, Ou CY, Chang SY, Soong YK. Retinal detachment in postpartum preeclampsia and eclampsia: Report of two cases. Changgeng Yi Xue Za Zhi 1999;22:520-4.

How to cite this article: Bhandari AJ, Bangal SV, Padghan DD, Gogri PY. Bilateral Serous Retinal Detachment as a Complication of Hemolysis, Elevated Liver Enzymes and Low Platelets Syndrome. Niger J Ophthalmol 2014;22:87-9.

Source of Support: Nil, **Conflict of Interest:** None declared