

## ORIGINAL ARTICLE

# Surgical Eye Removal in Ile-Ife, Nigeria

Oluwaseun O. Awe, Adenike O. Adeoye, Oluwatoyin H. Onakpoya

*Eye Care Centre, Obafemi Awolowo University Teaching Hospital, Ile-Ife, Nigeria***ABSTRACT**

**Objective:** To determine the indications and pattern of surgical removal of the eyeball at a Tertiary Hospital in South Western Nigeria. **Materials and Methods:** Retrospective review of case files and theatre records of all patients who had evisceration, enucleation, or exenteration at the ophthalmic theatres of Obafemi Awolowo University Teaching Hospital, Ile-Ife between July 2005 and June 2013 was done. Information on age, sex, indication for surgery, and the type of surgery was analyzed using SPSS 16 software. **Results:** Eighty eyes of 79 patients, age, ranged from 3 months to 88 years with a male: female ratio of 3.4:1 were surgically removed. The major indications for surgery were ocular trauma (43.8%), orbito-ocular neoplasm (22.5%), fulminant ocular infection (15%), and staphyloma (12.5%). Children accounted for 33.8% of all cases reviewed. **Conclusion:** Indications for eye removal in our geographical area of practice are largely preventable and similar to those reported in major Nigerian cities and other developing countries, but dissimilar to what obtains in many developed countries.

**Keywords:** Enucleation, evisceration, exenteration, eye removal

**INTRODUCTION**

Removal of an eye is one of the most serious and difficult decisions a patient and physician must consider and usually only recommended as a last resort. Serious consideration must be given to the psychological implication of submission to irreversible visual loss. Surgical eye removals have been performed in medical practice for hundreds of years. In the medieval period, enucleation of eyes and making blind was a punishment for crimes committed.<sup>[1]</sup> Noyes first reported evisceration of the ocular contents in 1874.<sup>[2]</sup> Common indications for surgical eye removal in modern times include: Orbito-ocular tumors, curtail fulminant infections, eliminate the risk of sympathetic ophthalmitis in ruptured globes, relieve intractable painful blind eye as well as improve cosmetic appearance of individuals with blind unsightly eyes.<sup>[3]</sup>

**Address for correspondence**

Dr. Oluwaseun O. Awe, Eye Care Centre, Obafemi Awolowo University Teaching Hospital, Ile-Ife, Nigeria.  
E-mail: [linkseunawe@gmail.com](mailto:linkseunawe@gmail.com)

**Access this article online****Quick Response Code****Website:**

[www.nigerianjournalofophthalmology.com](http://www.nigerianjournalofophthalmology.com)

**DOI:**

\*\*\*

Surgical eye removal procedures include evisceration, enucleation, and exenteration. It excludes autoenucleation and ritual enucleation. Enucleation refers to the surgical removal of the entire globe. Evisceration involves the removal of the intraocular contents while exenteration of the orbit refers to the surgical removal of the eye and the affected orbital contents with or without the eyelids.<sup>[3]</sup> The most commonly performed procedures are evisceration and enucleation.<sup>[4]</sup> The indications for surgical removal of the eye appear to be the same worldwide.<sup>[3,4]</sup> The relative importance of each etiology, however, seems to differ from place to place, and this appears to be related to the level of development and sociocultural dynamics of each specific setting.<sup>[5]</sup> In many developed countries, the major indications are orbito-ocular tumors and painful blind eye whereas in the developing world these are often of traumatic and infectious origin.<sup>[5-7]</sup>

This study aims at determining the indications and pattern of these procedures in the geographical area served by the hospital to help formulate appropriate

This is an open access article distributed under the terms of the Creative Commons Attribution-NonCommercial-ShareAlike 3.0 License, which allows others to remix, tweak, and build upon the work non-commercially, as long as the author is credited and the new creations are licensed under the identical terms.

**For reprints contact:** [reprints@medknow.com](mailto:reprints@medknow.com)

**How to cite this article:** \*\*\*

intervention strategies to help reduce the need for performing destructive eye surgeries.

## MATERIALS AND METHODS

This was a retrospective study which involved the review of case files and surgical records of all patients who underwent evisceration, enucleation, or exenteration between July 2005 and June 2013 performed in the ophthalmic theatres of Obafemi Awolowo University Teaching Hospital, Ile-Ife. Information collected included basic demographic data, diagnosis on admission, laterality, and type of surgical procedure. The primary clinical indications for surgical eye removal were categorized into five groups namely: Trauma, orbito-ocular neoplasm, infections, staphyloma, and others. Age was further categorized into three groups of below 15 years as “paediatric,” those 15–59 years as “adults,” and those 60-year-old and above were classified as “elderly.” Ethical clearance was obtained from the local Institution Ethical Review Board.

All the collected data were analyzed with Statistical Package for Social Sciences (SPSS, Inc, Chicago, Illinois, USA) for Windows version 16.0 software. Descriptive statistics were used to summarize the characteristics of the studied subjects.

## RESULTS

A total of 80 eyes of 79 patients were either eviscerated, enucleated, or had modified exenteration over the study period. Surgical eye removal was uniocular in all but one patient who had a bilateral removal. Besides the primary indication for eye removal, all affected eyes were blind with best corrected visual acuity of  $<3/60$ .

The median age of the patients was 28 years with a mean age of  $30.7 \pm 24.2$  years and a range of 3 months

to 88 years. Twenty-seven (34.2%) were children while 40 (50.6%) and 12 (15.2%) were adults and elderly, respectively [Figure 1]. Sixty-one (77.2%) were males while 18 (22.8%) were females, giving a male:female ratio of 3.4:1. The right eye was affected in 57.5% ( $n = 46$ ) of cases as against 42.5% ( $n = 34$ ) for the left.

## Indications

Trauma was the single the most common indication for surgical eye removal followed by neoplasm, intractable intraocular infection, and staphyloma [Figure 2].

Children accounted for 33.8% ( $n = 27$ ) of eyes that were surgically removed. Among children, 22 (81.5%) were aged  $<5$  years. Orbito-ocular neoplasm (advanced retinoblastoma) accounted for 55.6% ( $n = 15$ ) of surgical eye removal in this age group; this was followed by trauma 6 (22.2%) and staphyloma 4 (14.8%). Trauma was the leading indication for surgical eye removal among adults with 22 (53.7%) affected eyes. Of the 12 eyes of elderly patients removed, trauma was the most common cause accounting for 58.3% [Figure 3].

The most common procedure carried out was enucleation which accounted for 55% of all procedures [Figure 4].

## DISCUSSION

The leading indications for destructive procedures in this study were severe ocular injuries in which globe preservation procedures were either not possible or considered unsafe, and neoplasm. The study also showed that males were 3 times more likely to have surgical eye removal than females. This may be because the male gender is associated to a significant extent with aggressive behavior and tend to engage in occupations that constitute a considerable risk to ocular safety.<sup>[8]</sup> The leading roles of trauma and neoplasm as indications for eye removal are however not unique to this study as similar trend have been reported in literature in Nigeria and other developing countries. Adeoye and

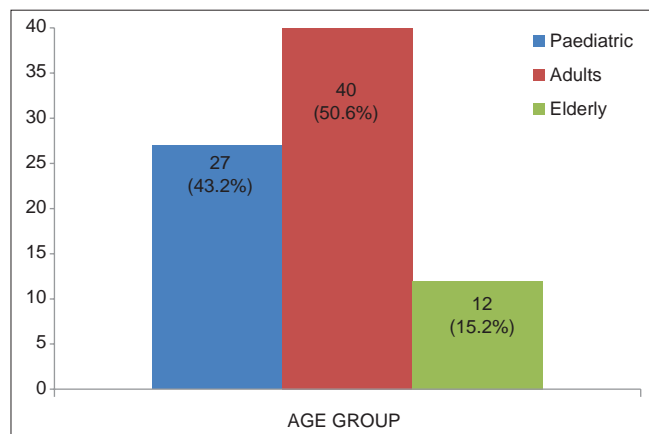


Figure 1: Age group distribution pattern

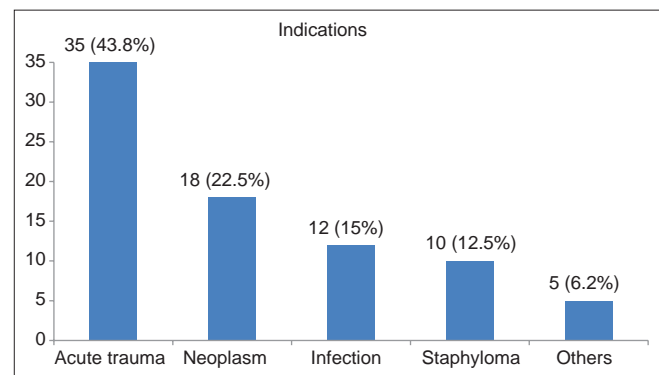


Figure 2: Profile of Indications

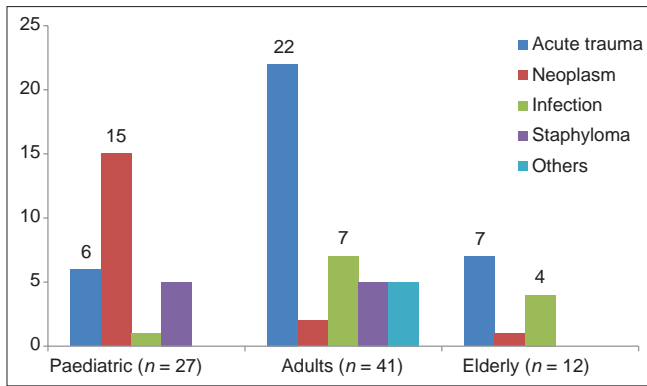


Figure 3: Aetiological pattern within age groups

Onakpoya in South Western Nigeria during a period of local inter-communal violent conflict reported removal of 94 eyes over a 10-year period with male:female ratio of 2.1:1 with trauma (43.4%) and orbito-ocular tumor (30.4%) identified as the leading indications for surgical eye removal.<sup>[9]</sup> Another 5-year study in Jos, North Central Nigeria reported that males were 3 times more likely to lose an eye than females and noted that trauma (45.6%) was the most common indication for removing the eye in adults.<sup>[10]</sup> The etiologic pattern in our study differs from the findings of a 10-year review in a rural hospital in South Eastern Nigeria where severe ocular infection and staphyloma took the lead.<sup>[11]</sup> This appear to reflect the inherent risks to eye health prevalent in such rural environment. Meanwhile, studies in the developed world have identified neoplasm and painful blind eye as the leading indications for surgical removal of the eyes.<sup>[5-7]</sup> Declining number of total eyes surgically removed per year was noted in a 60-year review of eye removal surgeries by Setlur *et al.*<sup>[6]</sup> The authors attributed this to improved medical and surgical treatment of eye conditions that lead to eye disease but also remarked that the absolute number of enucleations secondary to neoplasms has not decreased over time, despite an increase in globe-conserving treatments. Meanwhile, eye care providers in developing countries still experience myriad of challenges that often make eye removal inevitable.<sup>[5]</sup>

The leading indication for eye removal in this study was trauma among adults and elderly while neoplasm was the most common among children. The high incidence of trauma-related indications for eye removal is probably related to hazards of occupation as well as domestic and communal strife in some of the communities sub-served by the hospital during some years covered by this study. This is supported by the preponderance of the male gender in this study, corroborating similar report in several literature.<sup>[1,5,9,10,12]</sup> In addition, majority of patients were individuals within the working/productive age group.

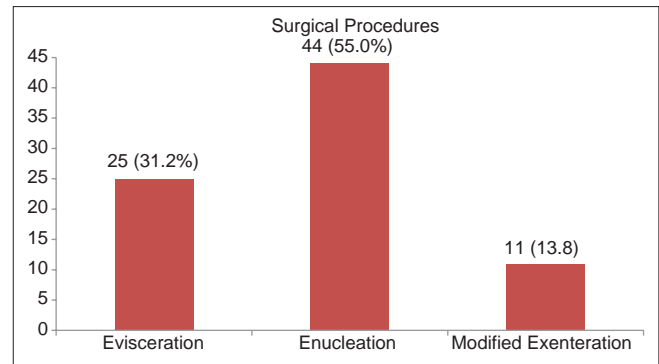


Figure 4: Pattern of surgical procedure

This study revealed that children who suffer the loss of an eye is a little over one-third of all eyes studied. The psychosocial implications associated with the loss of an eye in a child with the inherent and environmental lifetime risk of sight loss in the fellow eye cannot be overemphasized in these circumstances. The high incidence among such a vulnerable group is possibly a reflection of the lack of equipment and/or sub-specialty expertise to manage such cases adequately through sight- or globe-salvaging procedures. Furthermore, the high incidence of trauma and staphyloma among the cases reflects the potential harm prevalent in an average child's environment.

Among children <5 years, neoplasm, particularly retinoblastoma, was the commonest cause, consistent with reports in literature.<sup>[12-14]</sup> Typical of many developing countries, substantial delay before the first presentation and difficulty with funding treatment resulted in majority of children presenting with advanced stage disease, including fungating growth and metastasis.<sup>[15,16]</sup> Therefore, enucleation and modified exenteration in conjunction with chemoreduction, rather than globe-salvage procedures, were often times palliation for such advanced and/or extended intraocular tumors. Lack of capacity to offer sight-/globe-salvage intervention also contributed to the inevitability of surgical removal of eyes with early stage disease.<sup>[17]</sup> The late presentation among these patients and findings of extensive local infiltration on histologic evaluation mean that a lot of work needs to be done in educating people to identify early presentations of such conditions and report for prompt clinical assessment and early intervention.

There was no significant variation in the indications and pattern of globe excision in most urban settlements in developing countries, as most studies reported from tertiary eye care hospitals in large towns and cities showed that the most common indication was trauma and this contrast sharply with reports originating

from rural settings.<sup>[1,10-12]</sup> Education of the populace on hazards of ocular injuries and their poor outcomes, as well as avoidance of herbal medication, occupational protective measures and improved access to eye care, will significantly reduce globe excision from such causes.

Unlike many developed countries where the indications for destructive procedures are likely to be of nonpreventable neoplastic origin in adults and the elderly,<sup>[5]</sup> most of the causes of globe excision in this study are largely preventable particularly among working/productive age group and children. The pattern has largely remained the same over the last two decades in urban communities in West Africa. There is the need to improve on eye health education, ensure better access to eye care at all levels and encourage ophthalmologists to sub-specialize in relevant disciplines.

## CONCLUSION

This can be attributed to disparities in socioeconomic, environmental and cultural factors as well as level of eye health care development in the different societies.

## Financial support and sponsorship

Nil.

## Conflicts of interest

There are no conflicts of interest.

## REFERENCES

- Pandey PR. A profile of destructive surgery in Nepal Eye Hospital. Kathmandu Univ Med J (KUMJ) 2006;4:65-9.
- Noyes HD. The cornea. In: A Treatise on the Diseases of the Eye. New York: W. Wood; 1881.
- Sandford-Smith J. Evisceration, enucleation and exenteration. In: Eye Diseases in Hot Climates. London: JP Medical Ltd.; 2014. p. 307-15.
- Shah RD, Singa RM, Aakalu VK, Setabutr P. Evisceration and enucleation: A national survey of practice patterns in the United States. Ophthalmic Surg Lasers Imaging Retina 2012;43:425-30.
- Shapiro A, Monselise MB. Destructive ophthalmic procedures, a comparison between a developed and a developing country. Albrecht Von Graefes Arch Klin Exp Ophthalmol 1978;207:271-3.
- Setlur VJ, Parikh JG, Rao NA. Changing causes of enucleation over the past 60 years. Graefes Arch Clin Exp Ophthalmol 2010;248:593-7.
- Rasmussen ML, Prause JU, Johnson M, Kamper-Jørgensen F, Toft PB. Review of 345 eye amputations carried out in the period 1996-2003, at Rigshospitalet, Denmark. Acta Ophthalmol 2010;88:218-21.
- Nordberg E. Injuries as a public health problem in sub-Saharan Africa: Epidemiology and prospects for control. East Afr Med J 2000;77 12 Suppl: S1-43.
- Adeoye AO, Onakpoya OH. Indication for eye removal in Ile-Ife, Nigeria. Afr J Med Med Sci 2007;36:371-5.
- Mpyet C, Wade P, Ramyil A. Indications for surgical removal of the eye in adults: A five-year review. Niger J Med 2008;17:107-9.
- Okoye O, Chuka-Okosa CM, Magulike NO. Ten-year rural experience of surgical eye removal in a primary care center South-Eastern Nigeria. Rural Remote Health 2013;13:2303.
- Gyasi ME, Amoaku WM, Adjuk M. Causes and incidence of destructive eye procedures in North-Eastern Ghana. Ghana Med J 2009;43:122-6.
- Ntim-Amponsah CT. Ocular tumours and problems in management: A Ghanaian experience. East Afr Med J 1996;73:182-6.
- Mukhtar AU, Kagame K. Pathological study of retinoblastoma in Mbarara, Uganda. Cent Afr J Med 2000;46:13-6.
- Essuman V, Ntim-Amponsah CT, Akafo S, Renner L, Edusei L. Presentation of retinoblastoma at a paediatric eye clinic in Ghana. Ghana Med J 2010;44:10-5.
- Sahu S, Banavali SD, Pai SK, Nair CN, Kurkure PA, Motwani SA, et al. Retinoblastoma: Problems and perspectives from India. Pediatr Hematol Oncol 1998;15:501-8.
- Bekibele CO, Ayede AI, Asaolu OO, Brown BJ. Retinoblastoma: The challenges of management in Ibadan, Nigeria. J Pediatr Hematol Oncol 2009;31:552-5.