

## ORIGINAL ARTICLE

# Long-term Evaluation of Laser Retinopexy in Retinal Breaks: A Review and the Importance of Lifetime Follow-up

Gonen Baser, Murat Uyar, Aziz Serkan Topaloglu, Emine Seker Un, Sevim Yaman Yildirim, Sinan Bilgin

Department of Ophthalmology, Sifa University, Turkey

## ABSTRACT

**Purpose:** To evaluate the effects of laser retinopexy in retinal breaks and the recurrence cases. **Materials and Methods:** 45 eyes of 25 patients who underwent laser retinopexy in retinal breaks between the period of July 2009 and January 2013 are included. All the breaks and suspicious areas for possible breaks are treated with laser photocoagulation. The breaks were surrounded with three rows of laser spots. After the routine controls, the patients are called every 6 months and advised to come immediately to our clinic if new flashing or floaters occur. **Results:** The patients were followed-up for an average period of  $29.65 \pm 10.45$  months. New breaks were treated again and evaluated for the possible reasons. We found in three patients new breaks after an average period of  $27.33 \pm 2.03$  months. No specifications are observed in these subjects. **Conclusion:** Retinal breaks can occur even a long time after. It is not known why this process is progressing and new tears develop. For this reason, patients who underwent a laser therapy because of retinal breaks should followed-up for a lifetime. We advise that, asymptomatic patients who underwent laser retinopexy, should be examined every 6 months and every new complaint of flashing and big floaters should be carefully taken into consideration to prevent retinal detachments.

**Keywords:** Laser retinopexy, posterior vitreous detachment, retinal breaks

## INTRODUCTION

Retinal detachment is a serious and sight-treating disease. The only treatment is surgical and the results are not always successful. It develops on a base of retinal breaks. Therefore it is important to find the breaks and tears before a detachment develops. The main reason for retinal breaks is a posterior vitreous detachment (PVD). Posterior vitreous detachments are a frequent, age-related problem in the ophthalmology clinic. The clinical event is described as the separation of the vitreous cortex from the internal limiting

membrane due to its liquefaction.<sup>[1,2]</sup> Although generally it is not dangerous, it can be complicated by tractional retinal breaks and retinal detachment. The most common symptoms of PVD are floaters and flashing. Nonetheless, multiple floaters, retinal hemorrhage, bridging vessels and pigment cells in the anterior vitreous (Schaefer's sign) are found, which can be predictive for accompanying retinal breaks. Patients who are over the age of 45 with these complaints are very common in eye clinics. Because of its complications, it is of great importance for the clinician to take these complaints into consideration to prevent retinal detachments (RD).<sup>[2-8]</sup>

Symptomatic retinal breaks and lattice degeneration are visible lesions that are risk factors for later RD. Retinal detachments occur when fluid in the vitreous cavity passes through tears or holes in the retina and separates the retina from the underlying retinal pigment epithelium.<sup>[9]</sup> Creation of an adhesion surrounding retinal breaks and lattice degeneration,

### Access this article online

Quick Response Code	Website: <a href="http://www.nigerianjournalofophthalmology.com">www.nigerianjournalofophthalmology.com</a>
	DOI: ***

### Address for correspondence

Asst. Prof. Gonen Baser, Medical Faculty, Department of Ophthalmology, Izmir Sifa University 1429 Sok. No: 1/3 Ufuk Apt., Alsancak, Izmir, Turkey. E-mail: Gonen Baser: [basergonen@gmail.com](mailto:basergonen@gmail.com)

with laser photocoagulation or cryotherapy, has been recommended as an effective means of preventing RD. This therapy is of value in the management of retinal tears associated with the symptoms of flashes and floaters and persistent vitreous traction upon the retina in the region of the retinal break, because such symptomatic retinal tears are associated with a high rate of progression to retinal detachment. Retinal breaks, unassociated with acute symptoms and lattice degeneration, are significantly less likely to be the sites of retinal breaks that are responsible for later retinal detachment. Nevertheless, treatment of these problems is frequently recommended,<sup>[10]</sup> in spite of the fact that the effectiveness of this therapy is controversial.<sup>[11,12]</sup>

The early diagnosis of retinal breaks is very important. Thus, this dramatic disease can be prevented by laser photocoagulation before the onset of RD.<sup>[9]</sup> But after the treatment, new breaks can occur in the same, as well as the opposite eye. There is no evidence that lattice degeneration without holes requires treatment, and prophylactic therapy is of little value.<sup>[13,14]</sup> However, a study showed that prophylactic treatment of lattice degeneration in the phakic fellow eye of patients with retinal detachment reduces the risk of subsequent detachment from 5.1 to 1.8.<sup>[14,15]</sup> Our clinical experiences showed us that the timing of the onset of a new break is unknown.

This study was undertaken to evaluate the presence of retinal tears discovered on long-term follow-up examination. This information may be helpful for ophthalmologists when evaluating patients who underwent laser surgery for retinal tears. Every complaint of flashing and floaters, which are sometimes overlooked in overcrowded ophthalmology clinics, should be taken seriously by the physician because retinal tears can occur, even after a long period of time.

## MATERIALS AND METHODS

45 eyes of 25 patients who came to our clinic in the period of November 2009 and January 2013 with flashing and floating complaints and accompanying retinal breaks are taken into the study. The patients underwent a complete ocular examination with a careful retinal examination with a Goldmann 3 mirror lens. After the visual examination, the anterior segment was inspected and IOPs were measured. We treated all retinal breaks within 1 week and detected the lattice degeneration areas which we found risky for an upcoming break formation with laser photocoagulation. The breaks and lattice areas were encircled with three rows of laser spots.

The patients were called 2 weeks, 6 weeks and 3 months later for controls and if there was not any new break,

the patients were called for follow-ups for every 6 months. It has been advised to the patients that they should refer to us if they have new flashing or floaters. The follow-up period of the patients was between 16 and 55 months (av.  $29.65 \pm 10.45$ ). The study protocol adhered to the declaration of Helsinki. The local ethical committee has approved the study. Patients which had retinal breaks or lattice degeneration were taken into the study. The exclusion criteria's were as follows:

- History of a penetrating or blunt ocular trauma
- History of anterior or posterior uveitis
- History of intraocular surgery.

One patient had a retinal tear with hemorrhage. This patient was treated but could not be followed-up because of a hospitalization due to a congestive heart failure.

## RESULTS

The mean age of the patients was  $53.32 \pm 13.04$ . 14 were males (56%) and 11 were females (44%). We found in 45 eyes retinal tears, lattice degenerations with or without holes. 25 of them located in superior temporal (55.55%), 9 in the inferior temporal (20%), 5 in the inferior nasal (11.11%) and 6 in the superior nasal (13.33%) quadrant [Figure 1]. All were treated with laser photocoagulation in a spot size of 200-300  $\mu$  and energy of 200-300 mW. The spots were placed circumferentially on the tears in three rows. No complications occurred during or after the laser procedure.

In three of the cases, we detected new retinal breaks 25-28 months after the initial visit in the opposite eye. One of the patients underwent a retinal detachment surgery 1 year ago in another clinic. The tear that we treated was in the non-operated eye. Another patient underwent a laser retinopexy for the same eye that we treated because of a recurrent retinal break in another

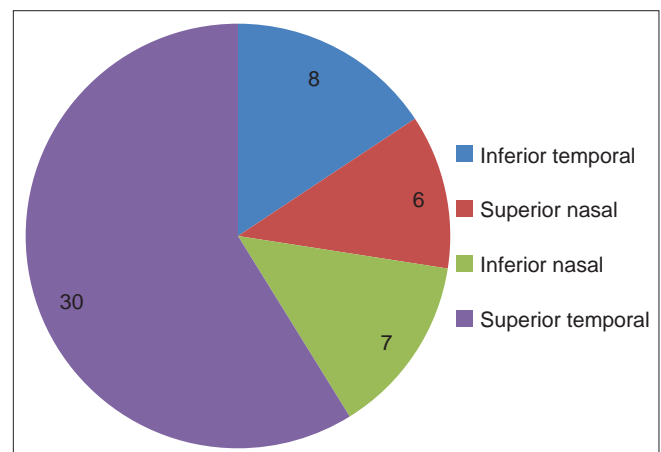


Figure 1: The distribution of the location of the retinal breaks

**Table 1: The specifications of these patients are summarized below**

Patient no	Age	Gender	First detection of tears	Follow-up period (months)	Time of new tears (months)	Refractive specifications	PVD
1	48	Male	2009	54	28	Moderate myopia and astigmatism	Incomplete
2	79	Male	2009	36	25	Moderate myopia (-3.00-6.00)	Complete
3	61	Male	2011	38	29	Light myopia (<1.00)	Complete

PVD: Posterior vitreous detachment

clinic. Two of them were moderate myopic. None of them had an untreated degenerating predisposing area. During the follow-ups, we took every complaint of flashing into consideration and examined every patient even his or her periodic control date has not come. We did not find any new breaks and still have most of these patients under control.

## DISCUSSION

Rhegmatogenous retinal detachments are a relatively frequent, serious and sight treating problem in the ophthalmology clinics. First when a detachment occurs, the only treatment is an expensive and difficult surgery, which is generally performed only by vitreoretinal surgeons. The main aim to prevent this disease is to detect symptomatic or non-symptomatic retinal breaks and holes and treat them before a RD onset.

Retinal tears and holes are basically formed in degenerative areas of the retina periphery. Degenerative lesions of the peripheral retina are sometimes present from teenage years onwards and increase with the age. These abnormalities are frequent, some of them being benign while others predispose to retinal tears and detachment. In the latter case, the lesions are rhegmatogenous and may justify prophylactic treatment by laser photocoagulation. The holes and tears observed in 2% of the population consist of round atrophic holes, "horseshoe" tears, oral dialysis and giant tears.<sup>[3]</sup>

Posterior vitreous detachment (PVD) plays an important role by converting degenerative areas to a retinal hole and RD. The main symptoms are flashing and floaters which are accompanied by retinal hemorrhages, bridging vessels and pigment cells in the anterior vitreous.<sup>[1-8]</sup> The diagnosis can be established by the "Weiss ring" found, the clinical examination and by the B-Scan USG.<sup>[9,16]</sup> The posterior vitreous cortex exerts dynamic traction over areas of persistent vitreoretinal adherence, which would contribute to the development of macular holes and retinal tears. Retinal detachments occur when fluid in the vitreous cavity passes through tears or holes in the retina and separates the retina from the underlying retinal pigment epithelium.<sup>[9,16,17]</sup>

The golden standard of the diagnosis of retinal tears is the examination of the peripheral retina with a

Goldmann 3 mirror lens and indirect ophthalmoscope. Because of its dramatic consequences, it is of high importance to do this in patients, which come to the clinic with symptoms of flashing and floaters. But this is a time-consuming examination, demands experience and manpower. Therefore, these symptoms could be categorized in a selective manner as described by Schweitzer *et al.*<sup>[1]</sup> or Overdam *et al.*<sup>[5,6]</sup>

The main treatment of retinal tears and holes without a RD is argon laser photocoagulation, where the tears are surrounded by laser spots.<sup>[7,10]</sup> In general, the tears are surrounded by two or more rows of laser spots. The main problem here is, a new tear can develop in the treated eye or in the fellow eye.

The incidence of retinal tears in acute symptomatic PVD varies from 10% to 14%.<sup>[18,19]</sup> Approximately, 30-50% of symptomatic retinal breaks with persistent vitreoretinal traction will cause a clinical RD if left untreated.<sup>[20]</sup> There is an increased risk in incomplete PVD's.<sup>[16]</sup> The highest risk period for a developing break after an acute PVD is the first 2-6 weeks.<sup>[5,6]</sup> But they can also develop in a much longer period.<sup>[16,17]</sup> The presence of a vitreous hemorrhage and numerous floaters looks to be a sign of new breaks.<sup>[7,20]</sup>

When we reviewed our cases, no retinal detachment developed in any case. Even so, a new tear or a RD can develop years after. For this reason, the long period for these patients is of high importance. In our opinion, as mentioned before, repeating or persistent flashing and numerous floaters are the most important signs for a possible break. The patient information in the case and every history of these complaints should be carefully taken into consideration. If examined and treated under great care, the laser retinopexy is a rapid and very effective method to prevent RD.<sup>[10,21-23]</sup>

There are some limitations in our study. Samples in which new breaks were present are not high. This makes it difficult to give a detailed determination of the recurrent breaks. We found no specifications or obvious difference between the other samples. The major result of our study is that new breaks can occur, even after a long time in new locations. Although it has been reported in some studies that in acute PVDs, the patients should be asked for re-examination, only if

they experience an increase in the number of floaters.<sup>[5]</sup> We believe that each patient, who had a retinal break diagnosis and with an acute PVD or not, should be followed-up every 6 months for his lifetime and alarmed to be examined as soon as possible when new flashings and floaters appear.

## REFERENCES

1. Schweitzer K, Eneh A, Hurst J, Bona M, Rahim K, Sharma S. Predicting retinal tears in posterior vitreous detachment. *Can J Ophthalmol* 2011;46:481-5.
2. El Sanhoury AA, Foster RE, Petersen MR, Hutchins RK, Miller DM, Evans TM, *et al.* Retinal tears after vitreous detachment and vitreous hemorrhage in patients on systemic anticoagulants. *Eye* 2011;25:1016-9.
3. Conart JB, Baron D, Berrod JP. Degenerative lesions of the peripheral retina. *J Fr Ophthalmol* 2014;37:73-80.
4. Folk JC, Ma C, Blodi CF, Han DP. Occlusion of bridging or avulsed retinal vessels by repeated photocoagulation. *Ophthalmology* 1987;94:1610-3.
5. van Overdam KA, Bettink-Remeijer MW, Klaver CC, Mulder PG, Moll AC, van Meurs JC. Symptoms and findings predictive for the development of new retinal breaks. *Arch Ophthalmol* 2005;123:479-84.
6. Van Overdam KA, Bettin JC, Bettink-Remeijer MW, Mulder PG, van Meurs JC. Symptoms predictive for the later development of retinal breaks. *Arch Ophthalmol* 2001;119:1483-6.
7. Khan AA, Gupta A, Bennett H. Risk stratifying retinal breaks. *Can J Ophthalmol* 2013;48:546-8.
8. Coffee RE, Westfall AC, Davis GH, Mieler WF, Holz ER. Symptomatic posterior vitreous detachment and the incidence of delayed retinal breaks: Case series and meta-analysis. *Am J Ophthalmol* 2007;144:409-13.
9. Tanner V, Harle D, Tan J, Foote B, Williamson TH, Chignell AH. Acute posterior vitreous detachment: The predictive value of vitreous pigment and symptomatology. *Br J Ophthalmol* 2000;84:1264-8.
10. Kovacevic D, Loncarek K. Long-term results of argon laser retinal photocoagulation for retinal ruptures. *Acta Med Croatica* 2006;60:149-52.
11. Blindbaek S, Grauslund J. Prophylactic treatment of retinal breaks-A systematic review. *Acta Ophthalmol* 2014. [In press].
12. Wilkinson CP. Interventions for asymptomatic retinal breaks and lattice degeneration for preventing retinal detachment. *Cochrane Database Syst Rev* 2012;3:CD00317.
13. Byer N. Long-term natural history of lattice degeneration of the retina. *Ophthalmology* 1989;96:1396-402.
14. Folk JC, Bennett SR, Klugman MR, Arrindell EL, Boldt HC. Prophylactic treatment to the fellow eye of patients with phakic lattice retinal detachment: Analysis of failures and risks of treatment. *Retina* 1990;10:165-9.
15. Optometric Clinical Practice Guideline. Care of the Patient with Retinal Detachment And Related Peripheral Vitreoretinal Disease. American Optometry Association, 2010.
16. Carrero JL, Perez-Flores I, Cid- Galano M, Fernandez-Fernandez M, Raposo FH, Nunez RV, *et al.* B-Scan Ultrasonography to screen for retinal tears in acute symptomatic age-related posterior vitreous detachment. *Ophthalmology* 2009;116:94-9.
17. Carrero JL. Incomplete posterior vitreous detachment: Prevalence and clinical relevance. *Am J Ophthalmol* 2012;153:497-503.
18. Byer NE. Natural history of posterior vitreous detachment with early management as the premier line of defense against retinal detachment. *Ophthalmology* 1994;101:1503-13.
19. Sharma S, Walker R, Brown G, Cruess A. The importance of qualitative vitreous examination in patients with acute posterior vitreous detachment. *Arch Ophthalmol* 1999;117:343-6.
20. Davis MD. The natural history of retinal breaks without detachment. *Trans Am Ophthalmol Soc* 1973;71:343-72.
21. Falk JC, Sneed SR, Folberg R, Coona P, Pulido JS. Early retinal adhesion from laser photocoagulation. *Ophthalmology* 1989;96:1523-5.
22. Menchini U, Trabucchi G, Brancato R, Capellini A. Can the diod laser (810 nm) effectively produce chorioretinal adhesion. *Retina* 1992;12:580-6.
23. Hikichi T. Time course of posterior vitreous detachment in the second eye. *Curr Opin Ophthalmol* 2007;18:224-7.

How to cite this article:\*\*\*

Source of Support: Nil, Conflict of Interest: None declared