

Original Article

Retrospective Morphometric Analysis of the Infraorbital Foramen with Cone Beam Computed Tomography

S Dağistan, Ö Miloğlu, O Altun¹, EK Umar²

Department of Oral and Maxillofacial Radiology, Faculty of Dentistry, Ataturk University, Erzurum,

¹Department of Oral and Maxillofacial Radiology, Faculty of Dentistry, İnönü University, Malatya,

²Department of Oral and Maxillofacial Radiology, Faculty of Dentistry, Yildirim Beyazit University, Ankara, Turkey

Date of Acceptance:
06-Sep-2016

INTRODUCTION

Infraorbital nerve is a branch of the maxillary nerve in the second portion of the trigeminal nerve. After it passes through foramen rotundum, maxillary nerve enters into the pterygopalatine fossa and from there it is oriented to the posterior teeth by giving its palatin and nasal branches. Then, it enters into the orbita from inferior orbital fissure and it is referred as infraorbital nerve. Infraorbital nerve passes through infraorbital sulcus and infraorbital canal and extended to the skull via the infraorbital foramen (IOF).^[1] Infraorbital nerve block is used in regional anesthesia technique during the oral and dental surgery and also in nasal surgery to ensure the intraoperative and postoperative analgesia.^[2] Infraorbital nerve injuries

ABSTRACT

Objective: The aim of our study is to examine the morphometric characteristics of the infraorbital foramen (IOF) and its anatomic localization by using cone-beam computerized tomography (CBCT). **Materials and Methods:** In our study, the anatomic characteristics of the IOF were identified by studying retrospectively the CBCT images of one hundred twenty-five (125) patients. These characteristics were assessed statistically in terms of age, gender, and right-left side. **Results:** In our study, 42% of them had IOF in circular form and 58% in oval form. Of them 66.90% of those in oval form were in oblique direction, 28.30% of them were in vertical direction, and 4.80% of them were in horizontal direction. The mean vertical diameter of the IOF was found as 3.71 ± 0.61 mm and its mean horizontal diameter was found as 3.17 ± 0.56 mm. The mean distance of IOF to midline were measured as 25.10 ± 2.17 mm, distance to upper edge of the orbita was measured as 41.91 ± 2.77 mm, distance to infraorbital edge was measured as 5.63 ± 1.77 mm, distance to the lateral nasal wall was measured as 9.32 ± 2.68 mm, distance to spina nasalis anterior was measured as 17.97 ± 3.99 mm, thickness of the soft tissue on the foramen was measured as 11.52 ± 2.40 mm, and distance between the right and the left IOF was measured as 50.20 ± 3.90 mm. Accessory foramen was found in 56.60% ratio. **Conclusion:** This study reveals that CBCT may guide for local anesthesia applications and for other invasive procedures in order to prevent the damage of the neurovascular structures during maxillofacial surgery by identifying the distances of anatomic points such as IOF having surgically importance.

KEYWORDS: Cone beam computed tomography, infraorbital foramen

might occur in the anterior and superior walls during the surgical treatments such as rhinoplasty, Caldwell-Luc surgical procedures, tumor surgery, orbita basis reduction (blow-out), malar region fractures, and Le Fort type-I osteotomy.^[3] Therefore, knowing the localization of IOF and its distances to the anatomic formations is extremely important for any surgical intervention performed in this region, which increases the chance of success of the regional block.^[4]

Address for correspondence: Dr. Ö Miloğlu, Department of Oral and Dentomaxillofacial Radiology, Faculty of Dentistry, Ataturk University, Erzurum, Turkey.
E-mail: omiloglu@hotmail.com

This is an open access article distributed under the terms of the Creative Commons Attribution-NonCommercial-ShareAlike 3.0 License, which allows others to remix, tweak, and build upon the work non-commercially, as long as the author is credited and the new creations are licensed under the identical terms.

For reprints contact: reprints@medknow.com

How to cite this article: Dağistan S, Miloğlu Ö, Altun O, Umar EK. Retrospective morphometric analysis of the infraorbital foramen with cone beam computed tomography. Niger J Clin Pract 2017;20:1053-64.

Access this article online	
Quick Response Code:	Website: www.njcponline.com
	DOI: 10.4103/1119-3077.217247

Cone-beam computerized tomography (CBCT) is a low-dose section technique for imaging the bone structures in the head and neck region.^[5] CBCT has a characteristic of diagnostic instrument which is noninvasive for dental applications. There are several studies demonstrating that linear and angular measurements done with CBCT provides precise and correct results for studying the maxillofacial region and the measurements of this region.^[6-9]

The aim of this study is the assessment of the anatomic localization of the IOF by using CBCT.

PATIENTS AND METHODS

In our study, the CBCT data were collected in the convenient position during the assessment of the patients referred to the Department of Oral and Maxillofacial Radiology of the Faculty of Dentistry of İnönü University between 2013 and 2014 before the dental implant, assessment of the impacted tooth surgery, that of orthognathic surgery and that of paranasal sinus, planning of orthodontics were retrospectively studied. The patients who were less than 18 years old, those having history of trauma in head and neck region, the patients having syndrome or congenital anomalies with signs in the head and neck region were not included. The patients who have pathologic formation and fracture in the relevant region were excluded from the study. The study was conducted in 125 patients, 65 females and 60 males, whose ages varied between 18 and 75 years. CBCT of the patients who were included in the study were done by means of the CBCT instrument (NewTom 5G, Quantitative Radiology, Verona, Italy) located in the Department of Oral and Maxillofacial Radiology of the Faculty of Dentistry of İnönü University.

IMAGING PROCEDURE

The patient was positioned in supine position in a fashion that the hard palate will be parallel to the gantry and perpendicular to ground in an instrument with a constant gantry angle which is perpendicular to ground. The study was conducted by using axial sections acquired in this position. In this instrument, the study was performed in 16 × 18-cm FOV area with cone beam technique in 110 kVp and with maximum 20 mA as standard. Guidance images were obtained at the initial stage of the image acquisition process. The instrument had also a system (AEC, automatic exposure control system) which makes automatic dose setting with respect to the anatomic density of the head. Image acquisition was completed by ensuring that the patient to stay without moving until scanning was finished. Following scanning, the images were assessed with the reconstructions on the

axial sections by using NNT software by after obtained the sections in other planes.

EVALUATED PARAMETERS IN THE ANALYSIS

Evaluations done for the localization of infraorbital foramen

The shape of infraorbital foramen and its direction with respect to the midline

Foramens and their images in coronal section were assessed and classified as oval or circle, and those in semicircular shape were included in circle class. In addition, IOFs with oval shape were classified as oblique, vertical, and horizontal after studied its direction with respect to midline.

Diameter of Infraorbital Foramen

Vertical diameter: Lower-upper diameter of IOF in sagittal section was measured [Figure 1].

Horizontal diameter: Medio-lateral diameter of IOF was measured in coronal section [Figure 1].

Accessory foramen

The incidence of accessory IOF was studied from axial sections [Figure 2].

Distances of infraorbital foramen to several anatomic points

Distance to midline

In coronal section, the distance between the midline in which maxillar bones form joint and IOF was measured [Figure 3].

Distance of the orbita to its upper edge (supraorbital edge/margin) (SOM)

In coronal section, the distance between the IOF and the upper edge of the orbita was measured [Figure 3].

Distance to infraorbital edge (margin) (IOM)

In coronal section, the distance between the IOF and the lower edge of the orbita was measured [Figure 3].

Distance to lateral nasal wall (LNW)

In coronal section, the distance between IOF and the lateral nasal wall was measured [Figure 3].

Distance to spina nasalis anterior (ANS)

Cephalometric image was formed by taking sections in complete thickness being perpendicular to MPR image and the distance between IOF and spina nasalis anterior was measured in this section [Figure 4].

Soft tissue thickness

Soft tissue thickness on the IOF was measured in sagittal section [Figure 5].

The distance between two infraorbital sections was measured in coronal section [Figure 6].

REPRODUCIBILITY

Whole of the parameters were evaluated by a research assistant (Fourth author of the article: E.K.U.) doing doctorate in the Department of Oral Diagnosis and Radiology. To ensure diagnostic reproducibility of the intraobserver reliability of the investigator, 10% of the evaluated images were selected randomly and evaluated by the same researcher twice for 6 weeks. Intra-examiner reproducibility was found to be 100%. In addition, the cases in which the researcher had problems in the evaluation were consulted by a second researcher (Third author of the article: O. A.). The cases in which consensus was ensured were included in the study and those were not were excluded ($n = 1$).

Statistical analysis

In the evaluation of the study data, SPSS 17.0 software was used. Arithmetic mean (\bar{x}) \pm standard deviation (SD) was used in the definition of the quantitative variables. It was detected that the data of quantitative variables indicate normal distribution by means of Shapiro-Wilk normality test ($P > 0.05$). In the assessment of the variables in terms of gender and side, independent sample *t*-test was used and, in assessment of age groups, one-way variance analysis test was used in the dependent groups. The evaluation of the shape of the IOF in terms of genders was done by means of Pearson Chi squared test. The level of significance in statistical analysis was taken as $P < 0.05$.

RESULTS

In our study, CBCT images of 125 patients whose ages varied between 20 and 72 (mean age: 43.1) were studied.

Shape of IOF: In our study, 42% of IOFs were found in circular shape and 58% of them were found in oval shape; 66.90% of those in oval shape were in oblique direction, 28.30% of them were in vertical direction, and 4.80% of them were in horizontal direction. IOFs in circular shape were found commonly in the age range of 30-39 and those in oval shape were found commonly in the age range of 20-29. Either circle- or oval-shaped IOF were found more in females compared to males for both sides. Apart from this difference there is no statistically significant difference ($P > 0.05$) [Tables 1 and 2].

Diameter of IOF: The mean vertical diameter of IOF was found as 3.71 ± 0.61 mm and the mean horizontal diameter of IOF was found as 3.17 ± 0.56 mm. Either the vertical diameter of IOF or the horizontal diameter of IOF was found greater in the age range between 40 and 49 years. However, when the diameter of IOF was assessed with respect to age groups,

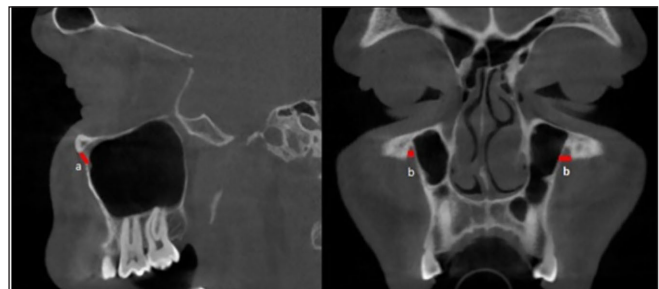


Figure 1: The diameter of infraorbital foramen: (a) sagittal section, vertical diameter; (b) coronal section, horizontal diameter

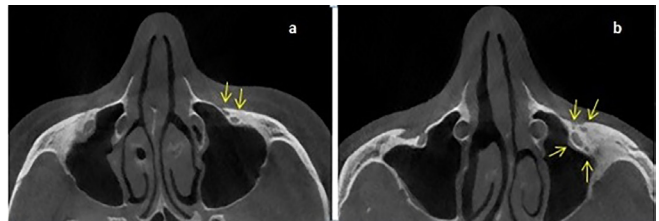


Figure 2: (a) One (1) accessory foramen, (b) Three (3) accessory foramen

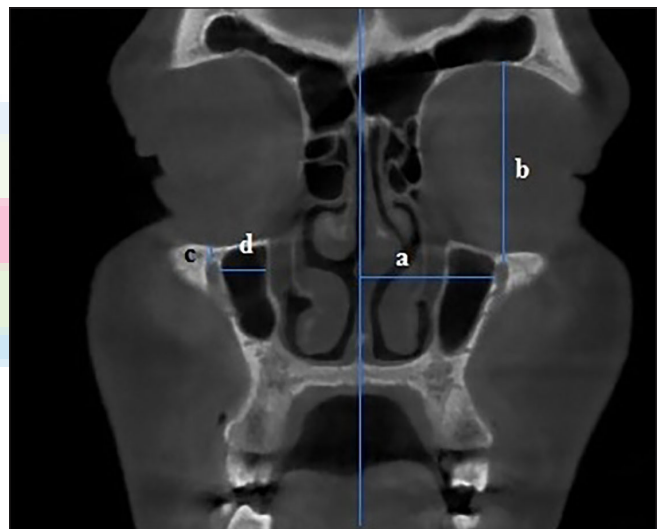


Figure 3: The distances of infraorbital foramen to several anatomic points (a) to midline, (b) to infraorbital edge, (c) to infraorbital margin and (d) to lateral nasal wall

no statistically significant difference was found ($P > 0.05$). When the distribution of the diameter of IOF was studied with respect to gender, no statistically significant difference was found between males and females for either vertical diameter or horizontal diameter ($P < 0.05$). The diameter of IOF is greater and more considerable in males [Tables 3,4 and 7].

The incidence of accessory foramen: The presence of a second foramen has been detected in 56.40%-ratio. The majority of these (53.20%) has two foramina. Only in one patient IOF formation with four foramina (0.40%) was detected. The distribution of the accessory foramen with respect to either age groups or gender demonstrates similarities [Tables 5 and 6].

Table 1: The distribution of infraorbital foramen shape according to the age groups

			20-29	30-39	40-49	50-59	>60	Total
Circular	R	n	12	12	11	7	9	51
		%	42.90	44.40	42.30	31.80	40.90	40.80
	L	n	11	15	13	7	8	54
		%	39.30	5.60	50.00	31.80	36.40	43.20
Oval	R	n	16	15	15	15	13	74
		%	57.10	5.60	57.70	68.20	59.10	59.20
	L	n	17	12	13	15	14	71
		%	60.70	4.40	00	8.20	63.60	56.80
Total	R	n	28	26	27	22	22	125
		%	100	100	100	100	100	100
	L	n	28	26	27	22	22	125
		%	100	100	100	100	100	100

Table 2: The distribution of infraorbital foramen shape according to the sex

		R			L			Total
		Female	Male	Total	Female	Male	Total	
Circular	n	27	24	51	28	26	54	105
	%	41.50	40.00	40.80	43.10	43.30	43.20	42.00
Oval	n	38	36	74	37	34	71	145
	%	58.50	60.00	59.20	56.90	56.70	56.80	58.00
Total	n	65	60	125	65	60	125	250
	%	100	100	100	100	100	100	100

$p = 0.861$ $p = 0.977$

Table 3: The distribution of infraorbital foramen diameter according to the ages

		20-29	30-39	40-49	50-59	>60	p
		x ± SD	x ± SD	x ± SD	x ± SD	x ± SD	
N		28	27	26	22	22	
Vertical (mm)	R	3.50 ± 0.49	3.71 ± 0.67	3.83 ± 0.54	3.64 ± 0.62	3.84 ± 0.65	0.23
	L	3.64 ± 0.53	3.67 ± 0.73	3.74 ± 0.64	3.61 ± 0.62	4.00 ± 0.58	0.242
Horizontal (mm)	R	3.26 ± 0.71	3.07 ± 0.67	3.39 ± 0.42	3.01 ± 0.46	3.12 ± 0.62	0.168
	L	3.15 ± 0.54	3.05 ± 0.55	3.23 ± 0.56	3.21 ± 0.46	2.11 ± 0.56	0.579

Table 4: The distribution of infraorbital foramen diameter according to the sex

Sex	Female	Male	Total	p	
	x ± SD	x ± SD	x ± SD		
N	65	60	125		
Vertical (mm)	R	3.54 ± 0.56	3.87 ± 0.60	3.70 ± 0.60	0.001
	L	3.55 ± 0.60	3.92 ± 0.59	3.73 ± 0.62	0.003
Horizontal (mm)	R	3.03 ± 0.56	3.34 ± 0.60	3.17 ± 0.60	0.001
	L	2.95 ± 0.50	3.40 ± 0.46	3.16 ± 0.53	0.001

The mean distances of the IOF to anatomic points: The mean distance of IOF to midline were measured as 25.10 ± 2.17 mm, mean distance to upper edge of the orbita was measured as 41.91 ± 2.77 mm, mean distance to infraorbital edge was measured as 5.63 ± 1.77 mm, mean distance to the lateral nasal wall was measured as 9.32 ± 2.68 mm, mean distance to spina nasalis

anterior was measured as 17.97 ± 3.99 mm, and mean thickness of the soft tissue on the foramen was measured as 11.52 ± 2.40 mm. When the distances of the IOF are assessed, there is no statistically significant difference between female and male in all age groups ($P > 0.05$). When the right and left side were compared statistically significant difference was seen in the distance of

Table 5: The distribution of accessory foreman incidence according to sex

		R			L			Total
		Female	Male	Total	Female	Male	Total	
Single	N	31	23	54	28	27	55	109
	%	47.70	38.30	43.20	43.10	45.00	4.00	3.60
2 for.	N	33	36	69	34	30	64	133
	%	50.80	60.00	55.20	52.30	50.00	1.20	53.20
3 for.	N	1	1	2	3	2	5	7
	%	1.50	1.70	1.60	4.60	3.30	4.00	2.80
4 for.	N	0	0	0	0	1	1	1
	%	0.00	0.00	0.00	0.00	1.70	0.80	0.40
Total	N	65	60	125	65	60	125	250
	%	100	100	100	100	100	100	100

Table 6: The distribution of accessory foreman incidence according to age groups

			20-29	30-39	40-49	50-59	>60 üstü	Total
Single for.	R	N	15	12	8	10	9	54
		%	53.60	44.40	30.80	45.50	40.90	43.20
	L	N	12	14	9	11	9	55
		%	42.90	1.90	34.60	50.00	40.90	44.00
2 for.	R	N	12	15	18	11	13	69
		%	42.80	55.60	69.20	50.00	59.10	55.20
	L	N	14	12	15	10	13	64
		%	50.00	44.40	57.70	45.45	59.10	51.20
3 for.	R	N	1	0	0	1	0	2
		%	3.60	0.00	0.00	4.50	0.00	1.60
	L	N	2	1	1	1	0	5
		%	7.10	3.70	3.85	4.55	0.00	4.00
4 for.	R	N	0	0	0	0	0	0
		%	0.00	0.00	0.00	0.00	0.00	0.00
	L	N	0	0	1	0	0	1
		%	0.00	0.00	3.85	0.00	0.00	0.80
Total	R	N	28	27	26	22	22	125
		%	100	100	100	100	100	100
	L	N	28	27	26	22	22	125
		%	100	100	100	100	100	100

Table 7: The average of the measurements without laterality

	N	Minimum	Maximum	x ± SD
Vertical (mm)	250	2,10	5,20	3.71 ± 0.61
Horizontal (mm)	250	1,80	5,00	3.17 ± 0.56
Midline (mm)	250	19,80	30,80	25.10 ± 2.17
SOM (mm)	250	35,10	52,00	41.91 ± 2.77
IOM (mm)	250	2,00	11,50	5.63 ± 1.77
LNW (mm)	250	3,60	21,30	9.32 ± 2.68
ANS (mm)	250	8,30	42,40	17.97 ± 3.99
Soft tissue (mm)	250	4,60	18,50	11.52 ± 2.40
IOF-IOF (mm)	125	40,20	60,10	50.20 ± 3.90

IOF to lateral nasal wall (LNW) ($P < 0.05$). In other measurements, no significant difference was seen between right and left side ($P > 0.05$) [Tables 7-10].

Distance between two IOF: The mean distance between the right and the IOF was measured as 50.20 ± 3.90 mm. There is no statistically significant difference

Table 8: The evaluation of the measurements in terms of laterality

		N	Minimum	Maximum	x ± SD	p
Vertical (mm)	R	125	2.3	5.2	3.70 ± 0.60	0.688
	L	125	2.1	5.1	3.73 ± 0.63	
Horizontal (mm)	R	125	1.8	5	3.17 ± 0.60	0.858
	L	125	1.8	4.8	3.16 ± 0.53	
Midline (mm)	R	125	20.2	30.8	25.14 ± 2.21	0.760
	L	125	19.8	30.5	25.06 ± 2.13	
SOM (mm)	R	125	35.8	48	41.98 ± 2.75	0.704
	L	125	35.1	52	41.84 ± 2.80	
IOM (mm)	R	125	2.00	10.50	5.64 ± 1.78	0.954
	L	125	2.00	11.50	5.63 ± 1.76	
LNW (mm)	R	125	4.3	21.3	8.95 ± 2.54	0.038
	L	125	3.6	15.3	9.01 ± 2.46	
ANS (mm)	R	125	8.3	28.2	17.95 ± 3.66	0.927
	L	124	9.8	42.4	17.99 ± 4.32	
Soft tissue (mm)	R	125	4.6	18.5	11.50 ± 2.48	0.915
	L	125	7.2	17.5	11.53 ± 2.34	

Table 9: The distances of infraorbital foramen to several anatomic points according to age groups

Age		20-29	30-39	40-49	50-59	60 üstü	p
		x ± SD	x ± SD	x ± SD	x ± SD	x ± SD	
N		28	27	26	22	22	125
Midline (mm)	R	24.61 ± 1.98	25.68 ± 2.46	25.08 ± 2.01	24.03 ± 2.18	25.98 ± 2.24	0.062
	L	24.87 ± 2.19	25.38 ± 2.56	25.03 ± 2.13	24.69 ± 1.58	25.30 ± 2.06	0.777
SOM (mm)	R	42.30 ± 2.43	41.59 ± 2.24	42.06 ± 2.87	41.67 ± 2.75	42.15 ± 2.67	0.809
	L	42.37 ± 2.50	41.95 ± 2.82	40.86 ± 3.75	41.67 ± 3.75	42.37 ± 2.42	0.279
IOM (mm)	R	5.67 ± 1.92	5.43 ± 1.29	5.50 ± 1.93	6.05 ± 2.00	5.62 ± 1.81	0.974
	L	5.62 ± 1.71	5.48 ± 1.56	5.39 ± 1.92	6.43 ± 2.10	5.30 ± 1.29	0.201
LNW (mm)	R	9.71 ± 2.19	9.78 ± 2.71	8.79 ± 2.41	9.91 ± 3.39	10.45 ± 3.12	0.330
	L	10.10 ± 2.80	9.23 ± 2.93	8.20 ± 2.06	8.01 ± 2.19	9.00 ± 2.05	0.125
ANS (mm)	R	18.64 ± 4.17	17.05 ± 3.32	17.65 ± 3.33	18.29 ± 2.95	18.19 ± 4.36	0.553
	L	18.62 ± 4.60	17.25 ± 3.07	17.90 ± 3.32	18.41 ± 6.04	17.82 ± 4.45	0.806
Soft tissue (mm)	R	11.28 ± 1.97	11.89 ± 2.17	11.01 ± 2.70	11.15 ± 2.36	12.22 ± 3.17	0.378
	L	11.31 ± 2.04	11.75 ± 2.24	11.15 ± 2.14	11.02 ± 2.51	12.5 ± 2.76	0.201

Table 10: The distances of infraorbital foramen to several anatomic points according to sex

Sex		Female	Male	Total	p
		x ± SD	x ± SD	x ± SD	
N		65	60	125	
Midline (mm)	R	25.00 ± 2.11	25.30 ± 2.32	25.14 ± 2.21	0.463
	L	24.83 ± 2.08	25.30 ± 2.18	25.06 ± 2.13	0.217
SOM (mm)	R	41.46 ± 2.63	42.55 ± 2.80	41.98 ± 2.75	0.082
	L	41.50 ± 2.76	42.23 ± 2.81	41.84 ± 2.80	0.141
IOM (mm)	R	5.87 ± 1.78	5.40 ± 1.77	5.64 ± 1.78	0.130
	L	5.88 ± 1.84	5.34 ± 1.62	5.63 ± 1.76	0.086
LND (mm)	R	9.77 ± 2.22	9.62 ± 3.27	9.70 ± 2.76	0.772
	L	9.11 ± 2.60	8.78 ± 2.50	8.95 ± 2.54	0.475
ANS (mm)	R	17.37 ± 3.87	18.58 ± 3.23	17.95 ± 3.66	0.065
	L	17.29 ± 3.73	18.78 ± 4.79	17.99 ± 4.32	0.056
Soft tissue (mm)	R	11.48 ± 2.45	11.52 ± 2.52	11.50 ± 2.48	0.929
	L	11.57 ± 2.47	11.50 ± 2.21	11.53 ± 2.34	0.872

Table 11: The distance between two infraorbital foramen according to age groups

Age	20-29	30-39	40-49	50-59	60	p
	x ± SD	x ± SD	x ± SD	x ± SD	x ± SD	
N	28	27	26	22	22	
IOF-IOF (mm)	49.48 ± 3.76	51.06 ± 4.65	50.10 ± 3.67	49.08 ± 3.18	51.27 ± 3.82	0.218

Table 12: The distance between two infraorbital foramen according to sex

Sex	Female	Male	Total	p
	x ± SD	x ± SD	x ± SD	
N	65	60	125	
IOF-IOF (mm)	49.83 ± 3.73	50.59 ± 4.06	50.20 ± 3.90	0.276

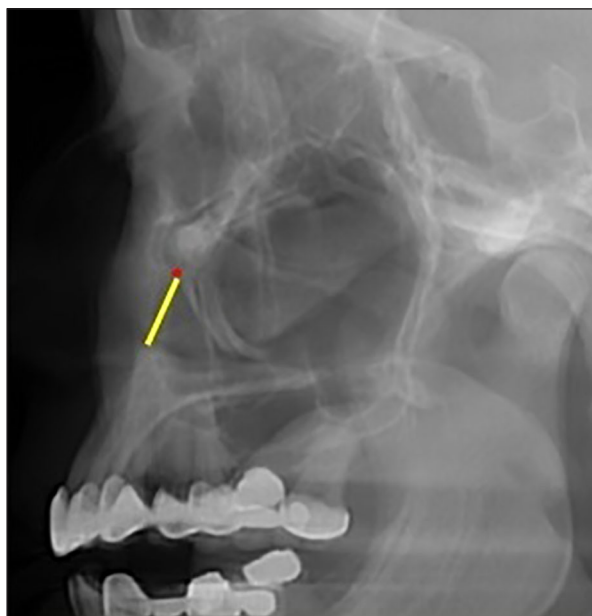


Figure 4: The distance between the infraorbital foramen and spina nasalis anterior in cephalometric section

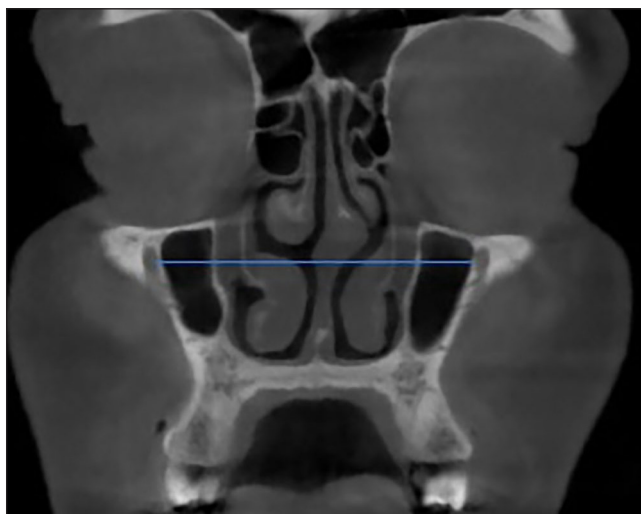


Figure 6: The distance between two infraorbital foramen

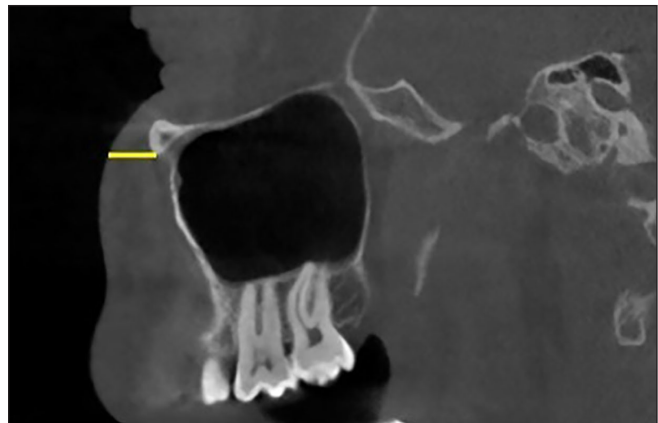


Figure 5: Soft tissue thickness

between the age groups and the genders in terms of the distance between the right and left IOF ($P > 0.005$) [Tables 11 and 12].

DISCUSSION

During the surgical procedures in the facial region, the importance of the anatomical characteristics of the foramens in the face is being increased. Knowing the localization of IOF is very useful for either medical dentists or surgeons of head and neck region for diagnosis and surgical procedures.^[10] The morphometry of the IOF plays an important role during the application of the regional anesthesia techniques of the infraorbital nerve.^[11] For the complete blockade, knowing the localization of the IOF and the direction of the infraorbital canal is very important.^[12] The content of the IOF may be damaged during the surgical procedures and as a result of this paresthesia or anesthesia may occur.^[13] The localization of IOF determines the direction of the acupuncture point used in the treatment of the trigeminal neuralgia.^[14] The information related with the dimensions and the symmetries of the foramens located in the facial region gain increasingly importance with the developments in the radiologic techniques such as magnetic resonance imaging (MRI) and computerized tomography (CT). These methods facilitate the difficult diagnoses of the pathological situations in the skull foramens.^[15] Recently, studies made with CBCT provide advantages compared to direct measurements achieved

by using skulls and cadavers. It is possible to observe the craniofacial bones from different angles with CT and to calculate the lengths and angles of various structures through some software. Furthermore, the occasion of having definite information about the gender and age of the patients makes more reliable study.^[16] The reliability and the accuracy of this method have been shown in the previous studies.^[17,18]

The view of IOF in various shapes has been reported in different studies. Ilayperuma *et al.*^[19] found oval foramen in 57.41% ratio, circular foramen in 31.48% ratio, and semicircular in 11.11% ratio as a result of IOF studies that they conducted on 108 skulls from 38 females and 70 males. The ratio of those which were oblique was found as 85.20% and the ratio of those which were vertical was found as 14.80%. Singh^[20] made morphometric analysis of IOF on 55 skulls. He identified the shape of IOF as circle in 29% ratio, as oval in vertical direction in 42.7% ratio, as oval in horizontal direction in 28.1% ratio. Apinhasmit *et al.*^[21] found the shape of IOF as oval in 50% ratio, as semicircle in 29.2% ratio, and as circle in 20.8% ratio in 106 skulls of 67 males and 39 females. In our study, foramen with oval shape and in oblique direction was found.

Boopathi *et al.*^[13] investigated the vertical and transverse (horizontal) diameter of the IOF in a study conducted on 80 skulls. The horizontal diameter was measured as 2.73 ± 0.73 mm at the right side and as 3.00 ± 0.81 mm at the left side and the mean was measured as 2.82 ± 0.79 mm and, the vertical diameter was measured as 2.79 ± 0.79 mm at the right side and the mean was measured as 2.87 ± 0.78 mm. No statistically significant difference was found between right and left. Kara *et al.*^[22] the mean of the horizontal diameter of IOF and that of the vertical diameter of IOF between genders. The diameter of IOF was found as 1.41 ± 0.30 mm at the right side and 1.58 ± 0.55 mm at the left side and the mean was found as 1.51 ± 0.49 mm in females and it was found as 2.31 ± 0.83 mm at the right side and as 2.00 ± 0.66 mm at the left side and the mean was found as 2.13 ± 0.75 mm in males. Statistically significant difference was found between genders but no statistically significant difference was found between right side and the left side. In the study conducted by Ongeti *et al.*^[23] on 104 skulls related with the foramens in the face the diameter of IOF was measured as 4.24 ± 0.88 mm at the right side and it was measured as 4.39 ± 0.78 mm at the left side in females where as it was measured as 4.89 ± 1.25 mm at the right side and as 4.43 ± 1.13 mm at the right side in males. Statistically significant difference was found between genders. Takahashi *et al.*^[24]

conducted a study about IOF on 28 cadavers. They measured the transverse (horizontal) diameter of IOF as 5.1 mm in females and as 5.7 mm in males and the mean diameter as 5.5 mm. Although statistically significant difference was found between genders, no statistically significant. In our study, we measured the vertical and the horizontal diameters of the IOF. In our study, we found that the vertical diameter at the right side as 3.54 ± 0.56 mm in females and as 3.87 ± 0.60 mm in males and the mean as 3.70 ± 0.60 mm without the distinction between genders and, we measured it at the left side as 3.55 ± 0.60 mm and as 3.92 ± 0.59 mm in males and the mean as 3.73 ± 0.62 mm without the distinction between genders. In our study, we found the vertical diameter at the right side as 3.03 ± 0.56 mm in females and as 3.34 ± 0.60 mm in males and the mean as 3.17 ± 0.60 mm without the distinction between genders and, we measured it at the left side as 2.95 ± 0.50 mm in females and as 3.40 ± 0.46 mm in males and the mean as 3.16 ± 0.53 mm without the distinction between genders. We found significant differences in vertical and horizontal diameters between males and females. To see differences in diameter between genders is due to the difference in skull dimensions with respect to genders, so, we may add the dimensions of other bone structures of the face at the same time.^[25] As a result of the comparison of the obtained results from previous studies, the variations in the anatomic characteristics of IOF may be from the variety of parameters. Moreover, the discrepancy of the population on which the study was conducted and the number of cases studied may be among the causes of this changes.^[26] The hypothesis stating that the diameter of infraorbital reflects the climatic discrepancies and that the face of the populations living in colder climate has larger infraorbital arteries in order to heat the face and thus, their IOFs are larger than those of living in equatorial regions. These hypotheses are based on the assumption that the diameter of the IOF is closely related with area of infraorbital nerve or with that of infraorbital artery.^[27]

Since it is difficult to localize the IOF, the risk that will be confronted increases more in cases with accessory foramen. Therefore, many studies in which accessory foramen has been investigated has been conducted. In the study conducted by Kazkayasi *et al.*^[4] on cadavers, they detected single foramen in 90% of the cases, double foramens in 5% of the cases, and three foramens in 5% of the cases; and they detected single foramen in 94.3% of the cases, double foramens in 5.7% of the cases in another study conducted on skulls.^[28] Ongeti *et al.*^[23] detected single foramen in 95.2% ratio at right side and in 93.3% ratio at left side, double foramens in 2.9% ratio at the right and in 4.8% ratio at the left, and three foramens in 1.9% ratio at either right or left. In a

study conducted by Rai *et al.*^[29] concerning accessory infraorbital foramen on 45 skulls and on 20 maxillas, they found accessory IOF in 13.6% ratio. 73.3% of them were found at right side, 6.6% of them were found at left side, and 20.0% of them were found bilaterally. In a study that we conducted, there was single foramen at right side in 54 (43.20%) cases and at left side in 55 (44.00%) cases. There were double foramen in 69 (55.20%) cases and three foramens in 2 (1.60%) cases at right side. We found double foramen in 64 (51.20%) cases and three foramens in five 5 (4%) cases, and four foramens in 1 case (0.80%) at right side. When we compare our study with the literature the probability of observing double foramen that is, single accessory foramen was found higher in our study. But, observing more than one accessory foramen is an occasional situation and this is consistent with the literature.

In a study conducted by Chrcanovic *et al.*^[30] on totally 80 skulls consisting of 54 females and 26 males, the distance of IOF to the midline was measured as 24.29 ± 2.63 mm in females and as 26.03 ± 2.67 mm in males and the mean distance as 24.86 ± 2.75 mm at the right side. At the left side, these were measured as 25.06 ± 2.12 mm in females, as 26.93 ± 2.46 mm in males and the mean value was 25.66 ± 2.39 mm. Statistically significant difference was found between the right and left side of the two genders. In the study conducted by Gupta^[31] in which foramens in the facial region on 79 skulls were studied, the distance of IOF to the midline was 28.0 ± 2.8 mm at right and as 28.7 ± 2.5 mm at left and the mean was 28.5 ± 2.6 mm. In a study conducted by Hwang *et al.*^[16] conducted on the three-dimensional reconstruction of the CT image, the distance of the IOF was found as 26.1 ± 1.8 mm in females and as 26.9 ± 1.9 mm in males and the mean was found as 26.5 ± 1.9 mm. Statistically significant difference was detected between genders. In our study, we measured the distance of IOF to the midline at the right side as 25.00 ± 2.11 mm in females and as 25.30 ± 2.32 mm in males, and the mean was 25.14 ± 2.21 mm without the distinction between genders; we measured the distance of IOF to the midline at the left side as 24.83 ± 2.08 mm in females and as 25.30 ± 2.18 mm in males, and the mean was 25.06 ± 2.13 mm without the distinction between genders. No statistically significant difference was found between genders.

In a study conducted by Ülker^[32] on 13 skulls and 8 cadavers, they measured the distance between IOF and superior orbital edge in skulls as 43.00 ± 3.05 mm at right and as 42.69 ± 3.42 mm at left. In cadavers, these were found as 43.37 ± 3.70 mm at right and as 41.62 ± 2.77 mm at left. In our study, we measured the

distance of IOF to the superior orbital edge at the right side as 41.46 ± 2.63 mm in females and as 42.55 ± 2.80 mm in males and the mean was 41.98 ± 2.75 mm without the distinction between genders; and we measured the distance of IOF to the superior orbital edge at the left side as 41.50 ± 2.76 mm in females and as 42.23 ± 2.81 mm in males and the mean was 41.84 ± 2.80 mm without the distinction between genders. No statistically significant difference was found between genders.

In the study by Lopes *et al.*^[26] the distance between IOF and the lower edge of the orbita was measured at the right side as 6.36 ± 1.55 mm in females, as 6.64 ± 1.75 mm in males and the mean was 6.57 ± 1.70 mm. At the left side, this was found as 6.46 ± 1.61 mm in females and as 6.87 ± 1.64 mm in females and the mean was 6.76 ± 1.64 mm. In a study conducted by Macedo *et al.*^[33] in which 295 skulls were studied, the distance between IOF and the infraorbital edge was measured as 6.28 ± 1.79 mm at the right side and as 6.45 ± 1.76 mm in at the left side and the mean was measured as 6.37 ± 1.69 mm. No statistically significant difference was found between the right and left side. Xu *et al.*^[34] was found the distance between infraorbital edge and infraorbital midline at right as 9.23 ± 1.90 mm and 9.30 ± 1.55 mm at left from the CT image and the length at the left was found as 8.81 ± 1.76 mm in females and as 9.21 ± 1.33 mm in males. No difference was found between the left side and right side and between genders. In our study, we measured the distance between the IOF and the lower edges of the orbita at the right side as 5.87 ± 1.78 mm in females, as 5.40 ± 1.77 mm in males, and the mean was 5.64 ± 1.78 mm without the distinction between genders; at the left side as 5.88 ± 1.84 mm in females, as 5.34 ± 1.62 mm in males, and the mean was 5.63 ± 1.76 mm without the distinction between genders. No statistically significant difference was found between the left and right side and between genders.

In our study, we also measured the distance between the IOF and the lateral nasal wall and we found the right side as 9.77 ± 2.22 mm in females and as 9.62 ± 3.27 mm in males, and the mean was 9.70 ± 2.76 mm without the distinction between genders. At the left side, we measured as 9.11 ± 2.60 mm in females and as 8.78 ± 2.50 mm in males and we measured the mean as 8.95 ± 2.54 mm without the distinction between genders. No statistically significant difference was found between genders but a statistically significant difference was found between the left and right sides ($P = 0.038$). In the previous studies related with the localization of the IOF, although the distances of foramen to anatomic structures are closer to each other, they demonstrate difference between them. This might be due to the different population. At the

same time, the fact that the used method and the number of cases are different may influence the situation. In our study, the distances of the IOF to the midline, to the lower edge of the orbita and to the upper edge of the orbita are consistent with the literature.

In the study conducted by Shaik *et al.*^[35] the distance between the IOF and anterior nasal spine (ANS) was found as 33.97 ± 5.80 mm at the right and as 34.73 ± 4.70 mm at the left and the mean was found as 34.35 ± 5.25 mm. In the study conducted by Ülker^[32] on skull, the distance between the IOF and anterior nasal spine (ANS) was found as 32.92 ± 2.43 mm at the right and as 32.61 ± 2.29 mm at the left. In the study conducted by Hwang *et al.*^[16] the distance between the IOF and anterior nasal spine (ANS) was found as 34.0 ± 2.3 mm in females and as 36.9 ± 2.2 mm in males and the mean was found as 35.0 ± 2.6 mm. Statistically significant difference was detected between genders. In our study, we also measured the distance between the IOF and the anterior nasal spine (ANS) at the right side as 17.37 ± 3.87 mm in females and as 18.58 ± 3.23 mm in males and the mean was $17.95 \pm .66$ mm without the distinction between genders and, at the left side, we measured as 17.29 ± 3.73 mm in females and as 18.78 ± 4.79 mm in males and we measured the mean as 17.99 ± 4.32 mm without the distinction between genders. No statistically significant difference between genders and the sides was found. The cause why we obtained different results from other studies is the fact that the methods and the parameters used are different. The studies apart from that of Hwang *et al.*^[16] are based on skull. Hwang *et al.*^[16] has used CT three-dimensional images. We utilized cephalometric images in which we have obtained on the complete thickness section that we took the distance of the IOF to the anterior nasal spine (ANS) perpendicularly to Multi Planar Reconstruction image.

Imaging the craniofacial bones with CT from various angles and sections and measuring is possible and in recent times the studies in this respect is being increased. With this characteristic CT provides superiority compared to the direct measurements done by using skull or cadaver. In the CT image of Hwang *et al.*^[16] the soft tissue thickness on the IOF in the sagittal plane was found as 11.4 ± 1.8 mm in females and as 11.5 ± 1.9 mm in males and the mean value was found as 11.4 ± 1.9 mm. No statistically significant difference was detected between genders. We measured the thickness of the soft tissue on the IOF again in the sagittal plane and we obtained similar results. We found at the right side as 11.48 ± 2.45 mm in females and as 11.52 ± 2.52 mm in males and the mean as 11.50 ± 2.48 mm without the distinction of gender. No statistically significant difference was found between

genders and the sides. Gupta^[31] was measured the distance between the right IOF and the left IOF as 53.2 ± 4.3 mm, Song *et al.*^[36] was measured the distance between the right IOF and the left IOF as 54.9 ± 3.4 mm, Tezer *et al.*^[37] was measured the distance between the right IOF and the left IOF as 56.85 ± 3.89 mm, Kazkayasi *et al.*^[4] was measured the distance between the right IOF and the left IOF as 64.44 ± 5.40 mm and Caspersen *et al.*^[38] was measured the distance between the IOF and the left IOF as 51.79 ± 4.13 mm. We found the distance between two IOF in CBCT images as 49.83 ± 3.73 mm in females and as 50.59 ± 4.06 mm in males and we found the mean as 50.20 ± 3.90 mm without the distinction of gender. The results that we have obtained in our study are consistent with the literature.

We evaluated the measurements that we made in our study in terms of age groups. No statistically significant difference was detected between age groups. It is known that the fastest growth rate occurs in the prenatal period. After the delivery, the growth rate reduces abruptly. The growth rate which declined to the minimum value rises to maximum value in adolescence. Then, this maximum growth rate ceases by gradually reducing at mean 17 years old in females and at 19 years old in males. The growth of maxilla also ceases.^[39] Suresh *et al.*^[40] demonstrated that the distance of IOF increase as the age proceeds in a study that he conducted in the images of 48 children with 9.7-year-old-mean age. This result is proportional with the growth rate. In our study, the cause that there is no statistically significant difference between age groups can be explained by the fact that the ages in our study are greater or equal to 20 years old.

In conclusion, knowing the anatomical characteristics and the neighborhood of the infraorbital nerve and the structures that it passes through reduces the complication risks that may occur during the surgical procedures and it ensures easiness for local anesthesia. When the studies available in the literature related with the anatomy of the region are compared, the discrepancies related with the morphometric characteristics of the IOF may be yielded from the racial discrepancies also in addition to the variability of the used method.

The information which is available in the literature related with the IOF has been usually obtained from the studies conducted on the skulls and on the cadaver. Since images possessing lower section thickness and lower section intervals with higher resolution can be acquired through CBCT technique, it ensures the occasion of examination with more details. Therefore, it gives successful results in identifying the anatomic characteristics of the IOF. Moreover, CBCT has advantages such as emitting less

radiation and having less cost and the easiness of use compared to CT. When the discrepancies depending on the population are considered, our study reveals the anatomic characteristics of the IOF in the Turkish people by utilizing the advantages of CBCT.

Financial support and sponsorship

Nil

Conflicts of interest

There are no conflicts of interest

REFERENCES

- Drake RL, Vogl W, Mitchell AWM. Gray's anatomy for students. Yıldırım M (çev. ed). Ankara 2007;8:822-94.
- Hu KS, Kwak J, Koh KS, Abe S, Fontaine C, Kim HJ. Topographic distribution area of the infraorbital nerve. *Surg Radiol Anat* 2007;29:383-8.
- Mozsary PG, Middleton RA. Microsurgical reconstruction of the infraorbital nerves. *J Oral Maxillofac Surg* 1983;4:697-700.
- Kazkayasi M, Ergin A, Ersoy M, Bengi O, Tekdemir I, Elhan A. Certain anatomical relations and the precise morphometry of the infraorbital foramen-canal and groove: An anatomical and cephalometric study. *Laryngoscope* 2001;111:609-14.
- Miracle AC, Mukherji SK. Conebeam CT of the head and neck, part 2: Clinical applications. *AJNR Am J Neuroradiol* 2009;30:1285-92.
- Lascala CA, Panella J, Marques MM. Analysis of the accuracy of linear measurements obtained by cone beam computed tomography (CBCT-NewTom). *Dentomaxillofac Radiol* 2004;33:291-4.
- Pinsky HM, Dyda S, Pinsky RW, Misch KA, Sarment DP. Accuracy of three-dimensional measurements using cone-beam CT. *Dentomaxillofac Radiol* 2006;35:410-6.
- Suomalainen A, Vehmas T, Kortseniemi M, Robinson S, Peltola J. Accuracy of linear measurements using dental cone beam and conventional multislice computed tomography. *Dentomaxillofac Radiol* 2008;37:10-7.
- Cattaneo PM, Bloch CB, Calmar D, Hjortshoj M, Melsen B. Comparison between conventional and cone beam computed tomography generated cephalograms. *Am J Orthod Dentofacial Orthop* 2008;134:798-2.
- Cutright B, Quillopa N, Schubert W. An anthropometric analysis of the key foramina for maxillofacial surgery. *J Oral Maxillofac Surg* 2003;61:354-7.
- Chung MS, Kim HJ, Kang HS, Chung IH. Locational relationship of the supraorbital notch or foramen and infraorbital and mental foramina in Koreans. *Acta Anat (Basel)* 1995;154:162-6.
- Lee UY, Nam SH, Han SH, Choi KN, Kim TJ. Morphological characteristics of the infraorbital foramen and infraorbital canal using three-dimensional models. *Surg Radiol Anat* 2006;28:115-20.
- Boopathi S, Chakravarthy Marx S, Dhalapathy SL, Anupa S. Anthropometric analysis of the infraorbital foramen in a South Indian population. *Singapore Med J* 2010;51:730-5.
- Wilkinson HA. Trigeminal nerve peripheral branch phenol/glycerol injections for tic douloureux. *J Neurosurg* 1999;90:828-32.
- Berge JK, Bergman RA. Variations in size and in symmetry of foramina of the human skull. *Clin Anat* 2001;14:406-13.
- Hwang SH, Kim SW, Park CS, Cho JH, Kang JM. Morphometric analysis of the infraorbital groove, canal, and foramen on three-dimensional reconstruction of computed tomography scans. *Surg Radiol Anat* 2013;35:565-71.
- Hwang SH, Seo JH, Joo YH, Kim BG, Cho JH, Kang JM. An anatomic study using three-dimensional reconstruction for pterygopalatine fossa infiltration via the greater palatine canal. *Clin Anat* 2011;24:576-82.
- Ji Y, Qian Z, Dong Y, Zhou H, Fan X. Quantitative morphometry of the orbit in Chinese adults based on a three-dimensional reconstruction method. *J Anat* 2010;217:501-6.
- Ilayperuma IGNNP. Morphometric Analysis of the infraorbital foramen in adult Sri Lankan skulls. *Int J Morphol* 2010;28:777-82.
- Singh R. Morphometric analysis of infraorbital foramen in Indian dry skulls. *Anat Cell Biol* 2011;44:79-83.
- Apinhasmit W, Chompoopong S, Methathrathip D, Sansuk R, Phetphunphiphat W. Supraorbital notch/foramen, infraorbital foramen and mental foramen in Thais: Anthropometric measurements and surgical relevance. *J Med Assoc Thai* 2006;89:675-82.
- Kara SA, Ünal B, Erdal H, Huvaj S, Koç C. İnfraorbital foramen anatomisinin radyolojik analizi. *Kulak Burun Boğaz ve Baş Boyun Cerrahisi Dergisi* 2003;11:17-21.
- Ongeti K, Hassanali J, Ogeng'o JHS. Biometric features of facial foramina in adult Kenyan skulls. *Eur J Anat* 2008;12:89-95.
- Takahashi Y, Kakizaki H, Nakano T. Infraorbital foramen: Horizontal location in relation to ala nasi. *Ophthal Plast and Reconstr Surg* 2011;27:295-7.
- Cheng AC, Lucas PW, Yuen HK, Lam DS, So KF. Surgical anatomy of the Chinese orbit. *Ophthal Plast and Reconstr Surg* 2008;24:136-41.
- Lopes P, Pereira G, Santos A, Freitas C, Abreu B, Malafaia A. Morphometric analysis of the infraorbital foramen related to gender and laterality in dry skulls of adult individuals in southern Brazil. *Braz J Morphol Sci* 2009;6:19-22.
- Muchlinski MN. The relationship between the infraorbital foramen, infraorbital nerve, and maxillary mechanoreception: Implications for interpreting the paleoecology of fossil mammals based on infraorbital foramen size. *Anat Rec (Hoboken)* 2008;291:1221-6.
- Kazkayasi M, Ergin A, Ersoy M, Tekdemir I, Elhan A. Microscopic anatomy of the infraorbital canal, nerve, and foramen. *Otolaryngol Head Neck Surg* 2003;129:692-7.
- Rai AR, Rai R, Vadgaonkar R, Madhyastha S, Rai RK, Alva D. Anatomical and morphometric analysis of accessory infraorbital foramen. *J Craniofac Surg* 2013;24:2124-6.
- Chrcanovic BR, Abreu MH, Custodio AL. A morphometric analysis of supraorbital and infraorbital foramina relative to surgical landmarks. *Surg Radiol Anat* 2011;33:329-35.
- Gupta T. Localization of important facial foramina encountered in maxillofacial surgery. *Clin Anat* 2008;21:633-40.
- Ülker E. Foramen infraorbitale'nin yetişkin kurukafa ve kadavralardaki yerleşimi ve komşu yumuşak dokularla olan ilişkisinin incelenmesi. Sağlık Bilimleri Enstitüsü, Anatomi Anabilim Dalı, Yüksek Lisans Tezi, Isparta, Süleyman Demirel Üniversitesi 2008.
- Macedo V, Cabrini R, Faig-Leite H. Infraorbital foramen location in dry human skulls. *Braz J Morphol Sci* 2009;26:35-8.
- Xu H, Guo Y, Lv D, Guo J, Liu W, Qi H. Morphological structure of the infraorbital canal using three-dimensional reconstruction. *J Craniofac Surg* 2012;23:1166-8.

35. Shaik HS, Shepur MP, Desai SD, Thomas ST, Maavishettar GF, Haseena S. Morphometric analysis of infra orbital foramen position in south Indian skulls. *Indian J Innovations Dev* 2012;1:22-4.
36. Song WC, Kim SH, Paik DJ, Han SH, Hu KS, Kim HJ. Location of the infraorbital and mental foramen with reference to the soft-tissue landmarks. *Plast Reconstr Surg* 2007;120:1343-7.
37. Tezer M, Oztürk A, Gayretli O, Kale A, Balcioğlu H, Sahinoğlu K. Morphometric analysis of the infraorbital foramen and its localization relative to surgical landmarks. *Minerva Stomatol* 2014;63:333-40.
38. Caspersen LM, Christensen IJ, Kjaer I. Inclination of the infraorbital canal studied on dry skulls expresses the maxillary growth pattern: A new contribution to the understanding of change in inclination of ectopic canines during puberty. *Acta Odontol Scand* 2009;67:341-5.
39. Ülgen PDM. Ortodonti Anomaliler Sefalometri Etioloji Büyüme ve Gelişim, Tanı. T.C. Yeditepe Üniversitesi Yayınları. 2000;213-308.
40. Suresh S, Voronov P, Curran J. Infraorbital nerve block in children: A computerized tomographic measurement of the location of the infraorbital foramen. *Reg Anesth Pain Med* 2006;31:211-4.

