

Original Article

Efficacy of Manual and Mechanical Instrumentation Techniques for Removal of Overextended Root Canal Filling Material

B Kesim, Y Üstün¹, T Aslan¹, HS Topçuoğlu¹, S Şahin¹, Ö Ulusan¹

Private Practice Limited to Endodontics, Uzman Dental Hospital, Kayseri,
¹Department of Endodontics, Faculty of Dentistry, Erciyes University, Kayseri, Turkey

ABSTRACT

Objective: To compare the efficacy of manual and mechanical instrumentation techniques, including ProTaper Universal retreatment system, Mtwo retreatment system, Reciproc system, and Hedström files, regarding removal of overextended root canal filling material. **Materials and Methods:** Eighty extracted human mandibular premolar teeth were prepared at the apical foramen level using Revo-S rotary files and subsequently obturated. The root canal filling material was deliberately extruded from the apex. Samples were transferred to glass vials that simulated the periapical area. Eighty samples of overfilled teeth were randomly assigned to four equal groups ($n = 20$) for removal of the root filling material with ProTaper Universal retreatment files (Group 1), Mtwo retreatment files (Group 2), Reciproc system (Group 3), and hand files (Group 4). Removal of the root canal filling material and additional preparation were performed by individual instruments from each different system up to a #40 size. The external apical surface of the teeth and the surrounding glass vials were checked using a dental operation microscope with $\times 12.5$ magnification. Samples were divided into two groups based on whether removal of the overextended root canal filling material was successful or not. The Fisher's exact test was used to detect any significant difference between the groups ($\alpha = 0.05$). **Results:** The success rate for removal of overextended gutta-percha was greater for the Mtwo (30%) and hand files (30%) compared with the ProTaper (20%) and Reciproc (10%). However, no significant statistical differences existed among the experimental groups ($P > 0.05$). **Conclusions:** This study demonstrated that all tested systems had similar efficacy in removing overextended root canal filling material.

KEYWORDS: Hand instrumentation, overextended root canal filling material, reciprocation, retreatment, rotary

Date of Acceptance:
29-Feb-2016

INTRODUCTION

For optimum success of the initial endodontic treatment, the root canal filling material should remain within the limits of the canal system.^[1] Especially in cases in which the apex of the tooth did not complete maturation or the apical constriction of the tooth is damaged, overextension of the root canal filling material may occur during obturation. Although in some cases it is well-tolerated by apical tissues, extruded obturation material may lead to the initiation of a periapical inflammatory reaction. When initial root canal therapy fails, nonsurgical endodontic retreatment

processes are primarily recommended before employing invasive procedures, such as apical surgery.^[2] Root canal retreatment is a more challenging and laborious process than the initial treatment.^[3] Overextension of the root canal filling material complicates the clinical outcome.

Several nickel-titanium (Ni-Ti) rotary systems have been developed specifically for retreatment procedures.

Address for correspondence: Dr. T Aslan,
Department of Endodontics, Faculty of Dentistry, Erciyes
University, 38039 Kayseri, Turkey.
E-mail: dr.tugrulaslan@hotmail.com

This is an open access article distributed under the terms of the Creative Commons Attribution-Non Commercial-ShareAlike 3.0 License, which allows others to remix, tweak, and build upon the work non-commercially, as long as the author is credited and the new creations are licensed under the identical terms.

For reprints contact: reprints@medknow.com

How to cite this article: Kesim B, Üstün Y, Aslan T, Topçuoğlu HS, Şahin S, Ulusan Ö. Efficacy of manual and mechanical instrumentation techniques for removal of overextended root canal filling material. Niger J Clin Pract 2017;20:761-6.

Access this article online	
Quick Response Code:	Website: www.njcponline.com
	DOI: 10.4103/1119-3077.180069

The ProTaper Universal retreatment system (Dentsply Maillefer, Ballaigues, Switzerland) and Mtwo retreatment system (VDW, Munich, Germany) are two well-known systems that are used for removing root canal filling material. Although the Reciproc system (VDW, Munich, Germany) was not originally designed for retreatment processes, it can be as effective as specifically designed rotary retreatment systems.^[4]

A few studies^[5-9] evaluating the efficacy of various Ni-Ti systems for removing root canal filling material within the root canal system have been published. However, to the best of our knowledge, no studies exist in the literature concerning the efficacy of different Ni-Ti systems for the removal of overextruded root canal filling material. Therefore, the purpose of this study was to compare *in vitro* the efficacy of removing overextended root canal filling material from straight canals of mandibular premolars, using manual and mechanical instrumentation techniques, including ProTaper retreatment files, Mtwo retreatment system, Reciproc system, and Hedström files.

MATERIALS AND METHODS

Specimen preparation

After approval by the ethics committee (number 454/2015), 80 single-rooted straight premolars were selected for this study. The premolars had mature apices with no calcification or internal resorption in which the first file fitted at the apex was a size 15. The selected teeth were stored in 0.1% thymol solution until use. Teeth with >10° of curvature were discarded. The soft-tissue remnants and the calculus on the external root surface were removed. Teeth were examined under an operating microscope (Zeiss Opmi; Carl Zeiss, Jena, Germany) to confirm the presence of a single apical foramen.

Root canal preparation and obturation

The length of the teeth was standardized at 18 mm by partially removing the coronal part of the teeth with a high-speed bur. Access cavities were prepared and canal orifices were located. A #10 K-file (Dentsply Maillefer, Ballaigues, Switzerland) was introduced into the canal until visible at the apical foramen. The working length (WL) was determined at the apical foramen to represent the situation that may be faced upon loss or overestimation of the WL measure. The WL measures were recorded for each tooth to be examined in the retreatment process. Root canal preparation was performed using Revo-S rotary files (Micro-Mega, Besancon, France) up to a master apical size equal to 35. The rotary files were used at 300 rpm in a sequence of SC1 (25/.06), SC2 (25/.04), SU (25/.06), AS 30 (30/.06), and AS 35 (35/.06). SC1 was used to enlarge the coronal two-thirds of the canal. The SC2, SU, AS 30, and AS 35 instruments were used to prepare canals until reaching

WL. Root canals were irrigated with 2 mL of 2.5% sodium hypochlorite (NaOCl) between the application of each file size by using a syringe and a 29-gauge needle (NaviTip; Ultradent, South Jordan, UT). After completion of the preparation, the canals were irrigated with 5 mL of 17% EDTA for 1 min and subsequently rinsed with 5 mL of distilled water. The root canals were dried with paper points and filled with an MM seal (Micro Mega, Besancon, France) and gutta-percha cones using a cold lateral condensation technique. The smaller size of the master gutta-percha point rather than the master apical file (Size #30, taper. 02) was selected as the master cone to simulate the clinical aspect of an overextended root canal filling. Thus, the root canal obturation material was deliberately extruded from the apex. Subsequently, the teeth were stored at 37°C with 100% humidity for 7 days to allow for setting of the sealer. In all samples, the length of overextended gutta-percha points was measured by a digital caliper and standardized at 2 ± 0.5 mm.

Test apparatus

The 80 overfilled teeth were randomly assigned to four equal groups for removal of the root filling material with the ProTaper Universal retreatment files (Group 1), Mtwo retreatment files (Group 2), Reciproc system files (Group 3), or Hedström hand files (Group 4). The retreatment process was performed at a position 1 mm shorter than WL (WL-1) that was separately recorded at the apical foramen level. Holes were created in rubber stoppers of glass vials. Each tooth was inserted gently with finger pressure into the rubber stopper and fixated with cyanoacrylate cement. Subsequently, glass vials, used to simulate the periapical area, were covered with an opaque sticking plaster to obscure the root apex from the vision of the operator [Figure 1].

Gutta-percha removal procedure

Group 1

The ProTaper Universal retreatment files—D1 (size 30, 0.09 taper, length 16 mm), D2 (size 25, 0.08 taper, length 18 mm), and D3 (size 20, 0.07 taper, length 22 mm)—were used sequentially. Final preparation was performed with F3 (size 30, 0.09 taper) and F4 (size 40, 0.06 taper) files at the WL-1 position.

Group 2

The Mtwo retreatment files—Mtwo R1 (size 25, 0.05 taper) and Mtwo R2 (size 15, 0.05 taper)—were used for removal of the gutta-percha. Final canal preparation was performed with the Mtwo files size 30, 0.06 taper; size 35, 0.06 taper; and size 40, 0.06 taper at the WL-1 position.

Group 3

The Reciproc R25 system (size 25, 0.08 taper over the first 3 mm) was used for removal of the gutta-percha. The final canal preparation was performed with an R40

file (size 40, 0.06 taper over the first 3 mm) at the WL-1 position.

Group 4

The gutta-percha was removed from the coronal and middle third of the tooth with sizes 3 and 2 Gates Glidden drills. Subsequently, sizes 35, 30, and 25 Hedström files were used sequentially in a “crown-down” manner for removal of the gutta-percha. Finally, root canals were prepared up to the size of 40 H-file at the WL-1 position.

A single operator performed all root canal filling removal protocols. Each instrument was used to retreat only five root canals. A total of 25 ml 2.5% NaOCl solution for each tooth was used for irrigation during removal of the canal filling material. In each group, root filling removal was deemed complete when the WL-1 position was reached, and no additional gutta-percha could be observed on the last instrument or in the root canal system. A dental operation microscope (Zeiss Opmi; Carl Zeiss, Jena, Germany) $\times 12.5$ magnification was used to check the canal filling removal procedure throughout the investigation.

Evaluation of removal of overextended filling

The removal of all root canal filling material was performed by a single operator and evaluation was conducted by two additional independent examiners who were blinded to the group assignment. The sticky plaster covering was removed from the glass vials after completion of the removal of the root canal filling material. All samples in the glass vials were examined from the outside with the aid of a dental operation microscope ($\times 12.5$ magnification) to determine whether or not overextended filling material remained adhered to the external surface of the apex stands. The teeth were classified after apical area examination using the dental operation microscope according to the following two types:

- Successful removal: No overextended gutta-percha existed on external root surfaces and in the surrounding glass vials that simulated the periapical area
- Failed removal: Overextended gutta-percha existed on the external root surfaces and in the surrounding glass vials that simulated the periapical area.

Statistical analysis

The analyses were performed using statistical software (SPSS version 20.0, SPSS Inc., Chicago, IL, USA). The Fisher's exact test was used to detect any significant differences among the groups. The significance level for statistical comparison was set at $\alpha = 0.05$.

RESULTS

Figure 2 displays the number and percentage of successful removal of overextended gutta-percha from



Figure 1: Representative images from test apparatus. Arrow points overextended gutta-percha. (a) Glass vial containing overfilled teeth. (b) Glass vial covering with opaque plaster

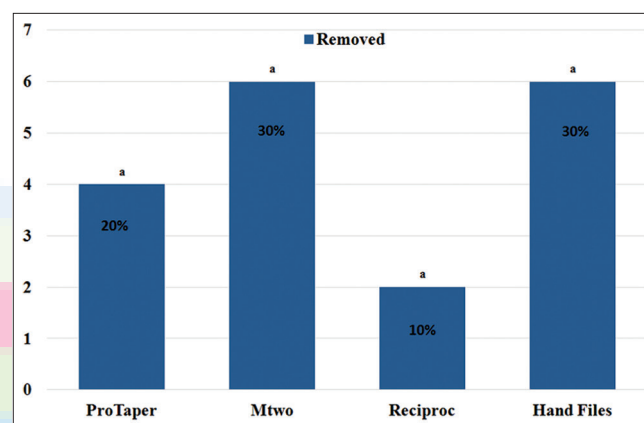


Figure 2: Number and percentage of successful removal of overextended gutta-percha from samples. Same superscript letters denote no statistical differences among groups ($P > 0.05$)

samples. The Fisher's exact test demonstrated that no significant differences existed between the groups regarding the removal of the overextended gutta-percha fillings ($P = 0.367$).

DISCUSSION

Complete removal of root canal filling material is the primary goal of nonsurgical endodontic retreatment processes. Necrotic tissues and bacterial remnants in the root canal can lead to endodontic treatment failures. In addition, overextended root canal filling material can affect the prognosis negatively in two ways: By hosting contaminated material and by triggering a persistent inflammatory reaction to a foreign body. The apical third of the root canal system is known as the most difficult area for the removal of root canal filling material.^[10] In addition, removing overextended material is one of the most challenging stages of retreatment cases.

To date, many techniques have been proposed for the removal of canal filling material.^[6,11,12] The present study aimed to determine whether a plausible and standard method exists regarding the removal of overextended root canal filling material. The efficacy of hand files, Ni-Ti rotary systems, and reciprocal system was compared for removing overextended canal filling material in this study.

Single-rooted mandibular premolar teeth were used in this study to eliminate root canal anatomy variations that could affect the results of the study. Differences in tooth crown anatomies and access cavity variations were prevented by the partial removal of the tooth crowns for the purpose of obtaining an 18 mm root length in every sample. Processing to remove root canal filling material was terminated when no further filling material was observed adhering to the instrument or the canal walls.

Some studies in the literature have emphasized the importance of using a dental operation microscope for remnant detection during the retreatment process.^[13,14] In the present study, samples were examined using a dental operation microscope under $\times 12.5$ magnification. One published study advocates a radiographic examination method that could be misleading for determining if any filling material remains.^[15] However, Kfir *et al.*^[13] claimed that use of a dental operation microscope is a more reliable method than the radiographic technique for detecting residual canal filling material. Because the aim of the current study is focused on the removal of overextended root canal filling material, transparent glass vials were checked visually from the outside by a dental operation microscope without any invasive requirements for the samples.

In a case report,^[1] rotary systems were referred to as nonsafe options for the removal of extruded portions of gutta-percha. Nevertheless, conventional removal of gutta-percha by hand files can be painstaking and time-consuming, particularly when the filling material is highly condensed.^[16] In addition, overextended root canal filling material can occur especially in cases of immature, resorbed, or overinstrumented root canal apices.^[17] Even when working with hand files, canal filling material can be pushed through the periapical area in teeth causing apical constriction damage.

In previous studies, various techniques, solvents, or adjunct technologies were used for removal of root canal filling material. However, a solvent was not used in the present study because of the potential for cytotoxic effects and concern regarding complete root canal cleaning.^[18,19]

In the current study, a terminal apical enlargement size was selected that was greater than the initial preparation

size to reduce the amount of residual filling material. Hülsmann *et al.*^[20] argued that the root canal system should be reprepared for efficient irrigation and obturation in retreatment cases. Nonetheless, in the same study, the authors warned that complications, such as perforations or weakening the remaining root structure, might occur if excessive preparation was performed. Therefore, additional preparation was performed with an individual #40 size instrument that is common to the different systems used in all groups tested.

The endodontic retreatment procedure is clinically difficult and complete removal of root canal filling material is almost impossible.^[7,21-24] In this study, the total success rate of all retreatment systems used to remove overextended gutta-percha from samples was 22.5%. Favorable results were observed in this study for hand files and Mtwo system. No previous studies exist that investigated the efficacy of various instrumentation systems for removing overextended gutta-percha; therefore, these results could not be compared.

In a previous study, Bramante *et al.*^[25] claimed that the Mtwo R instruments were less effective than the ProTaper Universal retreatment files or hand files. Both Mtwo R instruments and ProTaper Universal retreatment files have unique design features. The ProTaper retreatment D1 file produces a cutting action with a negative cutting angle and no radial land.^[4] Mtwo R files have a cutting tip and a constant helical angle which ensure the instrument's easy progression into the gutta-percha filling, without the need to exert pressure.^[26] Because there is an apical stop, the cutting action is more rapid and efficient.^[25] However, when apical damage exists, and in cases of potential contact with the maximum volume of gutta-percha, less aggressive systems may be preferred to avoid apical extrusion of the gutta-percha. In Mtwo group, Mtwo rotary files that used for additional instrumentation generate a planing action and are capable of by-passing the canal filling material^[16] by using a noncutting tip and a positive rake angle with two cutting edges.^[27] Therefore, a planing action was determined to be more plausible for removing overextended root canal filling material.

In contrast, Mollo *et al.*^[23] determined that the Mtwo R files were more effective than conventional hand files. In a previous study, a combined use of rotary and hand instruments was proposed to achieve optimal cleanliness of the canal walls, especially in the apical third of the root canal system of the tooth.^[5] In the current study, favorable results achieved by the Mtwo system and hand files in overfilled teeth may be related to the use of less aggressive techniques.

In this study, no significant differences were found among the groups considering removal of overextended

gutta-percha. After microscopic examination, the samples in each of the four groups were interpreted as successful or failed. In all groups, the number of teeth which were free from gutta-percha apically was unsatisfactory. If gutta-percha pieces derived from samples that fragmented or were nonintegrated dropped to the surrounding glass vials that simulated the periapical area, the samples were classified as failures. The success rate for the removal of overextended gutta-percha was higher for the Mtwo system (30%) and hand files (30%) compared with the ProTaper (20%) and Reciproc system (10%), but no significant differences were observed among all experimental groups.

CONCLUSIONS

The ProTaper and Reciproc are well-known systems with increased cutting ability.^[4,28] Likewise, efficacy of these systems regarding the removal of root canal filling materials has been proved in many studies in the literature.^[4,28-30] Within the limitations of this study, the Reciproc and ProTaper systems were as effective as the Mtwo system and hand files for removing overextended root canal filling material. Further investigations regarding removal of overextended root canal filling material with different techniques are needed.

Financial support and sponsorship

Nil.

Conflicts of interest

There are no conflicts of interest.

REFERENCES

- Silva EJ, Herrera DR, Lima TF, Zaia AA. A nonsurgical technique for the removal of overextended gutta-percha. *J Contemp Dent Pract* 2012;13:219-21.
- Paik S, Sechrist C, Torabinejad M. Levels of evidence for the outcome of endodontic retreatment. *J Endod* 2004;30:745-50.
- Duncan HF, Chong BS. Removal of root filling materials. *Endod Topics* 2008;19:33-57.
- Giuliani V, Cocchetti R, Pagavino G. Efficacy of ProTaper universal retreatment files in removing filling materials during root canal retreatment. *J Endod* 2008;34:1381-4.
- Somma F, Cammarota G, Plotino G, Grande NM, Pameijer CH. The effectiveness of manual and mechanical instrumentation for the retreatment of three different root canal filling materials. *J Endod* 2008;34:466-9.
- Pirani C, Pelliccioni GA, Marchionni S, Montebugnoli L, Piana G, Prati C. Effectiveness of three different retreatment techniques in canals filled with compacted gutta-percha or Thermafil: A scanning electron microscope study. *J Endod* 2009;35:1433-40.
- Marques da Silva B, Baratto-Filho F, Leonardi DP, Henrique Borges A, Volpato L, Branco Barletta F. Effectiveness of ProTaper, D-RaCe, and Mtwo retreatment files with and without supplementary instruments in the removal of root canal filling material. *Int Endod J* 2012;45:927-32.
- Rios Mde A, Villela AM, Cunha RS, Velasco RC, De Martin AS, Kato AS, *et al.* Efficacy of 2 reciprocating systems compared with a rotary retreatment system for gutta-percha removal. *J Endod* 2014;40:543-6.
- Rödig T, Reicherts P, Konietschke F, Dullin C, Hahn W, Hülsmann M. Efficacy of reciprocating and rotary NiTi instruments for retreatment of curved root canals assessed by micro-CT. *Int Endod J* 2014;47:942-8.
- Hülsmann M, Bluhm V. Efficacy, cleaning ability and safety of different rotary NiTi instruments in root canal retreatment. *Int Endod J* 2004;37:468-76.
- Peters LB, van Winkelhoff AJ, Buijs JF, Wesselink PR. Effects of instrumentation, irrigation and dressing with calcium hydroxide on infection in pulpless teeth with periapical bone lesions. *Int Endod J* 2002;35:13-21.
- Masiero AV, Barletta FB. Effectiveness of different techniques for removing gutta-percha during retreatment. *Int Endod J* 2005;38:2-7.
- Kfir A, Tsesis I, Yakirevich E, Matalon S, Abramovitz I. The efficacy of five techniques for removing root filling material: Microscopic versus radiographic evaluation. *Int Endod J* 2012;45:35-41.
- Schirrmeyer JF, Wrbas KT, Meyer KM, Altenburger MJ, Hellwig E. Efficacy of different rotary instruments for gutta-percha removal in root canal retreatment. *J Endod* 2006;32:469-72.
- de Carvalho Maciel AC, Zaccaro Scelza MF. Efficacy of automated versus hand instrumentation during root canal retreatment: An *ex vivo* study. *Int Endod J* 2006;39:779-84.
- Tasdemir T, Yildirim T, Celik D. Comparative study of removal of current endodontic fillings. *J Endod* 2008;34:326-9.
- Khabbaz MG, Papadopoulos PD. Deposition of calcified tissue around an overextended gutta-percha cone: Case report. *Int Endod J* 1999;32:232-5.
- Gu LS, Ling JQ, Wei X, Huang XY. Efficacy of ProTaper Universal rotary retreatment system for gutta-percha removal from root canals. *Int Endod J* 2008;41:288-95.
- Sae-Lim V, Rajamanickam I, Lim BK, Lee HL. Effectiveness of ProFile .04 taper rotary instruments in endodontic retreatment. *J Endod* 2000;26:100-4.
- Hülsmann M, Drebenstedt S, Holscher C. Shaping and filling root canals during root canal re-treatment. *Endod Topics* 2008;19:74-124.
- Marfisi K, Mercade M, Plotino G, Duran-Sindreu F, Bueno R, Roig M. Efficacy of three different rotary files to remove gutta-percha and Resilon from root canals. *Int Endod J* 2010;43:1022-8.
- de Mello Junior JE, Cunha RS, Bueno CE, Zuolo ML. Retreatment efficacy of gutta-percha removal using a clinical microscope and ultrasonic instruments: Part I – An *ex vivo* study. *Oral Surg Oral Med Oral Pathol Oral Radiol Endod* 2009;108:e59-62.
- Mollo A, Botti G, Principi Goldoni N, Randellini E, Paragliola R, Chazine M, *et al.* Efficacy of two Ni-Ti systems and hand files for removing gutta-percha from root canals. *Int Endod J* 2012;45:1-6.
- Rödig T, Hausdörfer T, Konietschke F, Dullin C, Hahn W, Hülsmann M. Efficacy of D-RaCe and ProTaper Universal Retreatment NiTi instruments and hand files in removing gutta-percha from curved root canals – A micro-computed tomography study. *Int Endod J* 2012;45:580-9.
- Bramante CM, Fidelis NS, Assumpção TS, Bernardineli N, Garcia RB, Bramante AS, *et al.* Heat release, time required, and cleaning ability of MTwo R and ProTaper universal

- retreatment systems in the removal of filling material. *J Endod* 2010;36:1870-3.
26. VDW-Dental. Munich/Germany. Available from: <http://www.vdw-dental.com/en/products/rotary-preparation/mtwo.html>. [Last cited on 2015 Nov 22].
 27. Schäfer E, Erler M, Dammaschke T. Comparative study on the shaping ability and cleaning efficiency of rotary Mtwo instruments. Part 1. Shaping ability in simulated curved canals. *Int Endod J* 2006;39:196-202.
 28. Versiani MA, Leoni GB, Steier L, De-Deus G, Tassani S, Pécora JD, *et al.* Micro-computed tomography study of oval-shaped canals prepared with the self-adjusting file, Reciproc, WaveOne, and ProTaper universal systems. *J Endod* 2013;39:1060-6.
 29. Zuolo AS, Mello JE Jr., Cunha RS, Zuolo ML, Bueno CE. Efficacy of reciprocating and rotary techniques for removing filling material during root canal retreatment. *Int Endod J* 2013;46:947-53.
 30. Takahashi CM, Cunha RS, de Martin AS, Fontana CE, Silveira CF, da Silveira Bueno CE. *In vitro* evaluation of the effectiveness of ProTaper universal rotary retreatment system for gutta-percha removal with or without a solvent. *J Endod* 2009;35:1580-3.

