

## ORIGINAL ARTICLE

# Central region morphometry in a child brain; Age and gender differences

İ Otağ, H Tetiker<sup>1</sup>, Mİ Koşar<sup>1</sup>, A Otağ<sup>2</sup>, M Atalar<sup>3</sup>, M Çimen<sup>4</sup>

Department of medical services, Vocational School of Health Services, <sup>2</sup> Department of health sciences, Physical Education and Sport High School, <sup>3</sup>Department of Radiology, <sup>4</sup>Department of Anatomy, Faculty of Medicine, Cumhuriyet University, Sivas, <sup>1</sup>Department of Anatomy, Faculty of Medicine, Muğla Sıtkı Koçman University, Muğla, Turkey

## Abstract

**Background:** Data on central region morphometry of a child brain is important not only in terms of providing us with information about central region anatomy of the brain but also in terms of the help of this information for the plans to be applied in neurosurgery.

**Objective:** In the present study, central region morphometry of a child brain in mid-sagittal MR images was analyzed in age and gender groups.

**Materials and Methods:** Different points determined previously, *commissura posterior* (PC) and the distances between cerebral cortex point (VCS) vertical to *commissura anterior- commissura posterior* line, *sulcus centralis* (CS), *sulcus marginalis* (MS), and the angle ( $\alpha$ ) between CS-PC-MS were determined and measured together with difference of gender in three different age groups (aged 6-9, 10-13, and 14-17).

**Results:** Central region measures of the brains of boys aged 6-17 are higher than girls except for MS-PC distance. While VCS-PC, CS-PC, and MS-PC measures display a significant difference in the girls aged 14-17 when compared to the other age groups of 6-9 and 10-13 ( $P < 0.05$ ), angle  $\alpha$  is not significantly different in age and gender groups ( $P > 0.05$ ). However, while VCS-PC, CS-PC and MS-PC distances show a significant increase in girls beginning from the age of 14, this increase is limited in boys.

**Conclusion:** Morphometric differences observed in different age groups in boys and girls shall contribute our evaluation of the alterations in brain development in both of genders and shall be useful in preparation of surgical operation plans to be applied to the central region.

**Key words:** Brain, central region, child, morphometry, magnetic resonance Imaging

**Date of Acceptance:** 10-Oct-2013

## Introduction

Without touching the target brain structures aimed to minimize the risks and patient complications that might occur during microsurgical operations on the brain, intracranial lesions are reached by retracting it mildly.<sup>[1,2]</sup> In surgical approach plan, not only width of the lesion but also neural and vascular proximity is important. Morphometric studies contribute greatly to the development of surgical plan.

MRI techniques provide anatomic brain images, which allow morphometric brain studies, and they are used so

often.<sup>[3,4]</sup> These techniques allow for determination of small brain structures and diagnosis of small intracerebral lesions<sup>[5]</sup> as well as the studies of length,<sup>[1]</sup> volume,<sup>[6,7]</sup> and functional methods determining the alterations in blood oxygenation, which reflects the changes during neural activities.<sup>[8]</sup> Furthermore, MRI studies facilitate constitution of patient, normal, gender, and age sample groups. Understanding morphometric differences between the groups and the direction of normal brain

### Address for correspondence:

Dr. İlhan Otağ,  
Vocational School of Health Services,  
Cumhuriyet University, Sivas, Turkey.  
E-mail: [ilhanotag@gmail.com](mailto:ilhanotag@gmail.com)

### Access this article online

Quick Response Code:	Website: <a href="http://www.njcponline.com">www.njcponline.com</a>
	DOI: ***
	PMID: *****

development is crucial for interpretation of clinical imaging studies.<sup>[9,10]</sup>

The brain morphometric studies are mostly related to adults. However, the brain of an adult is different from that of a child in terms of size and shape. The brain continues its development during childhood. When the entire head is taken into consideration, a strong influence of age is observed in all sizes.<sup>[11]</sup> The morphometric studies performed in child brains shall contribute to our determination of the differences with the adult brains. Moreover, brain morphometry shows difference also in gender groups. The brain volume reaches the peak at the age of 14.5 in men and 10.5 in women.<sup>[7]</sup> Brain volume of men is 7-10% bigger than the women.<sup>[4,7,12]</sup>

Morphometric brain studies performed for age and gender samples in normal or patient groups enlighten sensitive surgical plans. Many of intracranial lesions are taken by transcallosal technique by means of *corpus callosum*, subfrontal technique by means of *lamina terminalis*, and transcortical-transventricular and transcallosal subchoroidal technique by means of interhemispheric transcallosal-interforniceal, lateral ventricle according to their qualities, and position and combinations of these techniques.<sup>[13]</sup> Central region morphometry shall help surgical operations to be applied to the third ventricle and surrounding lesions.

## Materials and Methods

In the present study, total 90 child brain MRIs, 30 MRIs (15 of boys, 15 of girls) for three groups of childhood (aged 6-9, aged 10-13, and aged 14-17), were examined prospectively. The research was performed on a Model 2001 1.5 Tesla MRI device (Exelart, Toshiba, Tokyo, Japan) in Cumhuriyet University, Faculty of Medicine, Research and Training Hospital, Department of Radiology. Evaluation of images was carried out using Toshiba software (V4.10, Exelart, Tokyo, Japan). Screen resolution was 1024 × 768 pixels. All images were evaluated by observer with 12-years experience in pediatric neuroradiology interpretation. The images were taken by sagittal T1-weighted fast spin echo (SE) technique (Repetition time (TR): 500 ms; Echo time (TE): 10 ms; Flip angle (FA): 90/16, Number of excitation (NEX):2; Field of view (FOV): 180 × 220 mm; Matrix: 224 × 320; Slice Thickness: 6.2 mm).

In mid-sagittal MR images, the distance between cerebral cortex point vertical to *commissura anterior-commissura posterior* line and *commissura posterior* (VCS-PC), the distance between *sulcus centralis* in cerebral cortex and *commissura posterior* (CS-PC), *sulcus marginalis* which is a branch of *sulcus cingulate* in cerebral cortex and *commissura*

*posterior* (MS-PC) and additionally to these measures of length, the angle between *sulcus centralis-commissura posterior* – *sulcus marginalis* ( $\alpha$ ) were measured [Figure 1]. The data was evaluated with SPSS (14.0) program.

## Results

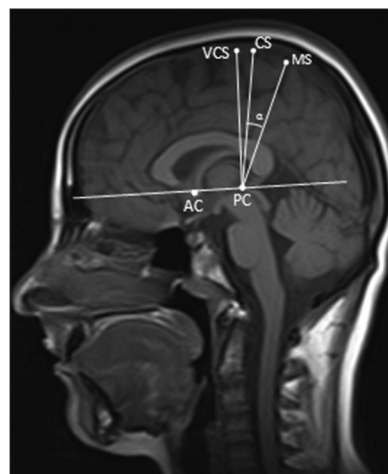
Without considering the gender, VCS-PC, CS-PC, MS-PC distances, and angle  $\alpha$  were measured in children in three age groups (age group of 6-9, 10-13, and 14-17) and totally. Statistical mean, standard deviation, the lowest and the highest value of every measurement were determined [Table 1].

Based on the statistical analysis, without considering the gender, VCS-PC, CS-PC, and MS-PC distances of children in age group of 14-17 are significantly different from the age group of 6-9 and 10-13 ( $P < 0.05$ ). For the age groups of 6-9 and 10-13, the difference between VCS-PC, CS-PC, and MS-PC distances is not significant ( $P > 0.05$ ). Angle  $\alpha$  is not significant for all of the three groups ( $P > 0.05$ ).

VCS-PC, CS-PC, MS-PC distances, and angle  $\alpha$  were measured in boys in all of three age groups (age groups of 6-9, 10-13, and 14-17) and in total. Statistical mean, standard deviation, the lowest and the highest value of every measurement were determined [Table 2].

In the study performed for age groups of boys, the differences between VCS-PC, CS-PC, MS-PC, and angle  $\alpha$  are not significant in all of three age groups ( $P > 0.05$ ).

VCS-PC, CS-PC, MS-PC, distances and angle  $\alpha$  were measured in girls in all of three age groups (age groups of 6-9, 10-13, and 14-17) and in total. Statistical mean,



**Figure 1:** VCS-PC, CS-PC, MS-PC distances, and angle  $\alpha$  in mid-sagittal brain MR images. PC: *Commissura posterior* VCS: The distances between cerebral cortex point vertical to *commissura anterior- commissura posterior* line CS: *Sulcus centralis* MS: *Sulcus marginalis*  $\alpha$ : The angle between CS-PC-MS

**Table 1: Without considering the gender, values of VCS-PC, CS-PC, MS-PC distances, and angle  $\alpha$  in children aged between 6-9, 10-13, and 14-17 and totally aged between 6-17. PC: Commissura posterior VCS: The distances between cerebral cortex point vertical to commissura anterior-commissura posterior line CS: Sulcus centralis MS: Sulcus marginalis  $\alpha$ : The angle between CS-PC-MS**

	Age	N	Minimum	Maximum	Mean	Std. Dev.
VCS-PC	6-9	30	62.0	76.0	69.6	2.8
	10-13	30	58.0	80.0	69.4	5.2
	14-17*	30	66.0	80.0	72.9	3.3
	Total	90	58.0	80.0	70.6	4.2
CS-PC	6-9	30	62.0	74.0	68.3	2.8
	10-13	30	57.0	78.0	67.9	4.5
	14-17*	30	65.0	79.0	71.5	3.6
	Total	90	57.0	79.0	69.2	4.0
MS-PC	6-9	30	55.0	72.0	66.0	3.6
	10-13	30	56.0	73.0	66.6	4.1
	14-17*	30	63.0	80.0	69.9	3.5
	Total	90	55.0	80.0	67.5	4.1
$\alpha$	6-9	30	7.4	19.0	13.7	3.1
	10-13	30	7.9	25.0	14.0	4.2
	14-17	30	10.4	21.0	14.0	2.5
	Total	90	7.4	25.0	13.9	3.3

\*Values are significantly different ( $P < 0.05$ )

**Table 2: Values of VCS-PC, CS-PC, MS-PC distances, and angle  $\alpha$  in boys aged between 6-9, 10-13, and 14-17 and totally aged between 6-17. PC: Commissura posterior VCS: The distances between cerebral cortex point vertical to commissura anterior-commissura posterior line CS: Sulcus centralis MS: Sulcus marginalis  $\alpha$ : The angle between CS-PC-MS**

	Age	N	Minimum	Maximum	Mean	Std. Dev.
VCS-PC	6-9	15	62.0	74.0	69.8	2.9
	10-13	15	58.0	80.0	70.8	5.2
	14-17	15	66.0	80.0	72.4	4.0
	Total	45	58.0	80.0	70.9	4.2
CS-PC	6-9	15	62.0	74.0	68.4	3.3
	10-13	15	61.0	78.0	69.1	3.7
	14-17	15	65.0	79.0	71.2	4.1
	Total	45	61.0	79.0	69.5	3.8
MS-PC	6-9	15	55.0	70.0	65.7	3.8
	10-13	15	58.0	73.0	67.7	3.7
	14-17	15	64.0	80.0	69.4	4.1
	Total	45	55.0	80.0	67.5	4.1
$\alpha$	6-9	15	7.6	19.0	14.7	2.9
	10-13	15	7.9	20.0	13.1	3.8
	14-17	15	10.4	21.0	13.4	2.9
	Total	45	7.6	21.0	13.8	3.2

\*Values are significantly different ( $P < 0.05$ )

standard deviation, the lowest and the highest value of every measurement were determined [Table 3].

**Table 3: Values of VCS-PC, CS-PC, MS-PC distances, and angle  $\alpha$  in girls aged between 6-9, 10-13, and 14-17 and totally aged between 6-17. PC: Commissura posterior VCS: The distances between cerebral cortex point vertical to commissura anterior-commissura posterior line CS: Sulcus centralis MS: Sulcus marginalis  $\alpha$ : The angle between CS-PC-MS**

	Age	N	Minimum	Maximum	Mean	Std. Dev.
VCS-PC	6-9	15	64.0	76.0	69.5	2.8
	10-13	15	59.0	76.0	68.2	5.1
	14-17*	15	69.0	79.0	73.2	2.7
	Total	45	59.0	79.0	70.4	4.2
CS-PC	6-9	15	64.0	74.0	68.2	2.2
	10-13	15	57.0	73.0	66.9	4.9
	14-17*	15	65.0	77.0	71.7	3.2
	Total	45	57.0	77.0	69.0	4.1
MS-PC	6-9	15	59.0	72.0	66.4	3.4
	10-13	15	56.0	71.0	65.7	4.4
	14-17*	15	63.0	74.0	70.3	3.0
	Total	45	56.0	74.0	67.5	4.1
$\alpha$	6-9	15	7.4	17.7	12.6	3.0
	10-13	15	9.6	25.0	14.8	4.5
	14-17	15	10.7	20.0	14.5	2.2
	Total	45	7.4	25.0	14.0	3.4

\*Values are significantly different ( $P < 0.05$ )

According to the statistical analysis, VCS-PC, CS-PC, and MS-PC distances of girls aged between 14-17 are significantly different from those aged between 6-9 and 10-13 ( $P < 0.05$ ). There is not a significant difference between VCS-PC, CS-PC, and MS-PC distances of girls aged between 6-9 and 10-13 ( $P > 0.05$ ). Angle  $\alpha$  is not significant between all of the groups ( $P > 0.05$ ).

## Discussion

In the present study, we examined central region morphometry of a normal child brain in the age groups of 6-9, 10-13, and 14-17 and impact of gender on this morphometry.

MR images provide anatomic data, which allows for constitution of the intended sample groups and brain morphometric studies during development.<sup>[14]</sup> MRI studies are especially convenient in children, because ionized radiation is not used.<sup>[17]</sup> In our research, we used MRI to reveal developmental difference of the brain's central region based on age and gender in normal child brains.

Age has a strong impact on all brain sizes.<sup>[11]</sup> This impact is evidently seen in central region morphometric measurements of a normal child brain. Without considering gender, in the analysis, we performed to show the impact of only age in central region of a normal child brain; it was found that there are significant differences between the development in the children aged between 14-17 and the

development in the children aged between 6-9 and 10-13 in terms of all distances ( $P < 0.05$ ). Development of the brain's central region is slow between the ages 6-13. However, angle  $\alpha$  shows no significant differences in all age groups, and this situation suggests that central region of the brain maintains its general shape during development.

In the studies revealing the differences of brain development based on gender, it was determined that a male brain is 7%-10% bigger than the volume of female brain.<sup>[4,7,12]</sup> However, the brain begins to develop earlier in women than men.<sup>[7]</sup> Although there is a development in all age groups in VCS-PC, CS-PC, and MS-PC distances relating to the posterior of central region of a boy brain, this development does not show any significant difference in spite of accelerating between the ages 14-17 ( $P > 0.05$ ). In girls, there is a fast development in posterior distances of central region of the brain between the ages 14-17. This development makes up a significant difference when compared to the girls aged between 6-9 and 10-13 ( $P < 0.05$ ). Morphometric measures of the brain's central region in girls develop fast after the age 14 and reach the measures of boys and even exceed them a bit. This data suggests that development of the brains central region in girls starts to develop earlier when compared to boys.

*Commissura anterior* and *commissura posterior* are used as reference points in brain measurements.<sup>[15]</sup> *Sulcus centralis* is an important and a functional reference in neurosurgery. Therefore, it is an obligation to determine *sulcus centralis* for surgical procedures around central region.<sup>[16]</sup> It is observed that there are also developmental differences between girls and boys in addition to the differences between age groups in terms of brain development.<sup>[17]</sup>

## Conclusion

The morphometric data obtained as a result of this study, which shows the impact of age and gender on brain development in normal child central region, shall help planning of sensitive surgical operations to be applied to the third ventricle and the brain's central region in children.

## Acknowledgements

We would like to thank Cumhuriyet University, faculty of Medicine, Department of Radiology.

## References

1. Ardeshiri A, Ardeshiri A, Wenger E, Holtmannspötter M, Winkler PA. Surgery of the anterior part of the frontal lobe and of the central region: Normative morphometric data based on magnetic resonance imagin. *Neurosurg Rev* 2006;29:313-20.
2. Erturk M, Kayacioğlu G, Ozer MA, Ozgur T. Morphometry of anterior third ventricle as a Guide for the Transcallosal-Interforneal Approach. *Neurol Med Chir* 2004;44:288-93.
3. Giedd JN, Stockman M, Weddle C, Liverpool M, Alexander-Bloch A, Wallace GL, et al. Anatomic magnetic resonance imaging of the developing child and adolescent brain and effects of genetic variation. *Neuropsychol Rev* 2010;20:349-61.
4. Sowell ER, Trauner DA, Gamst A, Jernigan TL. Development of cortical and subcortical brain structures in childhood and adolescence: A structural MRI study. *Dev Med Child Neurol* 2002;44:4-16.
5. Krombach GA, Spetzer U, Rohde V, Gilsbach JM. Intraoperative localization of functional regions in the sensorimotor cortex by neuronavigation and cortical mapping. *Comput Aided Surg* 1998;3:64-73.
6. Olesen PJ, Nagy Z, Westerberg H, Klingberg T. Combined analysis of DTI and fMRI data reveals a joint maturation of white and grey matter in a fronto-parietal network. *Brain Res Cogn Brain Res* 2003;18:48-57.
7. Lenroot RK, Gogtay N, Greenstein DK, Wells EM, Wallace GL, Clasen LS, et al. Sexual dimorphism of brain developmental trajectories during childhood and adolescence. *Neuroimage* 2007;36:1065-73.
8. Kwong KK, Chesler DA. Early time points perfusion imaging: Theoretical analysis of correction factors for relative cerebral blood flow estimation given local arterial input function. *Neuroimage* 2011;57:182-9.
9. Durston S, Hulshoff Pol HE, Casey BJ, Giedd JN, Buitelaar JK, van Engeland H. Anatomical MRI of the developing human brain: What have we learned? *J Am Acad Child Adolesc Psychiatry* 2001;40:1012-20.
10. Kennedy DN, Haselgrove C, McLnerney S. MRI-based morphometric of typical and atypical brain development. *Ment Retard Dev Disabil Res Rev* 2003;9:155-60.
11. Wilke M, Schmithorst VJ, Holland SK. Assessment of spatial normalization of whole-brain magnetic resonance images in children. *Hum Brain Mapp* 2002;17:48-60.
12. Giedd JN, Castellanos FX, Rajapakse JC, Vaituzis AC, Rapoport JL. Sexual dimorphism of the developing human brain. *Prog Neuropsychopharmacol Biol Psychiatry* 1997;21:1185-201.
13. Winkler PA, Weis S, Büttner A, Raabe A, Amiridze N, Reulen HJ. The transcallosal interforneal approach to the third ventricle: Anatomic and microsurgical aspects. *Neurosurgery* 1997;40:973-81.
14. Giedd JN. Structural magnetic resonance imaging of the adolescent brain. *Ann NY Acad Sci* 2004;1021:77-85.
15. Talairach J, Tournoux P. Co-planar stereotaxic atlas of the human brain. Stuttgart, Germany: Thieme Publishers; 1988. p. 1-4.
16. Pujol J, Conesa G, Deus J, Lopez-Obarrio L, Isamat F, Captevilla A. Clinical application of functional magnetic resonance imaging in presurgical identification of the central sulcus. *J Neurosurg* 1998;88:863-9.
17. Leonard CM, Towler S, Welcome S, Halderman LK, Otto R, Eckert MA, et al. Size matters: Cerebral volume influences sex differences in neuroanatomy. *Cereb Cortex* 2008;18:2920-31.

How to cite this article: ???

Source of Support: Nil, Conflict of Interest: None declared.