

ORIGINAL ARTICLE

Urethrocutaneous fistula complicating circumcision in children

SO Ikuero, MJ Bioku, OA Omisanjo, JO Esho

Urology Division, Department of Surgery, Lagos State University College of Medicine, Ikeja-Lagos, Nigeria

Abstract

Introduction: Urethrocutaneous fistula is an unusual but preventable complication following circumcision. We describe our experience with the management of this potentially challenging condition.

Materials and Methods: We reviewed all patients who had surgical repair of post-circumcision urethrocutaneous fistula from September 2008 to September 2011 in our institution.

Results: Thirty-one cases presenting at age 4 weeks to 12 years were managed. Twenty-six (84%) had had circumcision in the neonatal period. Most circumcisions (81%) were carried out by nurses using the dissection method and without anesthesia. In 30 (97%) patients, the fistula was single. The fistula size ranged from 1.5 to 12 mm in the widest diameter. Modified Mathieu's flap procedure was used in the repair of 18 (56%) fistulae and 9 (28%) fistulae were by simple closure. Recurrence of the fistula was seen in 8 (25%) patients with large fistulae > 5 mm in diameter. The recurrent fistulae were small and were repaired by simple closure.

Conclusion: Urethrocutaneous fistula post-circumcision is frequently seen in our practice and the surgical repair is challenging and associated with high recurrence rate in large fistulae. This preventable condition may be avoided by proper education and training of circumcisers.

Key words: Circumcision, complication, repair, urethrocutaneous fistula

Date of Acceptance: 22-May-2013

Introduction

Circumcision is the most common operation performed in the world.^[1,2] An estimated one in three male population are circumcised globally.^[3,4] The circumcision rate in a study done in Ibadan, Nigeria, was put at 87%^[5] mainly on cultural and religious grounds. Recently, male circumcision has generated public health interest because of randomized controlled trials which have shown that adult circumcision reduces the risk of acquiring HIV infection by about 60%.^[6-8] Thus, the Joint United Nations Programme on HIV/AIDS (UNAIDS) and the World Health Organization (WHO) have recommended considering adult and neonatal circumcision as a longer-term HIV prevention strategy.^[3]

Several complications have been reported following circumcision in children.^[5,9-13] Urethrocutaneous fistula (UCF) following circumcision in children is not a commonly reported complication.^[14-19] In recent times, we have seen increasing number of children presenting with UCF complicating circumcision. Circumcision is often thought of as a minor procedure and therefore, left for relatively inexperienced health personnels. The result of this would be complications such as UCF. The repair of urethral fistula could be quite challenging and there are only few reports on this subject. This study was therefore aimed at describing the cases of post-circumcision UCF seen in our institution and how they were treated.

Address for correspondence:

Dr. S. Odunayo Ikuero,
Urology Division, Department of Surgery,
Lagos State University College of Medicine,
1-5 Oba Akinjobi Way, Ikeja.
E-mail: kerowq@yahoo.com

Access this article online

Quick Response Code:



Website: www.njcponline.com

DOI: 10.4103/1119-3077.127422

PMID: 24553021

Materials and Methods

All cases of UCF following circumcision that presented at our urology unit between September 2008 and September 2011 and had surgical repair were reviewed, retrospectively. Information obtained included the patients' ages at circumcision and at presentation to our facility, method of circumcision, the circumcisers, the number of fistulae, their locations and sizes, the techniques of repair and the post-operative outcome. The data were analyzed using the IBM SPSS 19.0 for window.

Results

Thirty-one patients had operative repair for UCF and their record were available for review. Table 1 summarized the clinical characteristics of the 31 patients. The age of the patients at the time of presentation with UCF ranged from 4 weeks to 12 years with the average age of 4.7 years.

All 31 patients had circumcision for cultural and religious reasons. Twenty-six (84%) patients had circumcision in the neonatal period while five (16%) were circumcised in infancy after neonatal period. All the patients had the dissection method of circumcision without the use of any form of circumcision device. Twenty-five (81%) patients had circumcisions performed by nurses,

four (13%) by doctors, and two (6%) by traditional circumciser.

Single UCF was found in 30 (97%) patients and one (3%) patient had two fistulae. The size of the fistulae ranged from 1.5 to 12.0 mm in the widest diameter. Nine (28%) fistulae were <2 mm, 8 (25%) were 2–5 mm and 15 (47%) were >5 mm in the widest diameter. Twenty-three (72%) fistulae were located in the coronal region, seven (22%) were in the distal part of the penile shaft and two (6%) were located in the mid penile shaft.

The method of repair was determined by the size and location of the fistulae. Simple closure was achieved in 9 (28%) fistulae [Figure 1]. These fistulae were all <2 mm in widest diameter and 6 of them were located at the corona, 2 at the distal penile shaft and 1 at the mid penile shaft. Conversion of coronal fistula to 'coronal hypospadias' followed by Snodgrass repair was carried out in 5 (16%) patients [Figure 2]. These coronal fistulae were all ≤5 mm in widest diameter and had flimsy and narrow tissue bridge between the fistula and the external urethral meatus. Modified Mathieu's repair was done in 18 (56%) patients. Twelve coronal fistulae which were >5 mm in largest diameter were repaired by this method, which also involved the excision of the flimsy and narrow tissue bridge between the fistula and the external urethral meatus. Five distal penile fistulae and one proximal penile fistula were also repaired using the modified Mathieu's flap method. The modified Mathieu's repair involves using a peri-fistula based flap to close the fistula thereby substituting the urethra ventrally with penile skin [Figure 3].^[20]

In all cases, 5/0 polyglycolic acid sutures were used and the closures were carried out in three layers: Closure of fistula, dartos muscle layer closure over the first layer, and then skin closure. Following the repairs, suprapubic diversion of urine was done in 13 (42%) patients (10 Mathieu's repair,

Table 1: Clinical characteristics of patients with post-circumcision urethrocutaneous fistula

Clinical variable	Frequency	(%)
Total patients	31	(100)
Circumcisers		
Nurse	25	(81)
Doctor	4	(13)
Traditionalist	2	(6)
Age at circumcision		
Neonate	26	(84)
Infancy	5	(16)
Location of fistulae		
Corona	23	(72)
Distal penile shaft	7	(22)
Mid penile shaft	2	(6)
Number of fistulae	30	(97)
One	1	(3)
Two		
Size of fistula (mm)		
<2	9	(28)
2-5	8	(25)
>5	15	(47)
Fistula surgery		
Simple closure	9	(28)
Modified Snodgrass repair	5	(16)
Modified Mathieu's repair	18	(56)
Fistula recurrence	8	(25)

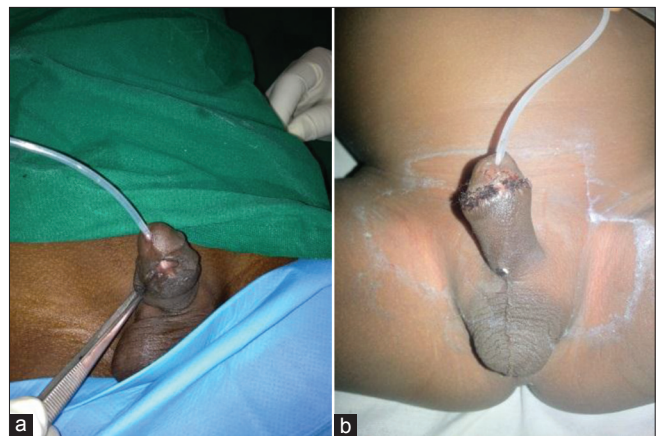


Figure 1: (a) A small coronal urethrocutaneous fistula, (b) same patient 10 days after repair just prior to the removal of the urethral stent with a good cosmetic outcome

2 Snodgrass repair and 1 simple closure repair). Fistula recurrence was recorded in eight (26%) patients, seven of whom had closure of fistula > 5 mm using the Mathieu's method and one had closure using Snodgrass method. Among the patients with recurrent fistula, three have had post-operative suprapubic urinary diversion. No recurrence was recorded among patients who had simple closure of the fistulae.

Discussion

Circumcision is a simple surgical procedure, but like any other operation, can result in distressing complications including UCF.^[5,9-17] Successful repair of UCF could be quite challenging. Although, religious and cultural circumcisions were performed in the neonatal period, most children with urethral fistula presented after the neonatal age. This delay in presentation was also reported elsewhere.^[13]

All the cases studied had been circumcised by surgical dissection often without anesthesia as described by the mothers. Thus, the patients might be uncooperative intraoperatively resulting in hasty clamping of urethral wall alongside the frenular vessels while securing hemostasis

or in some cases inadvertent scalpel injury to the urethral wall. The consequent fistula is synonymous with this method as reported in some studies.^[20-23] On the other hand, some workers have proposed that circumcision with plastibell device is simple and complications including UCF are uncommon.^[24,25] However, proximal migration of the plastibell ring leading to UCF has also been reported.^[26] The practice of circumcision without anaesthesia should be discouraged as neonates do perceive pain^[27] and the risk of injury leading to UCF would be significantly increased. The most important factor in UCF is poor surgical skill especially when circumcision is carried out by untrained health personnel. In majority of the cases we reviewed, circumcision had been carried out by nurses. Okeke *et al.*,^[5] also found a higher circumcision complication rate in Ibadan with the nurses. However, we think this is probably because most circumcision in our city is performed by nurses. Therefore, the emphasis should be on education and training of circumcisers so as to avoid this entirely preventable condition.

Whatever the etiology of UCF following circumcision, it remains a serious concern of paediatric urologists who are the final arbiters in the course of its care. Once the diagnosis is made, we select the appropriate method to repair it. The choice of technique depends on the location, size, and number of fistulae and availability of soft tissue for reinforcement of the repair. Usually, multilayered tension-free closure is favored.^[28] At surgery, it should be noted that circumcised phallus has little free skin particularly in the frenular area. There is usually also peri-fistula scarring. Simple closure was indicated in small fistulae <2 mm widest diameter [Figure 1]. Snodgrass tubularized incised plate urethroplasty was used for coronal fistula of size ≤ 5 mm with narrow skin bridge between the fistula and the external urethral meatus [Figure 2]. The narrow skin bridge was excised to convert it to a coronal hypospadias before the repair. It was practically not possible to achieve a multilayer fistula closure without excising the narrow skin bridge. In large fistulae >5 mm, simple closure or Snodgrass repair would result in repair under tension and the possibility of a future urethral stricture and therefore such fistulae were

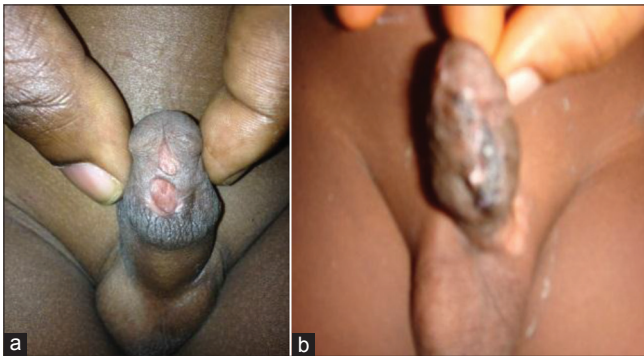


Figure 2: (a) a distal penile fistula of about 5mm in diameter and a flimsy skin bridge between the external urethral meatus and the fistula. After excising the skin bridge, the urethral plate was incised and tubularized and a layer of dartos and skin closed over it. (b) is same patient 4 weeks after the repair with a good cosmetic and functional outcome

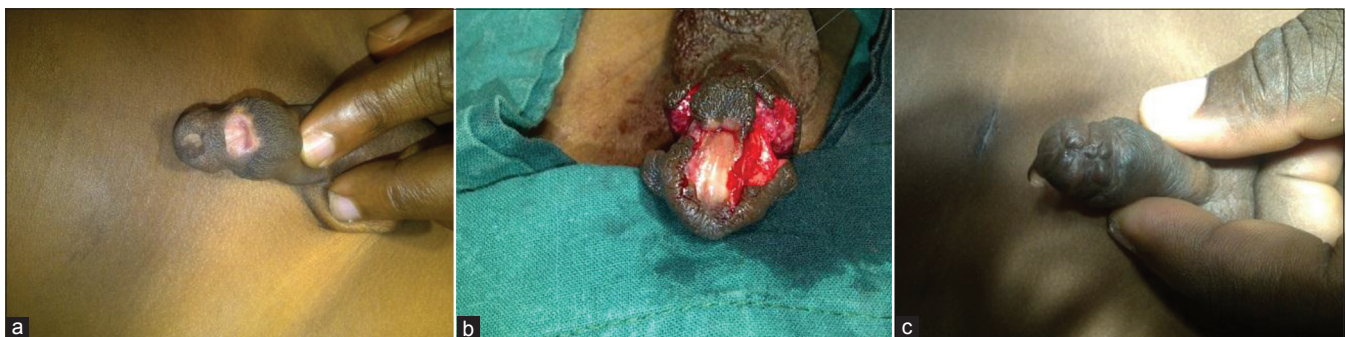

Figure 3: (a) A large urethrocutaneous fistula and peri-fistula scarring. (b) Peri-fistula based Mathieu's flap after excision of the skin bridge, (c) Same patient 3 months after the repair with a good cosmetic and functional outcome and good urine flow

repaired using a modified Matthieu's peri-fistula based flap [Figure 3]. Suprapubic urinary diversion was used at the discretion of the surgeons. The current data is, however, too small to determine if suprapubic diversion significantly influenced the result after repair. The approach to the only multiple urethral fistulae seen was to clearly canulate and demonstrate the fistulous tracts using methylene blue. The tracts were traced to where they combined to form a solitary internal opening at the subcoronal region of the urethra and it was easy to close the urethra over a silastic Foley's catheter without tension. In some cases, as has been reported, the diseased part may have to be excised, urethra mobilized and end-to-end anastomosis performed.^[29] In a recent publication, Osifo *et al.*,^[19] determined the methods of repair by preoperatively categorizing post-circumcision related injury. Although the categorization may be arbitrary, their post-operative result was good. In our series it would be practically impossible to find sufficient dartos layer, subcutaneous tissue and skin to be mobilized to cover a primarily closed large urethral fistula without tension. Such large fistulae in our series underwent substitution urethroplasty using a Matthieu's flap.

In spite of the meticulous care adopted during the surgical repair, recurrence was high. This is usually related to poor vascularity due to extensive peri-fistula scarring, large fistula size, and wound infection. Small to moderate size fistulae < 5-mm diameter rarely recur after initial repair. When the larger fistulae recur, they are usually much smaller in size and suitable for second stage simple closure.

Conclusions

Urethrocutaneous fistula following circumcision is potentially challenging to repair with significant recurrence rate among patients with large fistula size. Risk-reduction strategies including education and adequate training of all practitioners who are involved in circumcision may help reduce the occurrence of this condition.

References

- Williams N, Kapila L. Complications of circumcision. *Br J Surg* 1993;80:1231-6.
- Yegane RA, Kheirollahi AR, Salehi NA, Bashashati M, Khoshdel JA, Ahmadi M. Late complications of circumcision in Iran. *Pediatr Surg Int* 2006;22:442-5.
- WHO/UNAIDS: New data on male circumcision and HIV prevention: Policy and programme implications: Conclusions and recommendations. UNAIDS;2007. Available from: http://www.data.unaids.org/pub/Report/2007/mc_recommendations_en.pdf. [Last assessed on 2013 Mar 1].
- WHO/UNAIDS: Male circumcision: Global trends and determinants of prevalence, safety and acceptability. World Health Organization;2008. Available from: http://www.unaids.org/en/media/unaids/contentassets/dataimport/pub/report/2007/jc1360_male_circumcision_en.pdf. [Last assessed on 2013 Mar 1].
- Okeke LI, Asinobi AA, Ikuerowo OS. Epidemiology of complications of male

- circumcision in Ibadan, Nigeria. *BMC Urol* 2006;6:21.
- Gray RH, Kigozi G, Serwadda D, Makumbi F, Watya S, Nalugoda F, *et al.* Male circumcision for HIV prevention in men in Rakai, Uganda: A randomised trial. *Lancet* 2007;369:657-66.
- Bailey RC, Moses S, Parker CB, Agot K, Maclean I, Krieger JN, *et al.* Male circumcision for HIV prevention in young men in Kisumu, Kenya: A randomised controlled trial. *Lancet* 2007;369:643-56.
- Auvert B, Taljaard D, Lagarde E, Sobngwi-Tambekou J, Sitta R, Puren A. Randomized, controlled intervention trial of male circumcision for reduction of HIV infection risk: The ANRS 1265 Trial. *PLoS Med* 2005;2:e298.
- Ben Chaim J, Livne PM, Binyamini J, Hardak B, Ben-Meir D, Mor Y. Complications of circumcision in Israel: A one year multicenter survey. *Isr Med Assoc J* 2005;7:368-70.
- Wiswell TE, Geschke DW. Risks from circumcision during the first month of life compared with those for uncircumcised boys. *Pediatrics* 1989;83:1011-5.
- Manji KP. Circumcision of the young infant in a developing country using the Plastibell. *Ann Trop Paediatr* 2000;20:101-4.
- O'Brien TR, Calle EE, Poole WK. Incidence of neonatal circumcision in Atlanta, 1985-1986. *South Med J* 1995;88:411-5.
- Osifo OD, Oriafio IA. Circumcision mishaps in Nigerian children. *Ann Afr Med* 2009;8:266-70.
- Lackey JT, Mannion RA, Kerr JE. Urethral fistula following circumcision. *JAMA* 1968;206:2318.
- Limaye RD, Hancock RA. Penile urethral fistula as a complication of circumcision. *J Pediatr* 1968;72:105-6.
- Redman JF. Rare penile anomalies presenting with complication of circumcision. *Urology* 1988;32:130-2.
- Kaplan GV. Complications of circumcision. *Urol Clin North Am* 1983;10:543-9.
- Ademuyiwa AO, Bode CO. Complications of neonatal circumcision: Avoiding common pitfalls in a common procedure. *Afr J Paediatr Surg* 2009;6:134-6.
- Osifo OD, Odion-Obomhense H, Osagie TO. Repair-oriented categorization of circumcision urethral injury in Benin city, Nigeria. *J Pediatr Urol* 2013;9:206-11.
- Baskin LS, Canning DA, Snyder HM 3rd, Duckett JW Jr. Surgical repair of urethral circumcision injuries. *J Urol* 1997;158:2269-71.
- Sherman J, Borer JG, Horowitz M, Glassberg KI. Circumcision: Successful glanular reconstruction and survival following traumatic amputation. *J Urol* 1996;156:842-4.
- Yilmaz AF, Sarikaya S, Yildiz S, Buyukalpelli R. Rare complication of circumcision: Penile amputation and reattachment. *Eur Urol* 1993;23:423-4.
- Gluckman GR, Stoller ML, Jacobs MM, Kogan BA. Newborn penile glans amputation during circumcision and successful reattachment. *J Urol* 1995;153:778-9.
- Lazarus J, Alexander A, Rode H. Circumcision complications associated with the Plastibell device. *S Afr Med J* 2007;97:192-3.
- Gee WF, Ansell JS. Neonatal circumcision: A ten-year overview: With comparison of the Gomco clamp and the Plastibell device. *Pediatrics* 1976;58:824-7.
- Bode CO, Ikhisemiojie S, Ademuyiwa AO. Penile injuries from proximal migration of the Plastibell circumcision ring. *J Pediatr Urol* 2010;6:23-7.
- Bellieni CV, Buonocore G, Nenci A, Franci N, Cordelli DM, Bagnoli F. Sensorial saturation: An effective analgesic tool for heel-prick in preterm infants: A prospective randomized trial. *Biol Neonate* 2001;80:15-8.
- Lau JT, Ong GB. Subglandular urethral fistula following circumcision: Repair by the advancement method. *J Urol* 1981;126:702-3.
- Agrawal A, Parelkar S, Shah H, Sanghvi B, Joshi M, Mishra P. Multiple circumferential urethrocutaneous fistulae: A rare complication of circumcision. *J Pediatr Urol* 2009;5:240-2.

How to cite this article: Ikuerowo SO, Bioku MJ, Omissano OA, Esho JO. Urethrocutaneous fistula complicating circumcision in children. *Niger J Clin Pract* 2014;17:145-8.

Source of Support: Nil, **Conflict of Interest:** None declared.