

**ORIGINAL ARTICLE**

# Treatment of unilateral giant fibroadenoma by breast reduction skin incision: The inverted “T” technique

JU Achebe, GE Njeze, OR Okwesili

Department of Surgery, University of Nigeria Teaching Hospital, Enugu, Nigeria

## Abstract

**Background:** Giant fibroadenoma (GFA) has been defined as fibroadenoma greater than 5 cm in its widest diameter and/or weighing more than 500 g. A benign lesion, its size also raises the possibility of malignancy requiring differentiation from a malignant breast disease. When unilateral GFA presents with a severe breast asymmetry, due to its size, it is not correctable by simple enucleation alone. Postoperative asymmetry from volume and ptosis disparity results, which needs to be addressed at the primary surgery. The inverted “T” technique, which is effective in volume reduction and ptosis correction in breast hypertrophy, can be applied in the treatment of unilateral GFA.

**Aim:** This is a retrospective review of all GFA treated by inverted “T” method.

**Materials and Methods:** A retrospective review was carried out on all patients with GFA treated by inverted “T” skin pattern method over a period of 20 years (January 1988 to December 2007). The procedures were carried out at the University of Nigeria Teaching Hospital and the National Orthopedic Hospital, Enugu. Information, which included patients’ demographics, pre-operative assessment, operative findings and outcome of surgery were obtained from the case files of the patients. The degree of ptosis was recorded for each patient. Diagnosis of GFA was made after clinical evaluation and pre-operative tissue biopsy. Immediate results of treatment were based on the patients’ satisfaction, visual assessment of symmetry of size of breasts, correction of ptosis and position of nipple areola complex (NAC).

**Results:** A total of 27 patients underwent inverted “T” technique for excision of GFA in their breasts. Their average age was 17.5 years (range 12-25 years) delay in presentation ranged from 2 months to 15 months. In 16 patients (59.2%), the left breast was involved in GFA whilst the tumor occurred on the right breast in 11 (40.7%). The tumor weighed on the average 1500 g (range 655-2200 g). Average diameter of the tumor was 15 cm (range 12-20 cm). All quadrants of the breasts were involved at presentation. The inferior glandular pedicle bearing the NAC was used in all patients. The length of the pedicle ranged from 8 cm to 14 cm whilst the width ranged from 6 cm to 8 cm. Lactation was reported by three patients who went on to successfully breast feed. Complications were minimal. Most were minor wound healing problems and minor breast asymmetry. Epidermolysis in 2, hypertrophic scar in 6, minor breast asymmetry in 3 and delayed healing at the “T” junction in the inframammary fold in 4 were the common complications. All patients were satisfied with the result obtained.

**Conclusion:** In GFA with a significant breast asymmetry, excision through inverted “T” technique was successful in achieving postoperative symmetry with the opposite breast in these patients. Complications were minimal.

**Key words:** Breast reduction, giant fibroadenoma, inverted “T” technique

**Date of Acceptance:** 19-Jun-2013

## Introduction

Fibroadenoma is a common benign tumor of the adolescent and young adult female breast.<sup>[1-3]</sup> When it is of small size it does not usually produce breast asymmetry. When

excision biopsy is indicated placement of the incision will depend upon the location and the size of the lesion and

### Address for correspondence:

Dr. JU. Achebe,  
Department of Surgery University of Nigeria Teaching Hospital,  
P. O. Box. 769, Enugu, Nigeria.  
E-mail: juachebe@yahoo.com

### Access this article online

#### Quick Response Code:



**Website:** [www.njcponline.com](http://www.njcponline.com)

**DOI:** 10.4103/1119-3077.122835

**PMID:** \*\*\*\*\*

infra-mammary and circumareolar incisions are favored from esthetic point of view.<sup>[4,5]</sup> Giant fibroadenoma (GFA) on the other hand are those fibroadenomas that are larger than 5 cm and or weigh more than 500 g<sup>[2,6]</sup> They are not as common as small fibroadenomas.<sup>[4]</sup> However, GFA are known to be the most common cause of unilateral breast enlargement in the adolescent.<sup>[7]</sup> Some large unilateral GFA do produce significant breast asymmetry, which are not always corrected by simple enucleation.<sup>[2]</sup> Various method to address this post-operative asymmetry include reliance on post-operative soft-tissue shrinkage, use of breast implant or tissue expander.<sup>[2,8-11]</sup> The inverted “T” skin technique with inferior glandular pedicle that nourishes the nipple areola complex (NAC) was introduced by Robbins for breast reduction in breast hypertrophy.<sup>[12]</sup> With a slight modification, we applied this method to the treatment of large unilateral GFA with a significant asymmetry. Our 20 year experience with this technique in the treatment of unilateral GFA is presented.

## Materials and Methods

The case files of all patients with unilateral GFA who were treated by inverted “T” skin technique from January 1988 to December 2007 were obtained from the medical records department. Their age, marital status, delays in presentation as well previous breast diseases were noted. The degree of ptosis on the affected breasts were measured and classified by Regnault technique.<sup>[13]</sup> The difference in the vertical plane between the two nipple position with patient standing was also measured and termed the ptotic difference (PD). Operative recordings included the size and weight of tumor, its location in the breast and the dimensions of the NAC bearing flap. The complications of surgery as well as length of follow-up were noted.

### Operative procedure

The skin markings is similar to that for reduction mammoplasty using inferior pedicle flap and inverted T skin patterns as described by Robbins.<sup>[12]</sup> Measurements and markings were performed with patient standing. The following modifications are important.

- The distance from the supra-sternal notch to the new nipple position on the breast meridian is determined by the distance from the supra-sternal notch to the contra lateral nipple
- The difference in the vertical plane between the nipple position and that of the contra lateral breast was measured in all patients. This length was designated the PD
- The distance between the lower border of the areola and infra-mammary crease of the contra lateral breast determines the height of the medial and lateral flaps. This was kept at 4.00-4.5 cm
- The diameter of the new areola should be slightly larger

than the contra lateral side to allow for shrinkage.

- De-epithelization of areas to be buried under the flaps should be carried out before tumor enucleation
- Medial and lateral dermoglandular resections were not carried out. Rather the skin was de-epithelialized and invaginated to increase bulk
- The base of NAC flap should be as wide as possible
- All tumors were enucleated
- Figure 1 illustrates the stages in the surgical procedure.

## Results

There were 27 patients who underwent inverted “T” technique for unilateral GFA. Their average age was 17.5 years (range 12-25 years). Two (7.4%) were married at the time of surgery. In 16 patients (59.2%), the left breast was involved in GFA whilst the tumor occurred on the right breast in 11 (40.7%). Delay in presentation ranged from 2 months to 15 months with 20 patients (74%) reporting within 4 months of noticing the lesion. Breast asymmetry and rapid growth were the main reasons for seeking treatment in all patients, but in 15 patients (55.5%) the possibility of malignancy was additional concern. The difference between the nipple positions in the vertical plane ranged from 4 cm to 11 cm. Furthermore, 8 (29.6%) were grade 2 (moderate) whilst 19 (70.4%) were grade 3 (severe) ptosis. The tumor weighed on the average 1500 g (range 655-2200 g). Average size of the tumor was 15 cm (range 12-20 cm). All quadrants of the breast were involved at presentation. The length of inferior glandular pedicle bearing the NAC ranged from 8 cm to 14 cm whilst the width ranged from 6 cm to 8 cm. Lactation was reported by 3 patients who went on to successfully breast feed. Complications encountered are set out in Table 1. Most are minor wound healing problems and minor breast asymmetry. Epidermolysis,<sup>[2]</sup> hypertrophic scar,<sup>[4]</sup> minor breast asymmetry<sup>[3]</sup> and delayed healing at the “T” junction<sup>[4]</sup> were the common complications. All patients were satisfied with the result at follow-up. Few representative results are shown in Figure 2.

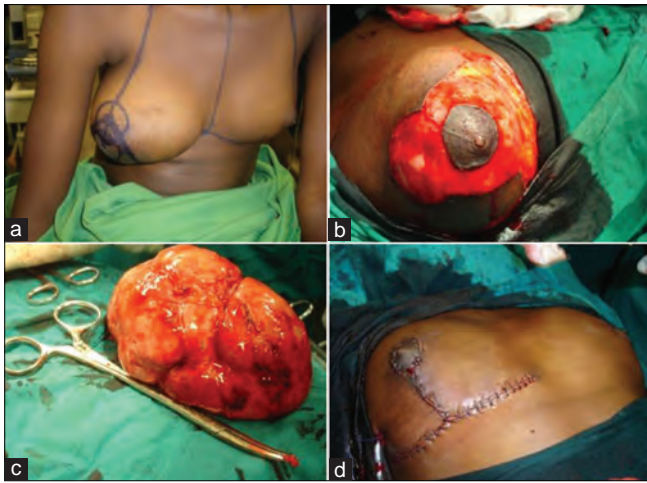
## Discussion

Fibroadenoma is a common benign tumor of the teenage, adolescent and young adult female breast.<sup>[1,2,3]</sup> It is also seen more in the blacks.<sup>[7]</sup> When it is of small size it does not usually lead to breast asymmetry. The main consideration would be to rule out malignancy which is usually uncommon in this

**Table 1: Post operative complications**

Complications	n (%)
Epidermolysis of NAC	2 (7.40)
Minor breast asymmetry	3(11.11)
Hypertrophic scar	4(14.81)
Delayed wound healing at the T junction	4(14.81)

NAC=Nipple areola complex



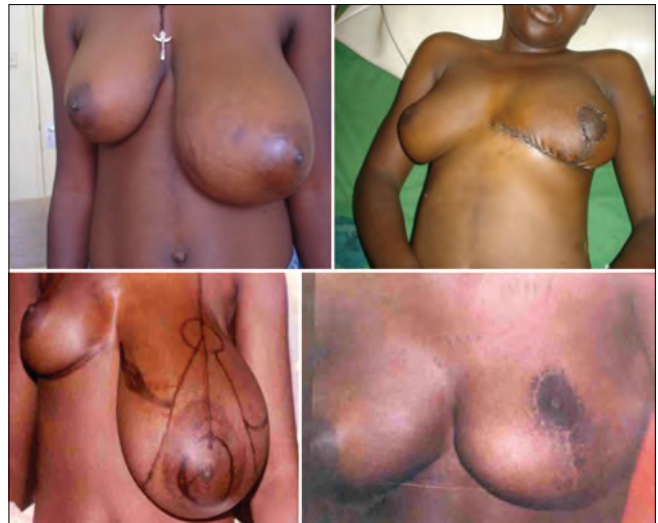
**Figure 1:** (a) Skin markings for inverted “T” procedure (B) De-epithelialisation of area to be buried (C) Excised tumor (D) Inverted T pattern skin closure

age group. A combination of history, physical examination and tissue biopsy will make the diagnosis in most patients. Placement of incision in doing the excision biopsy becomes an important aesthetic consideration so as to minimize and conceal the scar as much as possible. Depending upon the size and location of the tumor, infra-mammary fold or circumareolar incisions are favored.<sup>[4,5]</sup>

A variant of fibroadenoma, GFA is less common than small fibroadenomas;<sup>[4]</sup> however, GFA is the most common benign lesion causing unilateral breast enlargement in young patients.<sup>[4,7]</sup> Unlike the small fibroadenoma its growth can be progressive leading to enormous size. This was the finding in our series since the average size and weight of the tumor were 15 cm and 1500 g respectively. The size and progression of GFA not only produce significant breast deformity, but also raise the possibility of malignancy with its attendant psychological implication for the patient. Phyllodes breast tumor, which can also be seen in this age range of patients, should be differentiated from GFA. Although the treatment of both is surgical, the treatment plan will be based on diagnosis. Since history and physical examination may not always differentiate the two, pre-operative biopsy is necessary to confirm diagnosis

There is no consensus on the best surgical approach for the management of GFA with significant breast asymmetry. Some feel that enucleation through the infra-mammary incision was adequate and the postoperative deformity will correct by skin and subcutaneous shrinkage over months or years.<sup>[8]</sup> Others tried to correct the deformity immediately by tissue expanders that are slowly deflated, breast implants or mastopexy.<sup>[2,9-11]</sup>

Not all GFA can be adequately treated by simple enucleation and reliance on soft-tissue shrinkage for symmetry with the opposite breast.<sup>[2]</sup> It was therefore important to select those



**Figure 2:** Pre and post operative results of two representative cases

GFA where symmetry with the normal breast cannot be achieved by enucleation alone. Severe ptosis and PD of 6 cm and above became our guide in the selection of those cases suitable for inverted “T” technique. However, a prospective randomized study involving more cases will be required to confirm our findings.

Our goal in the treatment of GFA was complete removal of the tumor whilst preserving the normal form and function of the breast. Symmetry is a most important aspect of normal form in bilateral structures like the breast. The inverted “T” technique provides easy access for tumor enucleation and also adjusts the redundant breast skin envelope and the position and size of the NAC to maintain symmetry with the normal breast. An important aspect of breast function is lactation. Although three patients who were seen during the follow-up period became pregnant and achieved lactation with breast feeding, it is pertinent to note that most of our patients were teenagers who were unmarried at the time of surgery. The inverted “T” technique maintained the NAC attached to the ducts and the glandular tissue. It is therefore expected that like in breast reduction for mammary hypertrophy, this technique will not adversely affect the potential for lactation and breast feeding.<sup>[14]</sup> A few case reports in the past had employed this technique successfully to treat unilateral GFA with a significant asymmetry.<sup>[2,9,15]</sup> We confirm their findings in these our series of patients. Our complications were minor and have to do with wound healing problems and minimal size asymmetry. It is interesting that although all our patients were blacks, there was no case of keloids and only few cases of hypertrophic scars. It is important to counsel patients about this.

## Conclusion

Although some GFAs can be treated by excision through the infra-mammary fold or circumareolar route, such methods

may not correct asymmetry when there is a significant size difference and PD with the contralateral breast. The inverted "T" technique has some advantages in those situations. It provides easy access for tumor enucleation and facilitates volume and ptotic correction whilst restoring symmetry with the normal breast. The technique may not preclude lactation in the future and the resulting scars were not objectionable to our patients.

## References

1. Chang DS, McGrath MH. Management of benign tumors of the adolescent breast. *Plast Reconstr Surg* 2007;120:13e-9.
2. McGrath MH. Benign tumors of the teenage breast. *Plast Reconstr Surg* 2000;105:218-22.
3. Irabor DO, Okolo CA. Outcome of one hundred and forty-nine consecutive breast biopsies in Ibadan, Nigeria. *Breast Dis* 2011;33:109-14.
4. Park CA, David LR, Argenta LC. Breast asymmetry: Presentation of giant fibroadenoma. *Breast J* 2002;8:45-6.
5. Biggers BD, Lamont JP, Etufugh CN, Knox SK. Inframammary approach for removal of giant juvenile fibroadenomas. *J Am Coll Surg* 2009;208:e1-4.
6. Kuusk U. Multiple giant fibroadenomas in an adolescent female breast. *Can J Surg* 1988;31:133-4.
7. Musio F, Mozingo D, Otchy DP. Multiple, giant fibroadenoma. *Am Surg* 1991;57:438-41.
8. Jacob MM. Application of reduction mammoplasty in treatment of giant breast tumour. *Br J Plast Surg* 2000;53:265-6.
9. Yamamoto Y, Sugihara T. Application of reduction mammoplasty in treatment of giant breast tumour. *Br J Plast Surg* 1998;51:109-12.
10. Hoffman SH. Giant fibroadenoma of the breast: Immediate reconstruction following excision. *Br J Plast Surg* 1978;31:170-2.
11. Kamei Y, Torii S. Natural skin reduction and breast recovery using a tissue expander after enucleation of a giant breast tumour. *Scand J Plast Reconstr Surg Hand Surg* 2000;34:383-5.
12. Robbins TH. A reduction mammoplasty with the areola-nipple based on an inferior dermal pedicle. *Plast Reconstr Surg* 1977;59:64-7.
13. Regnault P. Breast ptosis. Definition and treatment. *Clin Plast Surg* 1976;3:193-20.
14. Cruz NI, Korchin L. Lactational performance after breast reduction with different pedicles. *Plast Reconstr Surg* 2007;120:35-40.
15. Ugburo AO, Olajide TO, Fadeyibi IO, Mofikoya BO, Lawal AO, Osinowo AO. Differential diagnosis and management of giant fibroadenoma: Comparing excision with reduction mammoplasty incision and excision with inframammary incision. *J Plast Surg Hand Surg* 2012;46:354-8.

**How to cite this article:** Achebe JU, Njeze GE, Okwesili OR. Treatment of unilateral giant fibroadenoma by breast reduction skin incision: The inverted "T" technique. *Niger J Clin Pract* 2014;17:43-6.

**Source of Support:** Nil, **Conflict of Interest:** None declared.

### Announcement

#### Android App



A free application to browse and search the journal's content is now available for Android based mobiles and devices. The application provides "Table of Contents" of the latest issues, which are stored on the device for future offline browsing. Internet connection is required to access the back issues and search facility. The application is compatible with all the versions of Android. The application can be downloaded from <https://market.android.com/details?id=comm.app.medknow>. For suggestions and comments do write back to us.