

ORIGINAL ARTICLE

Adolescent and adult cleft lip and palate, in Ile-Ife, Nigeria

AO Oladele, JK Olabanji, OO Awe¹Departments of Surgery, Obafemi Awolowo University, Ile-Ife, ¹Irrua Specialist Teaching hospital, Irrua, Nigeria

Abstract

Introduction: Congenital cleft lip and palate (CLP) defects usually present in childhood, especially in places with available and affordable care. In Nigeria, their incidence is low but late presentation in Adult life have been reported. This article aims at reviewing adolescent and adult CLP patients in our center, with the advent of free and available care, and to document the patterns and management outcomes of these patients as an addition to existing literature on the subject of adult CLP.

Materials and Methods: A retrospective review of adolescent and adult CLP patients managed from May 2006 to April 2010. Demographic data as well as clinical information were retrieved from the hospital records and include the type of cleft deformity, surgical intervention prior to presentation, the type of surgery performed and postoperative outcomes. Some pertinent clinical photos were also reviewed.

Results: Adolescent and adults constituted 24% of the 137 patients, their age ranged from 13 to 76 years, with a mean, median and modal age of 28, 22 and 20 years respectively. Unilateral cleft of primary palate was commonest with female preponderance. Most never had surgery, others desired revision surgery or secondary procedures. The outcomes were satisfactory in the 37 procedures performed on 33 patients.

Conclusion: A relatively high ratio of adolescent and adult clefts is observed. Most of them have never had surgical intervention. Some had failed surgical intervention prior to presentation. Satisfactory outcomes were achieved despite late intervention but failed initial intervention was associated with poorer outcomes.

Key words: Adolescents and adult clefts, cleft lip and palate, cleft lip palate Nigeria

Date of Acceptance: 17-12-2011

Introduction

Cleft lip and palate (CLP) defects usually present in infancy prompted by early stigmatization.^[1-3] With accessible care in western nations, late presentation is usually for uncorrected nose or secondary lip, nose deformity and occlusal defects.^[4,5] However, despite availability of care, late presentation is reported in Nigeria.^[6-7]

The incidence of CLP in general is low^[8] and although adult CLP has been reported from other studies in Nigeria,^[9-13] these do not give a complete picture of the prevalence of adult CLP in our country.

The purpose of this article is to review adolescent and

adult CLP patients in our center, with the advent of free and available care, and to document the patterns and management outcomes of these patients as an addition to existing literature on the subject of adult CLP.

Materials and Methods

A retrospective review of all adolescent and adult patients that were treated for CLP defects, at the center from May 2006 to April 2010. This period is marked by the introduction of free specialist care for patients and was preceded by mass publicity.

Address for correspondence:

Dr. AO Oladele,
Plastic Surgery Unit, Department of Surgery, P.O. Box 2032,
Obafemi Awolowo University, Ile-Ife, Nigeria.
E-mail: ayodejiolarewaju@yahoo.com

Access this article online

Quick Response Code:



Website: www.njcponline.com

DOI: 10.4103/1119-3077.104512

PMID: 23238188

Information retrieved from hospital records includes demographic data, description of cleft type, types of surgeries performed prior to presentation, type of surgical intervention performed in our center, surgical complications if any, and duration of hospital stay and follow-up. These were subjected to simple statistical analysis using the Statistical Package for Social Scientists Software, version 16. Some preoperative, intraoperative and postoperative clinical photographs were also retrieved and are presented.

Results

A total of 137 patients were managed for cleft lip and palate deformity during the period. Adults and adolescents above 13 years of age were 33 (24.1%). Out of these 33 patients, 11 (33.3%) were males and 22 (66.7%) were females. The mean, median and modal ages were 28, 22 and 20 years, respectively. The ages ranged from 13 to 76 years. The age distribution of patients is shown in [Figure 1]. The details of the distribution of various types of cleft by gender are shown in Table 1.

Two-thirds of the patients had never had surgery. We performed 37 procedures in the 33 patients. The details of those who had surgery performed before presenting and their outcomes are shown in Table 2. No pre-surgical orthodontic treatment or alveolar bone grafts were performed. The unilateral cleft lip was repaired by the rotation advancement technique or

its variant, the cleft palate defects were closed by the von langenbeck technique or its modifications. Local anesthesia was employed in six patients while general anesthesia with endotracheal intubation was employed in the others.

The procedures performed on the patients are as follows: cleft palate repair in four patients, bilateral lip repair in four patients, lip nose repair in 21 patients, palate fistula repair in three patients, and lip nose revision in five patients. There was no dehiscence in all lip repairs; the two patients who presented with palate fistula were successfully repaired.

Only four of the patients with cleft palate had been repaired out of which two developed palate fistula and one was successfully repaired. The other patient has been lost

Table 1: Frequency of different types of adolescent and adult clefts by gender

Diagnosis	Male (%)	Female (%)	Total (%)
Unilateral cleft of primary palate	4 (12.1)	11 (33.3)	15
Bilateral cleft of primary palate	2 (6.1)	2 (6.1)	4 (12.1)
Unilateral cleft of lip and palate	2 (6.1)	6 (18.2)	8 (24.3)
Bilateral cleft lip and palate	1 (3)	1 (3)	2 (6.1)
Isolated cleft palate	2 (6.1)	1 (3)	3 (9.1)
Midline defect of primary palate	0	1 (3)	1 (3)
Total	11 (33.4)	22 (66.6)	33 (100)

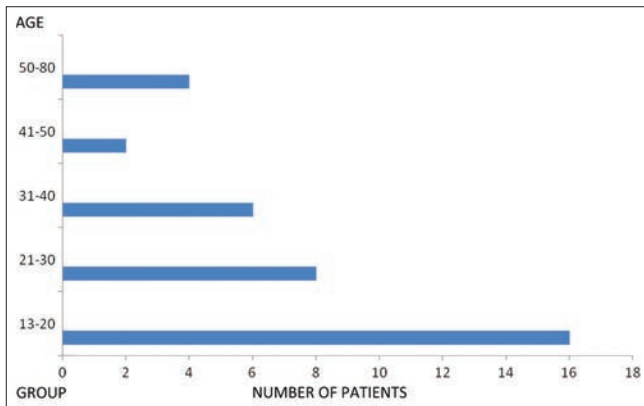


Figure 1: Age distribution of adolescent and adult cleft patients on bar chart.

Table 2: The diagnoses and outcomes of prior surgery in adult cleft patients at presentation

Patients who had prior surgery 11 (33.3%)		
Diagnosis	Operation done	Outcome
Cleft lip	Lip repair 6	Four failed total dehiscence, two required lip/nose revision
Cleft lip and palate 1	Lip repair	Required fistula repair
Bilateral lip repair 2	Bilateral lip repair	Required revision
Isolated cleft palate 2	Palate repair	Palatal fistula

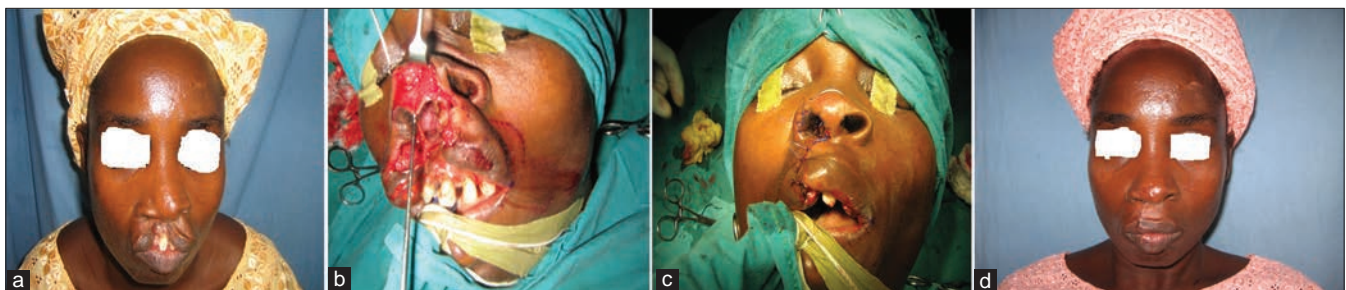

Figure 2: Adult cleft patient who had open rhinoplasty to correct alar cartilage deformity; (a) preoperative photo, (b) intraoperative photo, (c) immediate postoperative photo, (d) late postoperative photo

to follow-up. Primary nasal reconstruction was performed in some patients with lip and nose repair. Open rhinoplasty method was employed in some patients to achieve alar cartilage repositioning. This is as depicted in [Figure 2].

Complications recorded are shown in Table 3. Facial edema was due to extensive dissection to achieve nasal reconstruction and usually resolved within a few days [Figure 3]. Hypertrophic scar was managed by topical application of silicone gel. One patient had secondary rhinoplasty to correct narrowing of the nostril, following repair of bilateral cleft lip [Figure 4]. Outcome was poorer in those who had a failed earlier attempt at surgery [Figures 5 and 6]. An elderly patient also had cleft lip repaired [Figure 7].

Five patients were treated as day case surgeries while others were admitted for periods which ranged from 3 days to 28 days. The mean duration of admission was 7 days. (Average duration for cleft palate repair was 11 days while that for lip repair was 5 days.) A patient was admitted for 28 days

because she required a lip switch operation, in two stages to repair an upper lip midline defect, and stayed in hospital the whole duration of the time pending division and inseting.

Mean duration of follow-up was 10 weeks, with a median and mode of 4 weeks. Initial satisfactory appearances were sometimes followed by late distortions [Figure 2d].

Discussion

A higher percentage of adult CLP have been reported from places with poor access to cleft care.^[9,14-16] The 24%

Table 3 : Complications recorded in the patients

Complication	Number of patients
Reactionary hemorrhage	4
Nasal/ facial oedema	3
Hypertrophic scarring	4
Lip notching	2
Total	13

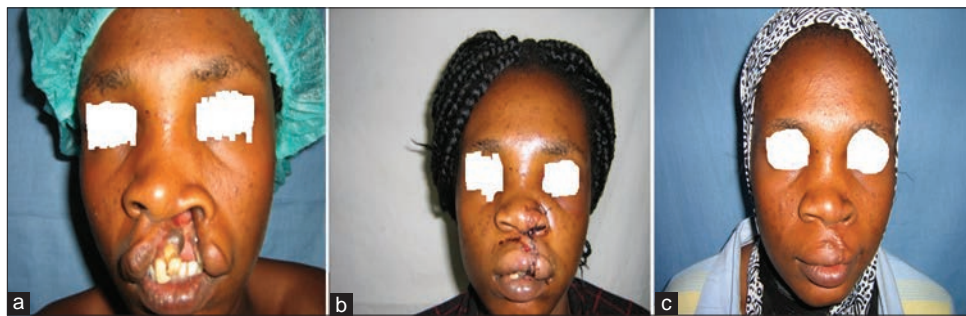

Figure 3: A 30-year-old patient who had open rhinoplasty (a) preoperative photo, (b) early postoperative photo showing facial edema, (c) full resolution of edema and good outcome 3 months post operatively

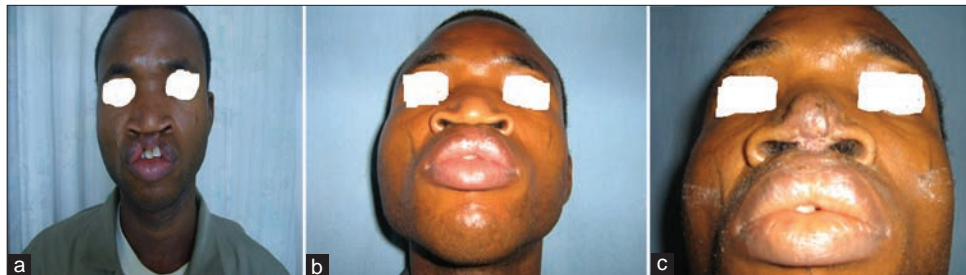
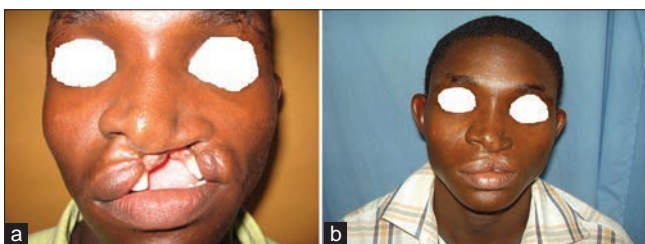


Figure 4: Bilateral cleft lip in a 30-year-old man who had lip repair (a) preoperative photo, (b) postoperative photo showing narrowing of the nostril, (c) early post operative photo after corrective rhinoplasty.



Figures 5 and 6: Poor cosmetic outcome in patient whose earlier attempt at repair of unilateral and bilateral cleft lip, respectively, before presenting to our unit, resulted in dehiscence. (a) preoperative photos (b) post operative photos

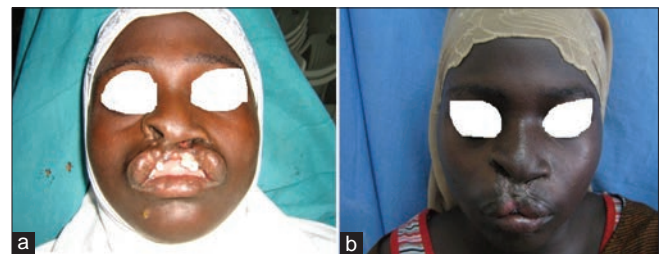

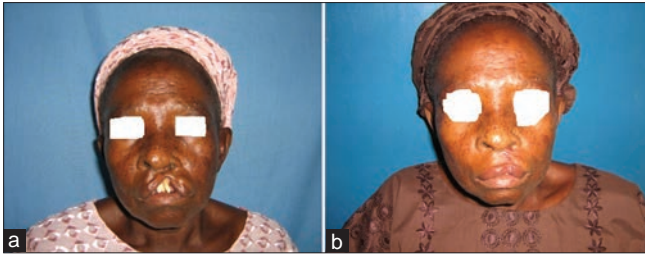


Figure 7: Elderly patient who had cleft lip repair. (a) preoperative photo (b) postoperative photo.

of patients presenting with adult CLP compares with that in other areas.^[7,14,16] Though the incidence of CLP is low, it is thought that underreporting could contribute^[11] bearing in mind the challenges with ascertaining these figures.^[17,18] A more accurate incidence of CLP in the general population will be determined by broad-based multicenter studies.

The female: male ratio of 2:1 in this study group may reflect a higher level of body consciousness even in middle aged. That a third of the patients have had previous attempts at surgery may also refute the thinking that all adult patients with CLP were not documented in childhood but suggests a low level of training in surgeons who performed initial intervention but this record was not available for review.

The management of adolescents and adult patients CLP follows the same principles as that of the child^[6] but the delay in presentation means that proposed normal time-lines and treatment protocols are individualized.^[19,20]

Pre surgical orthodontic devices were not used in our patients due to costs. We do not perform labial adhesion^[21] in our practice as patients may fail to turn up for definitive surgery

Day case surgery for clefts has advantages^[22,23] and was utilized in five of our patients. Adults are better suited^[13] as they are more compliant with administration of local anesthesia, heeding postoperative instructions and communicating postoperative complaints. The need for dissection of the alar cartilages for nasal reconstruction necessitated the use of general anesthesia in many of those who only had cleft lip repair.

Most of our patients required admissions because of the need to ensure adequate post operative care and wound healing prior to discharge as many travelled long distances to access care. This accounted for the long average duration of hospital stay.

The primary correction of the nasal deformity is considered a corner stone of adult cleft lip repair as in the child.^[16] Adult cleft rhinoplasty is more challenging than in children below 2 years of age due to significant increase in cleft

size with age, less elasticity and a more severe deformity of the nasal cartilages.^[14,22] The cleft nasal deformity is preferably corrected by external rhinoplasty approach and the results are usually satisfactory.^[4] Although ecchymosis occurs as a complication, it resolves within a few weeks but late deformities may also occur after initial satisfactory correction and may lead patients to request further revision.^[24]

In adult palate repair, the adherent non-pliable mucoperiosteal flaps as well as the near-vertical palatal shelves also make the repair more difficult than in children.^[19,22]

Two patients in this review requested lip and nose revision for previous cleft lip repair from other surgeons, while three of our patients did the same. This is not out of place, as up to 80% of patients have been reported to request secondary nose revision surgery following CLP repair.^[21] Four patients had failed lip surgery performed before referral to our center with total dehiscence and scarring, and this significantly affects the final cosmetic outcome [Figures 5 and 6].

Although CLP patients will require medical supervision throughout life,^[20] most of our patients are soon lost to follow-up with a mean duration of 10 weeks. Many of the patients with combined CLP have yet to report for palate repair. This makes it difficult to know the true rates of request for revision surgery, and we only assume they are satisfied with outcomes. The combined repair of both cleft lip and cleft palate in one stage has been a proposed possible solution, but this should be chosen judiciously as it is more invasive and results in higher morbidity.^[22,25] Some authors repair the palatal defect before the lip defects to compel a return for the lip surgery,^[19] but this may be difficult to justify as it prolongs the stigmatization to which these patients are already subjected and is not recommended.

Because cleft care is in evolution in Nigeria,^[26] adult patients are likely to diminish significantly^[2,9] as the level of awareness increases and the availability of affordable cleft care is assured.

We conclude that there was a high proportion of adolescent and adult patients presenting with CLP deformity with the advent of free cleft care as previously reported.^[5,6] This supports the observation of lack of money as the commonest reason for late presentation.^[7] A female preponderance of unilateral clefts was noted and many of these patients had never had any form of treatment. The outcome of surgery was adjudged to be satisfactory in the short term but poor follow-up made long-term evaluation difficult. Failed primary intervention in cleft lip repair was associated with poorer cosmetic outcome at repeat surgery.

References

1. Theogaraj SD, Joseph LB, Mani M. Statistical analysis of 750 cleft lip and palate patients. *Indian J Plast Surg* 2007;40:70-4.
2. Osuji OO, Ogar DI, Akande OO. Cleft lip and palate in the University College Hospital Ibadan. *West Afr J Med* 1994;13:242-4.
3. Mzezewa S, Muchemwa FC. Reaction to the birth of a child with cleft lip or cleft palate in Zimbabwe. *Trop Doct* 2010;40:138-40.
4. Ahuja RB. Radical correction of secondary nasal deformity in unilateral cleft lip patients presenting late. *Plast Reconstr Surg* 2001;108:1127-35.
5. Sakamoto T, Sueishi K, Miyazaki H, Katada H, Ebihara T, Kosaka T. Clinical statistical investigation of cleft lip and palate patients aged over 18 years at the department of orthodontics, Suidobashi hospital, Tokyo dental college. *Bull Tokyo Dent Coll* 2008;49:33-9.
6. Adigun I, Adeniran JO. Unoperated adult cleft of the primary palate in Ilorin, Nigeria. *Sahel Med J* 2004;7:18-20.
7. Adeyemo WL, Ogunlewe MO, Desalu I, Mofikoya BO, Adeyemi MO, *et al.* Cleft deformities in adults and children aged over six years in Nigeria: Reasons for late presentation and management challenges. *Clin Cosmet Investig Dent* 2009;1:63-9.
8. Iregbulem LM. The incidence of cleft lip and palate in Nigeria. *Cleft Palate J* 1982;19:201-5.
9. Adekeye EO, Lavery KM. Cleft lip and palate in Nigerian Children and adults. A comparative study. *Br J Oral Maxillofac Surg* 1985;23:398-403.
10. Olasoji HO, Dogo D, Obiano SK, Yawe T. Cleft lip and cleft palate in North Eastern Nigeria. *Nig Q J Hosp Med* 1997;7:209-10.
11. Okar KS, Ugwu BT, Momoh JT. Cleft lip and palate: the Jos experience. *East Afr Med J* 2002;79:510-3.
12. Olasoji O, Arotiba T, Dogo D. Experience with unoperated cleft lip and palate in a Nigerian teaching hospital. *Trop Doct* 2002;32:33-6.
13. Ugboke VI, Olasoji HO, Otuyemi OD, Ogunbodede EO. The use of local anaesthesia in adult cleft lip repair; case reports and review of literature. *Sahel Med J* 2001;4:135-8.
14. Aziz SR, Rhee ST, Redai I. Cleft surgery in rural Bangladesh: reflections and experiences. *J Oral Maxillofac Surg* 2009;67:1581-8.
15. Obuekwe O, Akapata O. Pattern of cleft lip and palate [corrected] in Benin-city, Nigeria. *Centr Afr J Med* 2004;50:65-9.
16. Ahuja RB. Primary definitive nasal correction in patients presenting for late unilateral cleft lip repair. *Plast Reconstr Surg* 2002;110:17-24.
17. Khan AA. Congenital malformation in African neonates in Nairobi. *J Trop Med Hyg* 1965;68:272-4.
18. Butali A, Mossey PA. Epidemiology of Orofacial clefts in Africa: Methodological challenges in ascertainment. *Pan Afr Med J* 2009;30:2-5.
19. Murthy J. Management of cleft lip and palate in adults. *Indian J Plast Surg* 2009;42 Suppl:S116-122.
20. Thompson HG, Lindsay WK. Cleft lip and palate Treatment program: a group approach. *Can Med Assoc J* 1968;99:758-62.
21. Mulliken JB, Martinez-Perez D. The principle of rotation advancement for the repair of unilateral cleft lip and nasal deformity: technical variations and analysis of results. *Plast Reconstr Surg* 1999;104:1247-60.
22. Morioka D, Yoshimoto S, Udagawa A, Ohkubo F, Yoshikawa A. Primary repair in adult patients with untreated cleft lip cleft palate. *Plast Reconstr Surg* 2007;120:1981-8.
23. Ugburo AO, Desalu I, Adekola AF, Fadeyibi IO. Day case cleft lip surgery in Lagos, Nigeria. *Cleft Palate Craniofac J* 2009;46:636-41.
24. Marcusson A, Paulin G, Ostrup L. Facial appearance in adults who had cleft lip and palate treated in childhood. *Scand J Plast Reconstr Surg Hand Surg* 2002;36:16-23.
25. Gopalakrishna A, Agrawal K. A status report on management of cleft lip and palate in India. *Indian J Plast Surg* 2010;43:66-75.
26. Akinmoladun VI, Obimakinde OS. Team approach concept in management of oro-facial clefts: a survey of Nigerian practitioners. *Head Face Med* 2009;5:11. Available from: <http://www.head-face-med.com/content/5/1/11> [Last accessed on 2011 Sep 16]

How to cite this article: Oladele AO, Olabanji JK, Awe OO. Adolescent and adult cleft lip and palate, in Ile-Ife, Nigeria. *Niger J Clin Pract* 2012;15:403-7.

Source of Support: Nil, **Conflict of Interest:** None declared.

Author Help: Online submission of the manuscripts

Articles can be submitted online from <http://www.journalonweb.com>. For online submission, the articles should be prepared in two files (first page file and article file). Images should be submitted separately.

1) **First Page File:**

Prepare the title page, covering letter, acknowledgement etc. using a word processor program. All information related to your identity should be included here. Use text/rtf/doc/pdf files. Do not zip the files.

2) **Article File:**

The main text of the article, beginning with the Abstract to References (including tables) should be in this file. Do not include any information (such as acknowledgement, your names in page headers etc.) in this file. Use text/rtf/doc/pdf files. Do not zip the files. Limit the file size to 1024 kb. Do not incorporate images in the file. If file size is large, graphs can be submitted separately as images, without their being incorporated in the article file. This will reduce the size of the file.

3) **Images:**

Submit good quality color images. Each image should be less than **4096 kb (4 MB)** in size. The size of the image can be reduced by decreasing the actual height and width of the images (keep up to about 6 inches and up to about 1800 x 1200 pixels). JPEG is the most suitable file format. The image quality should be good enough to judge the scientific value of the image. For the purpose of printing, always retain a good quality, high resolution image. This high resolution image should be sent to the editorial office at the time of sending a revised article.

4) **Legends:**

Legends for the figures/images should be included at the end of the article file.