

# A clinical case report of Hashimoto's thyroiditis and its impact on the treatment of chronic periodontitis

BS Patil, GR Giri

Department of Periodontology, S. Nijalingappa Institute of Dental Sciences and Research, Gulbarga, India

## Abstract

Periodontitis is a multifactorial disease with microbial dental plaque as the initiator of periodontal disease. However, the manifestation and progression of the disease is influenced by a wide variety of determinants and factors. The strongest type of causal relationship is the association of systemic and periodontal disease. Hashimoto's thyroiditis has also been considered as one of the causes of periodontal disease.

This clinical case report highlights the impact of Hashimoto's thyroiditis on the outcome of periodontal therapy.

**Key words:** Chronic periodontitis, Hashimoto's Thyroiditis, periodontal medicine

**Date of Acceptance:** 7-Feb-2011

## Introduction

In recent times, the optimal treatment for the improvement of periodontal health has become a frequent challenge to the periodontist. Recent studies in periodontal medicine, suggest a mild-to-moderate association between certain systemic disorders such as diabetes mellitus, pneumonia, heart diseases, pre-term deliveries, and rheumatoid arthritis.<sup>[1]</sup> New data suggests that this association is not indicated by traditional clinical signs of periodontal disease, but rather by a cluster of host immune and inflammatory mediators.<sup>[2]</sup>

Periodontal medicine is based on molecular criteria and will affect the future of periodontal diagnosis, treatment, and professional practice.<sup>[1]</sup> Recent evidence suggests that the underlying systemic conditions affect the outcome of the periodontal treatment plan.<sup>[2]</sup> Identifying and alleviating these systemic disease conditions for further periodontal improvement is of paramount importance.

Hashimoto's thyroiditis (HT) is the most common cause of thyroid disease in children and adolescents. It is also called as autoimmune or chronic lymphocytic thyroiditis.

It is characterized by the production of immune cells and autoantibodies by the body's immune system in the thyroid tissue.<sup>[3]</sup>

This article presents a clinical case report of a periodontitis condition, wherein, periodontal therapy is compromised due to the underlying Hashimoto's thyroiditis, which is a systemic condition.

## Case Report

A 45-year-old female patient reported to the Department of Periodontology, complaining of bleeding gums in the upper and lower jaws since six months, and loose teeth in the front region of her lower jaw since three months.

A clinical examination revealed poor oral hygiene,<sup>[4]</sup> with stains and calculus as a local factor, with generalized bleeding on probing (BOP), generalized pockets of 6 – 8 mm, Millers mobility,<sup>[5]</sup> Grade III, in the maxillary left canine and first premolar, and Grade I mobility in the maxillary right first and second molars, left second premolar, and mandibular

### Address for correspondence:

Dr. Bindu S. Patil,  
Department of Periodontics,  
S.Nijalingappa Institute of Dental Sciences and Research,  
Sedam Road, Gulbarga- 585 105, India.  
E-mail: satpat71@gmail.com

### Access this article online

#### Quick Response Code:



Website: [www.njcponline.com](http://www.njcponline.com)

DOI: 10.4103/1119-3077.94113

PMID: 22437105

left and right first molars. The radiographic findings revealed 60–70% bone loss with respect to the same teeth [Figure 1].

Routine blood investigations comprising of clotting time, bleeding time, white blood count, differential count, hemoglobin, and blood glucose levels, were with normal values.

A diagnosis of chronic periodontitis was made. The surgical treatment comprising of the pocket reduction therapy and periodontal full thickness flap with bone grafting [Osseo graft, Demineralized bone matrix xenograft (type I collagen) granules, manufactured and marketed by Advanced Biotech Products (P) Ltd. Chennai, India], in relation to the above mentioned teeth, was performed accordingly. During the maintenance phase, after six months, there was no bleeding on probing; the periodontal pockets were reduced to a depth of 3 mm. The patient presented with good oral hygiene.

After a year, the patient visited the department complaining of loose teeth in the upper front region. The patient had consulted the gynecologist for the symptoms of menstrual irregularity and weight gain, which on subsequent investigations revealed the presence of Hashimoto's thyroiditis. Thyroid scintigraphy showed high thyroid stimulating hormone (TSH) levels and diffuse thyromegaly with organification defect, suggestive of Hashimoto's thyroiditis. The patient was administered a daily dose of thyroxine replacement by the physician. An intraoral clinical examination revealed grade III mobility in the maxillary left lateral incisor and second premolar, grade II in the maxillary left central incisor and mandibular right first molar. Periodontal pockets of 10 mm were detected in relation to the maxillary right and left first molar, mandibular left first premolar, molar, and right first molar.

Radiographic findings revealed 70–80% loss of bone in relation to the mandibular right and left second premolar and first molar, and 60% loss of bone in the maxillary second premolar and molars on the left side.

The oral hygiene status was good, and the radiographic findings revealed a vertical defect with maxillary left first molar, mandibular left first premolar, first molar, and right first molar [Figure 2]. In spite of good oral hygiene these findings showed progressive bone destruction [Figure 2].

## Discussion

Hashimoto's thyroiditis (HT) is an autoimmune thyroiditis. In 1912, Hashimoto described the term 'struma lymphomatosa' meaning a focal collection of lymphocytes on the histological examination of the thyroid glands. The autoimmune nature of this form of thyroiditis was established in 1956 by Rotter *et al.*<sup>[3]</sup> The disease is 15–20 times as frequent in

women as in men. It occurs especially during the decades from 30 to 50, but may be seen in any age group, including children. HT patients present with hypothyroidism, mood alteration, weight gain, menstrual disorder, stress, and depression.<sup>[6]</sup> The pathogenesis in Hashimoto's thyroiditis is lymphocytic infiltration into the glands and production of auto-antibodies directed toward thyroglobulin and thyroid peroxidase.<sup>[7]</sup> Oral findings include macroglossia<sup>[8]</sup> dysguesia, delayed root resumption,<sup>[9]</sup> decreased salivary gland secretion,<sup>[10]</sup> poor periodontal health, delayed wound healing, and osteoarthritis of the temporomandibular joint (TMJ).<sup>[10]</sup>

In the present clinical case, the tissue response to periodontal therapy was adversely affected. The clinical parameters comprising of bleeding on probing (BOP), pocket probing depth (PD), and tooth mobility evaluation showed further increased destruction. In the radiographic findings, when pre- and postoperative comparison was made, it showed increased bone loss.

Scardina and Messina<sup>[11]</sup> suggested the possible association of HT and periodontitis, in relation to the poor tissue response to periodontal therapy. Reduced caliber and a greater number of tortuosity of the gingival capillary loops in the interdental region were observed in HT cases. The clinical consequences of altered gingival microcirculation could be a compromise of the first line of defense. For the defense cells to perform their function, some receptors must be expressed in correspondence to the endothelial wall.

Thus, the first step of non-specific defense involves a greater vulnerability in the subject. Such morphological data appear extremely relevant, as they would certainly be altered during particular pathologies such as HT.<sup>[11]</sup> In this case, the amount of alveolar bone was further correlated with the evaluation of salivary alkaline phosphates, which had increased up to 63  $\mu\text{l}$ , in comparison to a normal of  $32.2 \pm 5.2$ . The amount of bone destruction could be

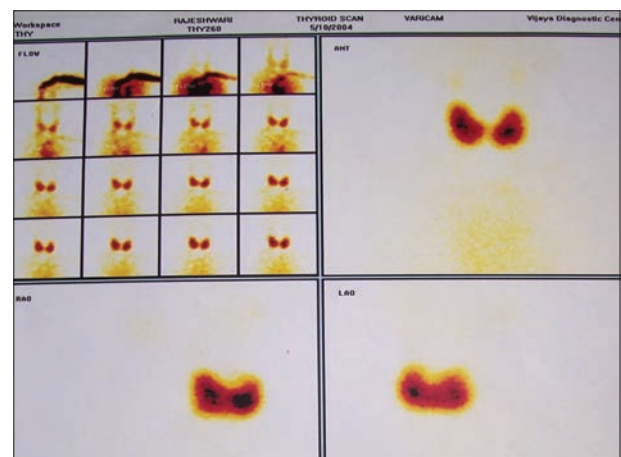
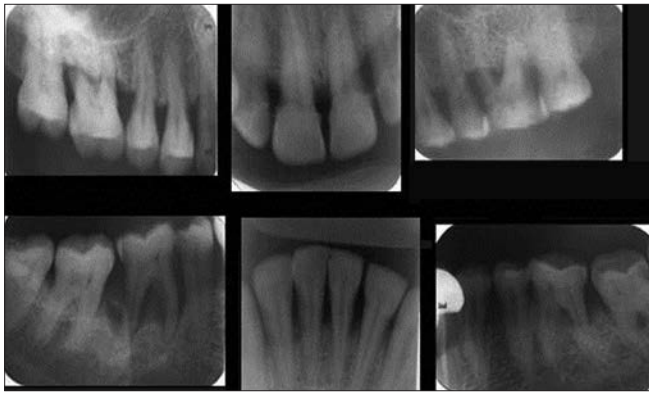
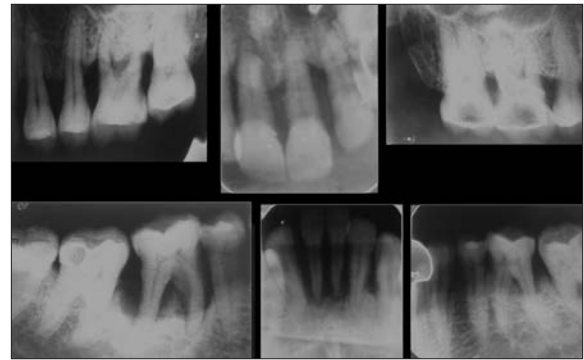


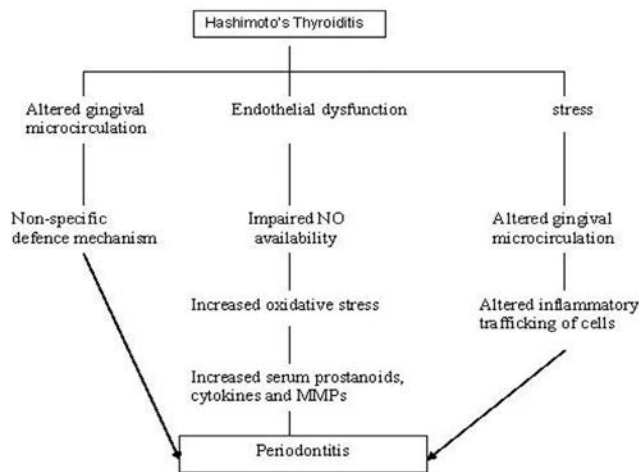
Figure 1: Thyroid scintigraphy



**Figure 2:** Prior to HT and treatment of periodontitis



**Figure 3:** After the treatment, with the development of HT



**Figure 4:** Schematic presentation of HT and Periodontitis

attributed to the pathogenesis of HT. The endothelial dysfunction in these patients, presenting with low-grade chronic inflammation, impaired nitric oxide availability by a Cox-2 dependent pathway, leading to the increased production of oxidative stress.<sup>[12,13]</sup>

A schematic presentation of HT and Periodontitis is shown [Figure 4]. Stress or mood alteration are the characteristic features of HT. Evidence suggesting stress and periodontal disease has already been stated.<sup>[14]</sup> Therefore, a correlation of stress altering the blood flow and trafficking of inflammatory cells can induce a set of reactions that have an effect on virtually all body systems. However, the association of HT, Stress, and Periodontitis needs to be evaluated.

### Conclusion

Hormonal alterations influence changes in the human system. HT, an autoimmune disease, had affected a female in

this case report, who presented with severity of periodontal disease after a year of scheduled treatment. For reconsidering the possible association of systemic and periodontal disease, further clinical studies with relevant investigations are needed, to prove the relation of periodontitis with HT.

### References

1. Teng YT, Taylor GW, Scannapieco F, Kinane DF, Curtis M, Beck JD, et al. periodontal health and systemic disorders. *J Can Dent Assoc* 2002;683:188-92.
2. Teng YT, Taylor GW, Scannapieco F, Kinane DF, Curtis, Beck JD, et al. Periodontal health and systemic disorders. *J Can Dent Assoc* 2002;68:188-92.
3. Ohye H, Nishihara E, Sasaki I, Kubota S, Fukata S, Amino N, et al. Four cases of Graves' disease which developed after painful Hashimoto's thyroiditis. *Intern Med* 2006;45:385-9.
4. Loe H. The gingival index, the plaque index and the retention index systems. *J Periodontol* 1967;38(suppl):610-6.
5. Muhleman HR. Tooth mobility: A review of clinical aspects and research findings. *J Periodontol* 1967;38(suppl):686-723.
6. Flynn SD, Nishiyama RH, Bigos ST. Autoimmune thyroid disease: Immunological, Pathological and clinical aspects. *Crit Rev Clin Lab Sci* 1988;26:43-95.
7. Little JW. Thyroid disorders, Part II: Hypothyroidism and Thyroiditis. *Oral Surg Oral Med Oral Pathol Oral Radiol Endod* 2006;102:148-53.
8. Burman KD, McKinley-Grant L. Dermatologic aspects of thyroid disease. *Clin Dermatol* 2006;24:247-55.
9. Pizzorni C, Sulli A, Craviotto C, Tuccio M, Seriola B, Cutolo M. Diagnostic perspectives in the rheumatological vasculitis: The role of the video-capillaroscopy (in Italian). *Reumatismo* 2000;54:99-104.
10. Chang CP, Shiau YC, Wang JJ, Ho ST, Kao CH. Decreased salivary gland function in patients with autoimmune thyroiditis. *Head Neck* 2003;25:132-7.
11. Kinane DF. Periodontal diseases contribution to cardiovascular disease: an overview of potential mechanisms. *Ann Periodontol* 1998;3:142-50.
12. Scardina GA, Messina P. Modifications of interdental papilla microcirculation: A possible cause of periodontal disease in Hashimoto's Thyroiditis? *Ann Anat* 2008;190:258-63.
13. Taddei S, Caraccio N, Viridis A, Dardano A, Versari D, Ghiadoni L, et al. Low grade systemic inflammation causes endothelial dysfunction in patients with Hashimoto's thyroiditis. *J Clin Endocrinol Metab* 2006;91:5076-81.
14. Boyapati L, Wang HL. The role of stress in periodontal disease and wound healing. *Periodontol* 2000 2007;44:195-210.

**How to cite this article:** Patil BS, Giri GR. A clinical case report of Hashimoto's thyroiditis and its impact on the treatment of chronic periodontitis. *Niger J Clin Pract* 2012;15:112-4.  
**Source of Support:** Nil, **Conflict of Interest:** None declared.