

**CASE REPORT**

# African traditional medication and keloid formation in herpes zoster ophthalmicus

OO Komolafe, OT Ogunleye, OO Fasina<sup>1</sup>, OA Komolafe<sup>2</sup>Departments of Ophthalmology, and <sup>2</sup>Pharmaceutical Service, Federal Medical Centre, Owo, <sup>1</sup>Department of Ophthalmology, University College Hospital, Ibadan, Nigeria

## Abstract

Keloid scar complicating herpes zoster ophthalmicus (HZO) has not been much reported among Africans despite the African population having dark skin. We report on a middle-aged Nigerian with HZO who developed keloid scar following use of traditional herbs to the herpetic rashes. A 52-year-old immune-competent Nigerian male presented with a 2-week history of vesicular rashes involving the left side of the forehead down to the tip of the nose. He initially presented to an African traditional healer who had advised application of various herbs to the lesion. When he presented to the eye clinic, he was treated for the associated uveitis with significant improvement. The cicatricial skin change gradually became raised with clinical appearance of keloid at 1 year of follow-up. Cicatricial skin changes in HZO are not unusual, but keloid formation among Africans has not been much described. Late presentation, use of traditional herbs some of which have corrosive effect and secondary bacterial infection are the possible factors that may encourage such abnormal wound healing. The myth associated with HZO in the local African setting as well as the fact that African traditional healers are still widely accepted among most African communities may play a role in increasing the risk of keloid formation among our population following HZO infection.

**Key words:** Herpes zoster ophthalmicus, keloid scar, myth, traditional medication**Date of Acceptance:** 04-Mar-2011

## Introduction

Herpes zoster ophthalmicus (HZO) refers to herpes zoster involvement of the ophthalmic division of the trigeminal nerve (fifth cranial nerve).<sup>[1]</sup>

Cicatricial skin changes from herpes zoster are not unusual.<sup>[2]</sup> There had been reports of cicatricial entropion complicating HZO.<sup>[3-5]</sup> Also among Indians, Nanda *et al.*<sup>[6]</sup> reported on four cases of keloid scar complicating HZO, which was attributed to secondary infection.

Excessive scars form as a result of the aberration of physiologic wound healing following insult to the deep dermis such as seen in burn injury, lacerations abrasions and surgery.<sup>[7]</sup>

Not much had been reported about keloid scar in patients with HZO among indigenous Nigerians despite the fact

that dark-skinned individuals are more susceptible to keloid formation.

We report a case in which the initial herpes zoster cicatricial changes became keloid scars. There was also application of traditional medication prior to presentation to the eye clinic.

## Case Report

A 52-year-old immune-competent Nigerian male presented with a 2-week history of vesicular eruptions involving the left side of the forehead, with some reduction in vision in the left eye. There was history of presenting to a tradomedical facility where various locally prepared herbs were rubbed

**Address for correspondence:**

Dr. Opeyemi Komolafe,  
Department of Pharmaceutical Service, Federal Medical Centre,  
Owo, Nigeria. E-mail: [kopeyemi@yahoo.co.uk](mailto:kopeyemi@yahoo.co.uk)

**Access this article online****Quick Response Code:****Website:** [www.njcponline.com](http://www.njcponline.com)**DOI:** 10.4103/1119-3077.91761**PMID:** 22248955

on the rashes, prior to presenting to the eye clinic. He was a mechanical engineer by profession.

On presentation, the pinhole visual acuity was 6/6 in the right eye and 6/36 in the left eye. External examination revealed rashes involving the left side of the forehead down to the tip of the nose (Hutchinson sign) without crossing the midline [Figure 1]. There were mild hyperemia and crusting of the skin of the affected area.

Slit-lamp examination revealed injected conjunctiva with small and medium-sized fresh and pigmented keratic precipitate. There were also some cellular reactions in the aqueous humour. There was some pigment dusting of the anterior lens capsule but no posterior synechiae.

Intraocular pressures (IOP) by Goldmann applanation tonometer were 16 mmHg in the right eye and 18 mmHg in the left eye. Dilated fundal examination was essentially normal in both the eyes.

He was treated with both systemic and topical antiviral agent (Acyclovir), and also topical prednisolone acetate and cyclopentolate, which led to remarkable improvement.

He was followed up in the outpatient clinic during which it was observed that the cicatricial skin changes which were initially flat were becoming raised, and at 1 year of follow-up, the scars had obvious clinical appearance of keloid [Figure 2].

## Discussion

Keloids are abnormal wound response to trauma, inflammation, surgery or burns in predisposed individuals.<sup>[8]</sup> Although there are clinical similarities between hypertrophic scar and keloid, the appearance of the lesions which are firm, mildly tender and bosselated with shiny surface, spreading

out beyond the margin of the initial wound, is in strong support of keloid. This is a similar description that was given by Al-Attar *et al.*<sup>[9]</sup>

The patient revealed history of application of locally prepared herbs to the vesicular eruptions and this most likely accounted for his late presentation to the eye clinic coupled with the deterioration in his vision as a result of the uveitis from the viral infection as evident by the keratic precipitates and aqueous cellular reaction.

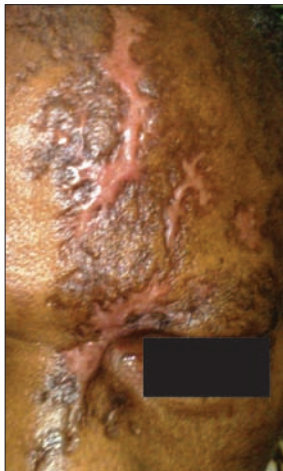
Courtright *et al.*<sup>[10]</sup> showed that the use of traditional eye medication (TEM) is associated with delay in presentation.

There are still a lot of myths associated with skin eruptions seen in HZO among local communities in southwestern Nigeria coupled with the fact that African traditional healers are still widely accepted by rural Africans. It goes by the local names such as “Ata”, “African pepper” and “poisonous dart or arrow”. Hence, it comes as no surprise that our patient first sought care at a traditional healing facility despite being literate.

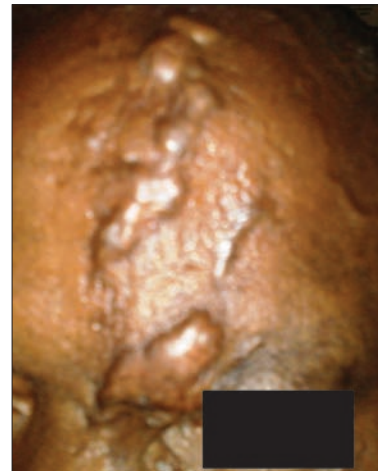
Although the constituent of most of these herbs cannot be ascertained, there is anecdotal evidence in support of the acidic and corrosive nature of some of these agents.

The predisposition to keloid formation has a familial tendency,<sup>[6]</sup> but this may not apply in this patient considering the single anatomical site of the keloid in him. Old scars in other parts of his body showed no feature of keloid even at locations involving high risk such as the chest.

The role of infection as a risk for the keloid formation, similar to what was reported by Nanda *et al.*,<sup>[4]</sup> cannot be completely excluded. Some of the herbs might have been applied under an aseptic condition. Quite often, these concoctions (mixture of various substances which may



**Figure 1:** Scar at 8 weeks of presentation



**Figure 2:** Keloid scar at 1 year of presentation

be herbs or animal extracts) are made without regard for hygiene.<sup>[11]</sup> However, at the time of presentation, there was no overt clinical evidence in support of this because the degree of hyperemia of the skin was not out of phase with the inflammation from the resolving rashes. Also, there were no discharges.

This case report reiterates the need for more health education and public enlightenment on clinical entities such as HZO, with an emphasis on debunking some of the myths attached to HZO among an indigenous African community. There is also a place for a larger case series to find out if there is a bias toward keloid formation in those treated with traditional medicine and to try to establish the constituent of the traditional medication used.

## References

1. Liesegang TJ. Herpes zoster ophthalmicus. Natural history, risk factors, clinical presentation and morbidity. *Ophthalmology* 2008;115 (2 Suppl):S3-12.
2. Kaufman SC. Anterior segment complications of herpes zoster ophthalmicus. *Ophthalmology* 2008;115 (2 Suppl):S24-32.
3. Sanghvi CA, Leatherbarrow B, Ataullah S. Cicatricial ectropion due to herpes zoster ophthalmicus. *J Postgrad Med* 2006;52:153-4.
4. Smith JP, Lavine DM. Cicatricial ectropion of the upper lid secondary to herpes zoster ophthalmicus. *Ann Ophthalmol* 1981;13:579-80.
5. Nasr AM, Beyer-Machule CK, Yeatts RP. Cicatricial ectropion secondary to herpes zoster. *Ophthalmic Surg* 1983;14:763-5.
6. Nanda S, Rajpal M, Grover C, Reddy BS. Keloid—An under reported complication of herpes zoster: Report of 4 cases. *Indian J Dermatol* 2005;50:84-6.
7. Gauglitz GG, Korting HC, Pavicic T, Ruzicka T, Jeschke MG. Hypertrophic scarring and keloids: Pathomechanisms, current and emerging treatment strategies. *Mol Med* 2011;17:113-25.
8. English RS, Shenefelt PD. Keloids and hypertrophic scars. *Dermatol Surg* 1999;25:631-8.
9. Al – Attar A, Mess S, Thomassen JM, Kauffman CL, Davison SP. Keloid pathogenesis and treatment. *Plast Reconstr Surg* 2006;117:286-300.
10. Courtright P, Lewallen S, Kanjaloti S. Changing pattern of corneal diseases and associated vision loss at a rural African hospital following a training programme for traditional healer. *Br J Ophthalmol* 1996;80:694-7.
11. Klaus V, Schwartz EC. Other conditions of the outer eye. In: Johnson GT, Minassian DC, Weale R, editors. *The epidemiology of eye diseases 1<sup>st</sup> ed.* Philadelphia: Lipincott. Raven Publishers; 1998. p. 155-8.

**How to cite this article:** Komolafe OO, Ogunleye OT, Fasina OO, Komolafe OA. African traditional medication and keloid formation in herpes zoster ophthalmicus. *Niger J Clin Pract* 2011;14:479-81.

**Source of Support:** Nil, **Conflict of Interest:** None declared.

## Announcement

### Android App



Download  
iPhone, iPad  
application

FREE

A free application to browse and search the journal's content is now available for Android based mobiles and devices. The application provides "Table of Contents" of the latest issues, which are stored on the device for future offline browsing. Internet connection is required to access the back issues and search facility. The application is compatible with all the versions of Android. The application can be downloaded from <https://market.android.com/details?id=comm.app.medknow>. For suggestions and comments do write back to us.