

Treatment of dorsal wrist ganglia by transfixation technique

CM Rathod, AS Nemade, CM Badole

Mahatma Gandhi Institute of Medical Sciences, Sewagram, Wardha, Maharashtra, India.

Abstract

Background: Ganglion is one of the common lesions seen in minor surgical practice. Treatment of dorsal wrist ganglia varies from simple reassurance to excision and advanced endoscopic excision. Irrespective of the treatment modality, recurrence is a common problem.

Materials and Methods: This study evaluates results of 40 wrist ganglia treated by using the transfixation technique.

Results: Out of 40 cases included in this study 38 were completely cured of the symptoms giving a success rate of 95 percent, recurrence was seen in one patient and skin necrosis secondary to tight gauze piece was seen in one patient.

Discussion: Comparing with other modalities this method is cost-effective, less time consuming, minimally invasive, low rate of recurrence, and can be carried out under local anesthesia, and does not require any special instrument and an easy-to-learn technique.

Key words: Ganglion, recurrence, transfixation

Date of Acceptance: 5-Oct-2011

Introduction

Ganglion is one of the troublesome lesions met in minor surgical practice. Although ganglia are extremely common in surgical practice, there is little agreement about their cause or treatment. Dorsum of the hand is the most common site.

The treatment of dorsal wrist ganglia include reassurance of the patient without any intervention, simple aspiration, aspiration and injection with or without hyaluronidase, injection with a sclerosant, transfixation with a silk suture, manual rupture, cyst wall puncture with a percutaneous needle, percutaneous incision with a tenotome, radical excision, either open or endoscopic.

Major problem in the treatment is recurrence no matter whichever modality of treatment is used. The different ways of managing ganglion range from simple expectant treatment to the highly sophisticated arthroscopic resection. Not all patients need or demand treatment nor all patients

can access the most advanced treatment for the same. No matter which treatment is used, what patients demand is the success rate.

This study determines the results of treatment of dorsal wrist ganglia by using the transfixation technique.

Materials and Methods

This prospective study was conducted in the Department of Orthopaedics and Traumatology at our institute from May 2005 to December 2007. The study included 40 cases of dorsal wrist ganglia size more than 5 mm and only cases not intervened earlier.

Exclusion criteria

1) Compound palmar ganglion. 2) Ganglion in the vicinity of radial artery. 3) Ganglion less than 5 mm in size. 4) Infected

Address for correspondence:

Dr. Chasanal Rathod,
55/A/2, European Quarters, Sir Bhalchandra Road,
Dadar (East), Mumbai, Maharashtra-400 014, India.
E-mail: chasanal@gmail.com

Access this article online

Quick Response Code:



Website: www.njcponline.com

DOI: 10.4103/1119-3077.91753

PMID: 22248947

ganglion. 5) Ganglion at a site other than hand. 6) Previous treatment taken in any form. 7) Ganglion associated with arthritic disorder.

Materials

Xylocaine 2% without adrenaline, Sterile cut down tray, Disposable 16G needle, Silk 1-0 (Ethicon)

Surgical technique

The procedure was done on out-patient basis. Under all aseptic precautions, area surrounding the lesion was infiltrated with xylocaine 2%. A sterile silk suture (1-0) was passed through the cyst and taken out from the opposite side [Figure 1]. The thread gets a glistening appearance as it comes out because of the mucin content, which confirms its passage through the cyst. Similarly another thread is passed at right angles to the previous thread. With a 16G disposable needle the content of the cyst were aspirated [Figure 2]. The thread was then tied over the cyst over a sterile gauze piece firm enough to hold it in place. Care is taken not to cause puckering of the skin [Figure 3]. Sterile

compression bandage is given. The patient is sent home with analgesics and an antibiotic. No restriction of activity was required. Patients were advised follow-up after four weeks for suture removal.

Recurrences were considered in those who had a reappearance of the cyst of 1 cm or more at the end of six months and they were taken up for a repeat procedure but thread passed through a different site [Figure 4].

Results

Out of the 40 cases included in this study, 38 were completely cured of the symptoms, thus giving a success rate of 95%. The mean age was 25 years (10–59). There were 26 (65%) females and 14 (35%) males. Of the total 40 patients, 20 (50%) had come to seek treatment for the non-cosmetic appearance of the swelling, whereas 15 (37.5%) presented for pain with cosmetic disfigurement; only five patients came with sole complaint of pain irrespective of

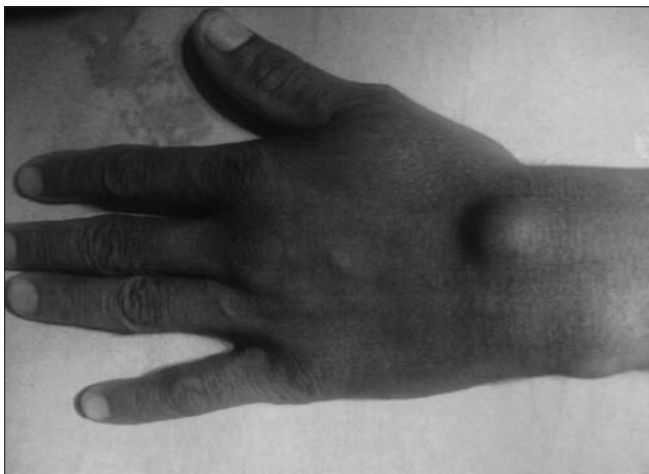


Figure 1: Dorsal wrist ganglion

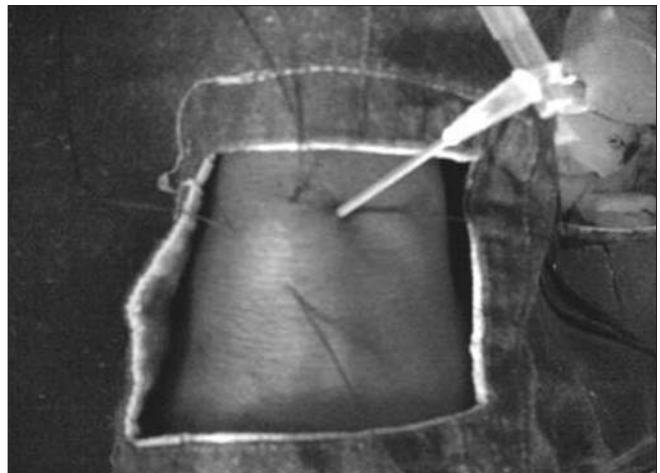


Figure 2: Transfixation of ganglion and gelatinous fluid seen at the needle hub

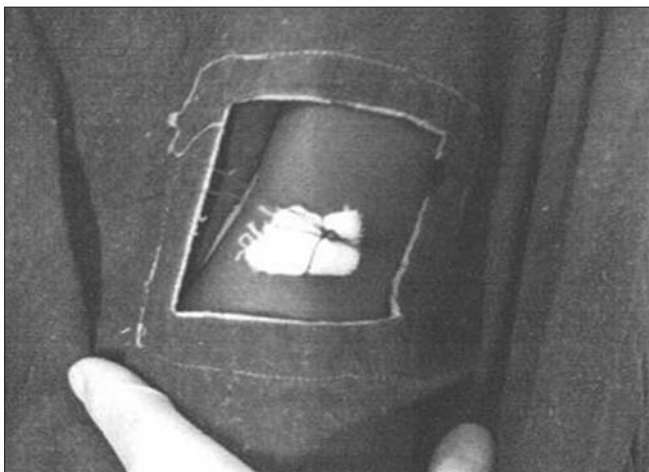


Figure 3: Transfixing sutures tied over a sterile guaze piece

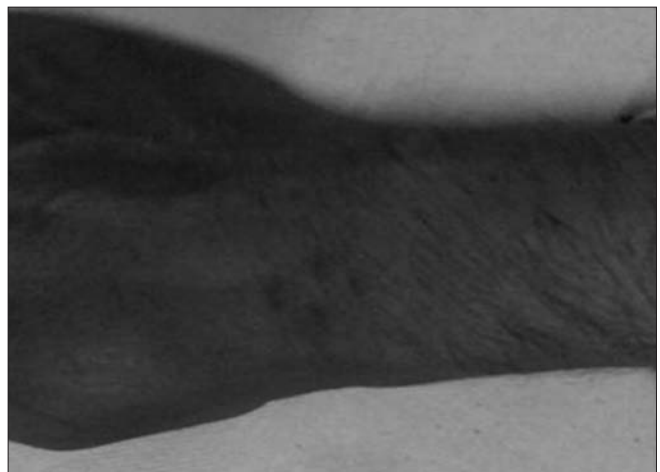


Figure 4: Follow-up at 1 year

the non-cosmetic appearance. Maximum follow-up period was 24 months. Thirty-eight (95%) patients were satisfied with the results. Of the total, 20 patients complaining of pain were completely relieved of pain. Although there was a recurrence of ganglion in one case, she accepted the same as it was less than the previous swelling and not evident easily hence the cosmesis was improved. Therefore there was a 97.5% improvement in the cosmetic outlook of the patient. None of the case had complaint of the restriction of movement at wrist joint

Complications were in encountered in two cases. In one case there was a superficial infection at the site of entry point of threads at ten days of follow-up, which was treated with antibiotics. The final result was equally good. In another case, the patient developed a severe necrosis of the skin under the gauze piece, which needed a prompt early removal of the thread and a course of antibiotics. The lesion healed well but the swelling persisted till the end of this study to a total period of 18 months. It gave rise to an unsightly scar with the same complaints persisting.

Discussion

The ganglion (Greek ganglia: node tissue) is a pseudocyst, i.e., a bag, walls formed by fibrous tissue compressed not secretory that appears as a well-defined nodule, firm, thin walled, which has a gelatinous substance viscous (mucin) and that is always in contact with a capsule or articular synovial sheath. There are many treatment methods available for treating it, which in itself shows that no single efficient method of treatment is available without complications. A large number of methods have been described in the literature regarding the treatment of ganglion, the most ancient being bursting the ganglion with a heavy book (traditionally “the Bible”).^[12] It was observed that ganglia receiving no treatment occasionally give history of spontaneous disappearance.^[4] The methods in use include simple aspiration, aspirations and injection of corticosteroid with or without hyaluronidase,^[12] injection of sclerosing agent,^[9] trans-fixation with silk suture,^[5,6] manual rupture, cyst wall puncture with a needle, radical surgical excision,^[12] arthroscopic excision,^[7] roentgen ray therapy^[8] or simply reassurance to the patient. Success rate of these methods varies considerably. Literature reports high rates of recurrence following various methods of treatment of the ganglion ranging from 2–60%.^[11,12]

Patients treated with aspiration and injection with various medications had good cure rates of 57–64% and those treated with surgical excision had cure rates of 84–94%.^[10,12] The advantages of injection therapy in the form of no scar, relatively low recurrence rate (18%), simple out-patient treatment readily given by

junior doctor, no risk to joints, tendons or neighboring structured, no worsening of the appearance if injection fails to cure.^[10]

Surgical excision of ganglia showed cure rates varying from 84–94% with a recurrence rate of 4–11%.^[1,3,12] The low recurrence rate they observed was because of proper procedure of excision; they have followed and removed the ganglion from the base.^[1] The analysis of 62 operative cases showed that the pedicles of ganglia arose from the scapho-lunate ligament in forty seven (76%) patients; in 2 patients no definite attachment to the capsule could be found and in the remainder the pedicle directly entered the capsule and were not found to attach to deeper structure. Surgical management of ganglion involves risk of nerve injury, keloid formation, post-operative stiffness, scapho-lunate instability, and recurrence.^[2]

In the present study of transfixation method, silk thread passing through the wall of ganglion leads to low-grade inflammation and thickening the cyst wall and hence its spontaneous regression. Aspiration of the contents of ganglion and its regular massage prolongs the contact with thread and hence causes more fibrosis and yields better success rate.

In our study of 40 cases treated by transfixation technique, we observed a cure rate of 95% (38) and recurrence rate of 2.56% (only one recurrence) and one failure, while in similar study carried out by Kapoor *et al.*, of the 108 cases, 102 cases were followed recurrence rate was 4% and cure rate 96%. In another study carried out by Gang and Makhlouf of the 70 cases treated, 62 were followed, 95% were cured and 5% had recurrence. While comparing our results for the recurrence with these studies we observed comparative low recurrence rate, this yielded a successful method of treatment as none of our cases required surgical excision of the ganglion. As per the literature in various studies for conservative and operative management of ganglion the recurrence rate is variable from 2–60%.^[11,12] With advances in technology, arthroscopic resection has been reported to very low recurrence rate of 0–5%,^[7] But the expertise needed and the long learning curve is the major limitation with this method.

Literature reports high rate of recurrence following various methods of treatment of ganglion ranging from 2–60%. Our method of transfixation for the treatment of ganglion is cost effective, less time consuming, minimally invasive, low rate of recurrence, can be carried out under local anesthesia, and does not require any special instrument. This procedure can be done as an outdoor procedure in the minor operation theatre. There are no complications as compared with the surgical excision. Patient acceptance and compliance to the treatment is excellent. An easy-to-learn technique.

References

1. Barnes WE, Larsen RD, Posch JL. Review of the ganglia of the hand and wrist with analysis of surgical treatment. *Plast Reconstr Surg* 1964;34:570-8.
2. Clay NR, Cement DA. The treatment of dorsal ganglia by radical excision. *J Hand Surg Br* 1988;13:187-91.
3. De Orsay RH, Mecray PM, Ferguson LK. Pathology and treatment of ganglion. *Am J Surg* 1937;36:313-9.
4. Dias JJ, Dukaram V, Kumar P. The natural history of untreated dorsal wrist ganglia and patient reported outcome 6 years after intervention. *J Hand Surg Br* 2007;32:502-8.
5. Gang RK, Makhlof S. Treatment of ganglia by thread technique. *J Hand Surg Br* 1988;13:184-6.
6. Kapoor H, Arora J, Jain P, Sharma AK, Sharma VK. Trans-fixation of ganglion. *Indian J Orthop* 2004;264-6.
7. Luchheti R, Badia A, Alfaramo M, Orbay J, Indriago I, Mustapha B. Arthroscopic resection of dorsal wrist ganglia and treatment of recurrences. *J Hand Surg Br* 2000;25:38-40.
8. Lyle FM. Radiation treatment of ganglia of the wrist and the hand. *J Bone Joint Surg* 1941;23:162-3.
9. Mackie IG, Howard B, Wilkins P. The danger of sclerotherapy in the treatment of ganglia. *J Hand Surg Br* 1984;9:181-4.
10. McEvedy BV. A simple ganglion; A review of modes of treatment and an explanation of the frequent failures of surgery. *Lancet* 1954;266:135-6.
11. Muddu BN, Morris MA, Fahmy NR. The treatment of ganglia. *J Bone Joint Surg Br* 1990;72:147.
12. Nelson CL, Sawmiller S, Phalen GS. Ganglion of the wrist and hand. *J Bone Joint Surg Am* 1972;54:1459-64.

How to cite this article: Rathod CM, Nemade AS, Badole CM. Treatment of dorsal wrist ganglia by transfixation technique. *Niger J Clin Pract* 2011;14:445-8.
Source of Support: Nil, **Conflict of Interest:** None declared.

Announcement

Android App



Download
iPhone, iPad
application

FREE

A free application to browse and search the journal's content is now available for Android based mobiles and devices. The application provides "Table of Contents" of the latest issues, which are stored on the device for future offline browsing. Internet connection is required to access the back issues and search facility. The application is compatible with all the versions of Android. The application can be downloaded from <https://market.android.com/details?id=comm.app.medknow>. For suggestions and comments do write back to us.