

PENETRATING HEAD TRAUMA FOLLOWING GUNSHOT IN A NON-NEUROSURGICAL TRAUMA CENTRE: A CASE REPORT

*II Onah, **A Imo

**Trauma Unit, National Orthopaedic Hospital, Enugu, **Radiology, Ebonyi State University Teaching Hospital, Abakaliki*

ABSTRACT

With the dearth of trained neurosurgeons in sub-Saharan Africa and increasing civilian violence, penetrating head trauma occasionally present to other clinicians for management. The National Orthopaedic Hospital, Enugu is a non-neurologic trauma centre having the south-east, south-south geopolitical zones, and parts of Benue and Kogi states as the catchments area. A retrospective report from the case note of a patient with infratentorial brain injury from a gunshot is presented. He was treated conservatively and had a satisfactory outcome. The follow up is for four years. Adequate resuscitation and monitoring is crucial in successfully managing head injuries.

(Accepted 11 February 2009)

INTRODUCTION

Traumatic brain injuries constitute approximately 1% of all injuries, gunshot injuries being responsible for about 12% of them.¹ Infratentorial gunshot wounds (i.e. injuries below the tentorium cerebri) account for less than 3% of civilian craniocerebral gunshot injuries,² and are regarded as fatal³ because of compromise to pontine and midbrain centres and cerebellar herniation through the foramen magnum. The victim of a gunshot wound (GSW) to the head is approximately 35 times more likely to die than is a patient with a comparable nonpenetrating brain injury⁴ for the same reasons.

Penetrating head injury is best managed in a neurosurgical centre, but neurosurgeons are scarce in our environment,⁵ and private neurosurgical service is out of reach for most of the populace, especially without health insurance. This implies that the burden of managing such patients, especially at the acute phase, occasionally still falls on other clinicians. A 36year old man with a gunshot causing an infratentorial brain injury is presented. He was initially managed for 12 days in our trauma unit, and discharged to a neurosurgical centre.

CASE REPORT

Mr C. O. a 36yr old man presented at the trauma unit of National Orthopaedic Hospital, Enugu in May 2004. He was shot by assailants as he fled, sustaining injuries to the posterior chest wall and neck. The weapon was a double barreled gun. He was brought by a vigilante squad to the trauma centre within 30 minutes of the incident. No history of

prolonged loss of consciousness immediately following the incident was admitted but there was memory loss.

Multiple pellet entry points were noted on the posterior trunk and neck. No exit wounds were present. Further examination revealed hypotension, respiratory distress and a Glasgow Coma Score (GCS) of 12. There was weakness of the right upper limb, non progressing dilation of the right pupil, and left sided mouth deviation. A diagnosis of moderate Traumatic Brain Injury [TBI] and penetrating chest injury was made. The brain injury was initially attributed to a concussion from a fall while running from assailants; a penetrating head injury was missed.

Haemorrhagic shock was treated with lactated Ringer's solution, and transfusion of two units of blood. Penetrating chest injury was managed by right thoracic catheterization connected to an underwater seal, oxygen by face mask, 8.4N sodium bicarbonate (for acidosis), and physiotherapy. TBI was further managed by mannitol and tilting the head of the bed to 30°; a burr hole was not offered. The entry point wounds were cleaned and dressed. Monitoring was by urethral catheterization for hourly urine output, serial GCS measurements, pupillary size and light response assessment, and pulse oximeter for continuous oxygen saturation and heart rate. Other management included tetanus prophylaxis, antibiotics (ciprofloxacin), and a 72hour course of Ranitidine. There was scant drainage from the thoracic tube and it was removed within a week. Radiological, hematological and electrolyte studies were done.

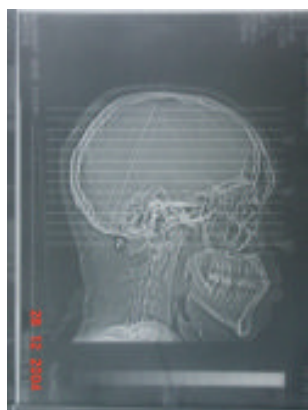
The GCS improved even though there was one episode of haematemesis. He was discharged after 12

Correspondence: Dr II Onah
Email: anyionah@yahoo.com

centre for further management. Computerized Tomography (CT) scan done at that centre showed two pellets lodged in the right occipito-temporal region, one fracturing and penetrating the temporal bone (figure 1). The neurosurgeon also placed him on anticonvulsants and steroids. It was at this point we realized there had been a penetrating skull injury from the pellets. The report given by the second author states: "There is a larger foreign body particle localized extra cranially but postero-lateral to the C1 vertebra. Note the resultant linear streaks of metallic artifacts on the cut at the level of C1. The intracranial foreign particle however does not show any effects on the local intracranial structures. No haematoma formation or any other underlying brain damage is seen on scan."

A year after he has a Glasgow Outcome Score of 5: he no longer had facial deviation and had full power in the lower limbs and grade 4 power in the upper limbs with full return to his business. Four years later he is still free of medication.

Figure 1: CT scan of the patient.



DISCUSSION

Low energy gun shot injury causing penetrating brain injury has been noted to be on the increase but has a better prognosis than penetrating high energy head injury.² The diagnosis of penetrating head trauma was completely missed as the entry points were in the posterior trunk and neck. Seeing he had penetrating chest injuries the penetrating head injury may have occurred from a deflection of 2 pellets or else he was shot more than once from different positions. Owing to the lack of CT scan facilities in our trauma unit and the steady improvement of his focal lesions this basic investigation for traumatic brain injury was delayed. The experience of this has been previously noted.⁵

Presentation with haemodynamic instability following gunshot injury is common in this environment,⁶ but it is a bad prognostic sign. Aggressive resuscitation was commenced as the brain is expected to recover from the primary injury if secondary injury is avoided. Lactated Ringer's

solution and fresh whole blood was used; with a diuretic to manage raised intracranial pressure. The electrolyte contents of lactated Ringer's solution mimic that of plasma and it is isotonic. The lactate produces energy when processed by the tricarboxylic acid (TCA) cycle. Mannitol: an osmotic diuretic was chosen. Along with other pharmacologic agents as dimethyl sulfoxide it has been shown to be beneficial in neuroprotection following missile injury.⁷ Steroids were not used in this patient as the risk of death within 14 days from all causes when they are used acutely is higher than when not used.⁸ The patient was positioned in a 30° head up tilt to optimize brain perfusion.

Haematemesis which occurred on admission in this patient may have resulted from stress gastritis (Cushing's ulcers) known to follow head trauma.^{4,8} It is infrequent, may be a manifestation of a bleeding disorder, but may be managed by H2 receptor blockers and transfusion of fresh whole blood as in this patient.

The principles of surgery of GSW to the head are to debride devitalized tissue, evacuate haematomas causing mass effect, remove accessible missile or bone fragments, i.e. minimal local debridement, meticulous haemostasis, watertight dural closure (patch grafting if necessary), and postoperative control of intracranial pressure.⁹ Broad-spectrum antibiotic, anticonvulsant and tetanus prophylaxis are also administered. In a good number of cases of low velocity penetrating injuries where the patient does not have a deterioration in the GCS conservative management is acceptable and sufficient.^{3, 10} Less aggressive surgical protocols in the presence of retained foreign bodies is also associated with a reduced risk of epilepsy.³ It is based on this that the authors believe the conservative approach was adequate. Close monitoring however was continued in the event of the need for exploration. A major indication for exploration is an expanding space occupying lesion. The presence of monoparesis, hemiparesis, monoplegia, hemiplegia, and 1mm dilation in a previously normal pupil each indicate a space occupying lesion. This can be confirmed by a CT scan: the investigation of choice in TBI. The patient's CT scan result is similar to other CT results following penetrating head injury in our environment.¹¹ However CT scan is not to be used in isolation but in conjunction with clinical findings;⁹ indeed in an early epidural hematoma it may appear normal but later shows evidence of pathology if repeated.^{1,2} An expanding SOL is evidenced by serial CT scans, and clinically by a three point drop in the GCS and/or progressive dilation of the pupil. The patient showed no clinical evidence of this. This underscores the need for frequent evaluations of the patient by the surgeon as rapid neurological

Deterioration can occur when an arterial laceration causes an expanding haematoma. It means the theatre should be on standby for urgent intervention during the duration of conservative management. The intervention of choice is a craniotomy to identify the haematoma, secure hemostasis and evacuate the haematoma.

The patient had a combination of favourable and unfavourable prognostic signs and had a satisfactory outcome.

REFERENCES

1. **Dawodu ST.** Traumatic Brain Injury: Definition, Epidemiology, Pathophysiology. eMedicine July 6, 2004. <http://www.eMedicine.com>.
2. **Nathoo N, Chite SH, Edwards PJ, Stat C, van Dellen JR.** Civilian Infratentorial Gunshot Injuries: Outcome Analysis of 26 Patients: Surg Neurol 2002; 58:225-33.
3. **Branvold B, Levi L, Feinsod M, George ED.** Penetrating craniocerebral injuries in the Israel involvement in the Lebanese conflict, 1982-1985; Analysis of a less aggressive approach. J Neurosurg 1990; 72:15-20.
4. **Vinas FC.** Penetrating Head Trauma eMedicine Nov 8, 2004. [Http://www.eMedicine.com](http://www.eMedicine.com).
5. **Katchy AU, Agu TC, Dabkana TM, Nwankwo OE.** Head injury in a non-neurosurgical Centre- Pattern, Management and Outcome. Orient Journal of Medicine 2000; 12:1-4 ;55-61.
6. **Onah II, Okwesili IC.** Presentation of trauma at the National Orthopaedic Hospital, Enugu: a pilot study. Tropical Doctor 2009; 39: 80-83.
7. **Carey ME.** Experimental missile wounding of the brain. Neurosurg Clin N Am 1995;6: 629-642.
8. **Roberts I, Yates D, Sandercock P, et al.** Effect of intravenous corticosteroids on death within 14 days in 10008 adults with clinically significant head injury (MRC CRASH trial): randomised placebo-controlled trial. Lancet 2004 Oct 9; 364(9442): 1321-1328.
9. **Rosenfeld J V.** Gunshot injury to the head and spine. J of Clin Neuroscience. 2002; 9(1), 9-16.
10. **Taha JM, Saba MI, Brown JA.** Missile injuries to the brain treated by simple wound closure: results of a protocol during the Lebanese conflict. Neurosurgery 1991;29:380-383.
11. **Obajimi MO, Shokunbi MT, Malomo AA, Agunloye AM.** Computed Tomography (CT) in civilian gunshot head injuries in Ibadan. WAJM 2004; 23(1): 58-61.