

CASE REPORT



Successful open surgical repair of an infrarenal, abdominal aortic aneurysm (AAA) in a young Malawian female: A case report

Geoffrey Elihu Manda¹, Peter Chaziya¹, Waluza Mwafulirwa¹, Stephen Kasenda¹ Eric Borgstein^{1,2}

1. Queen Elizabeth Central Hospital, Blantyre, Malawi
2. University of Malawi, College of Medicine, Blantyre, Malawi.

Date Received: 13 February 2017
Revision Received: 31 July 2017,
Date Accepted: 22 August 2016

Correspondence: Geoffrey Manda
(gmanda@medcol.mw)

<https://dx.doi.org/10.4314/mmj.v30i3.15>

Case Presentantion

A 39-year-old lady presented to Queen Elizabeth Central Hospital in Blantyre, Malawi with a 3-week history of worsening peri-umbilical abdominal pain radiating to the lower back associated with anorexia, nausea and vomiting. There was no history of trauma, diarrhoea, obstipation, fevers, or urinary symptoms. She reported history of "spinal surgery" done 6 years prior due to a herniated intervertebral lumbar disk. Collateral history from the primary spinal surgeon revealed that a simple laminectomy was done and the risk of causing an aneurysm was very low. Patient was not a smoker and was without other significant medical or significant family history. Systemic review was unremarkable. On physical examination, she was afebrile (36.9°C). Her height was 1.65m with a body mass index (BMI) of 23Kg/m². Abdominal examination revealed a 3cm wide by 8cm long non-tender and pulsatile mass 2cm left of the umbilicus and the rest of examination was normal. Full blood count showed a normocytic anaemia of 10 g/dl but other parameters were normal. The following tests were either normal or negative: liver and renal function tests, serum electrolytes, HIV, hepatitis B and C and syphilis serology. A trans-abdominal ultrasound scan showed an infra-renal fusiform AAA originating from left anterolateral aspect of the abdominal aorta ending just at the bifurcation of the aorta. It had a left eccentric mural thrombus (1.9cm thick and 5.4 cm long) which did not extend into either iliac arteries. There was no peri-aortic gas, fluid collection or stranding detected and the rest of the ultrasound scan was normal (Figures 1 to 4). Magnetic Resonance Imaging could not be done due to previous spine implant and Computed Tomography (CT) could not be done due to inaccessibility. Chest radiography did not show features of a dissecting thoracic aneurysm (Figure 5) and echocardiography showed a normal-sized aortic root.

Surgical Treatment

She underwent open abdominal vascular surgical repair in the absence of Percutaneous Endovascular Repair (EVAR) facilities. Midline abdominal incision was made, mesentery were reflected and bowels were mobilised. Trans-peritoneal dissection along the Treitz ligament revealed a 10cm, mobile aneurysm which was dissected free. The infra-renal aorta, external and internal iliac arteries were dissected for clamping. Proximal aorta and both iliac arteries were clamped. Aneurysm was opened and intramural thrombus

removed which was later confirmed histologically to be an organising haematoma. Both common iliac arteries showed no aneurysmal changes and were flushed with normal saline. A 26mm straight woven Dacron graft was then inserted and sutured infra-renally. Aneurysm sac was then sutured over the graft with no leaks. After 1 day of intensive care unit stay, she was moved to the general ward. Repeated imaging of the aorta was unremarkable. She was discharged on the seventh postoperative day and follow up at three months was unremarkable.

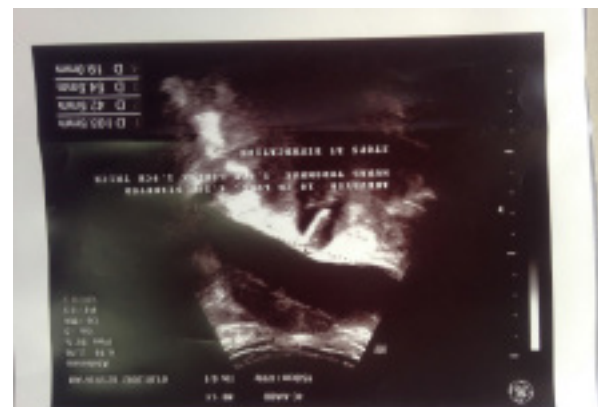

Figure 1: Aneurysm dimensions

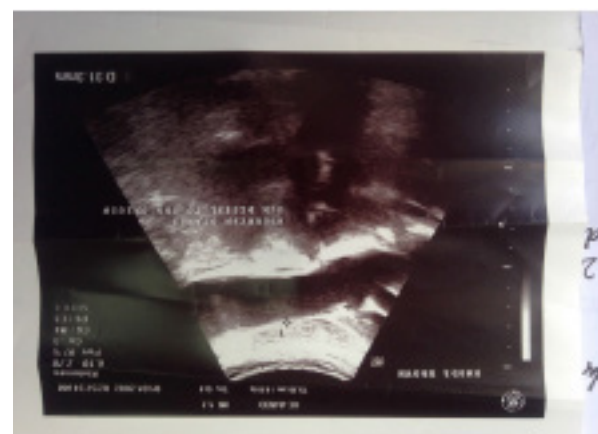

Figure 2: Aneurysm origin

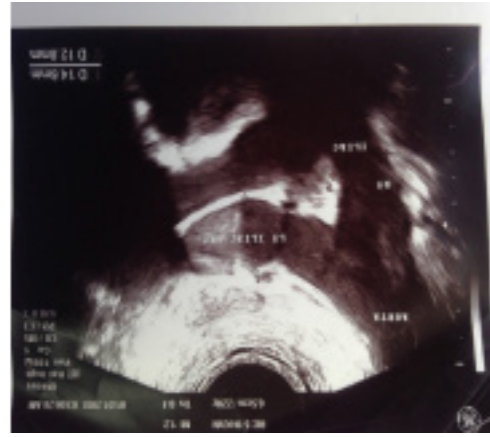

Figure 3: Common Iliac arteries spared

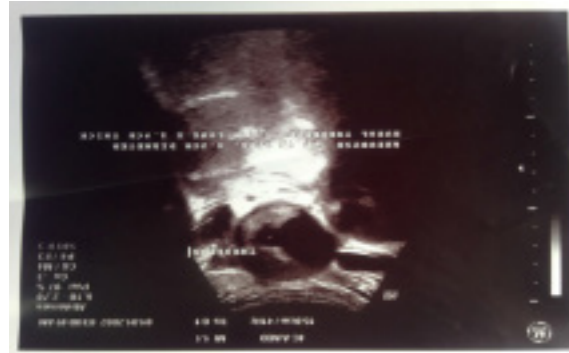

Figure 4: Mural thrombus eccentric to the left

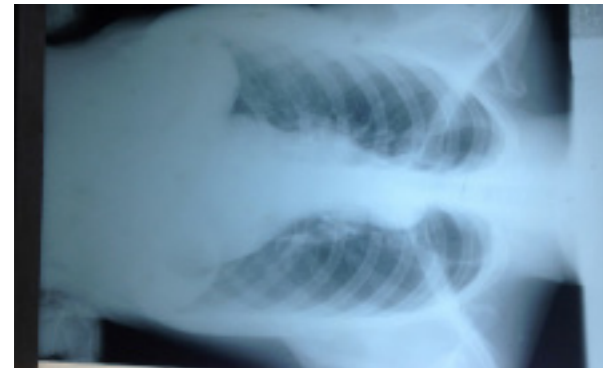


Figure 5: Normal chest radiograph

Discussion

Aortic aneurysmal disease is defined as focal dilation of the aorta at least 50% above the normal (2cm) diameter. Aortic aneurysmal disease can be classified by: location relative to renal arteries, involvement of the vessel layer walls, morphology, diameter and aetiology.¹ Abdominal aortic aneurysm (AAA) are the most common type (80%)^{2,3}. Symptoms are frequently non-specific during the early stages which may result in considerable diagnostic delays by non-suspecting clinicians¹. The true incidence of aneurysms in our setting is unknown and global epidemiology varies but the prevalence of 2.9 - 4.9 cm AAAs range from 1.3% for middle aged men to 12.5% for geriatric men and 0% and 5.2% for women respectively.^{4,5} AAA pose a risk of complications such as rupture which can prove fatal in a setting with limited vascular surgery capacity like Malawi. Based on the

2013 Global Burden of Disease study, the age-standardized death rate attributable to aortic aneurysm in 2013 was 2.6 per 100, 000⁶. The exact mechanisms underlying pathogenesis of AAA, though unclear, appear to be altered biochemical, immunological, mechanical, and genetic systems that lead to gradual proteolytic degradation of arterial vessel walls by matrix metalloproteinases such as gelatinases and matrilysin and macrophage elastase^{1,7}.

Clinical presentation in our case was unusual due to young age at presentation and lack of the typical risk factors associated with the development of AAA like advanced age, male gender, Caucasian race, a positive family history, hypertension, smoking, the presence of other large vessel aneurysms or atherosclerosis². The previous history of spinal disk herniation may suggest an underlying connective tissue disease such as Marfan syndrome, Ehlers-Danlos syndrome or Loeys-Dietz syndrome although the clinical history and examination findings did not meet a set criteria for clinical diagnosis and genetic testing for relevant mutations was not available in our setting³. Symptoms of AAA are frequently minimal during the early stages and a high index of suspicion is essential to make the diagnosis. After a diagnosis is made, the risk of rupture should be weighed against the risk of surgical complications for each patient⁸. AAAs variably dilate over time with estimated mean aneurysm growth rate for small aneurysm (3.0–5.4cm) at 2.21mm per year⁹. The five-year overall cumulative rupture rate of incidentally diagnosed aneurysms in population-based samples is 25% to 40% for aneurysms larger than 5.0 cm; thus, elective surgery is recommended for such^{2,10}. Our patient was operated early due to worsening of symptoms. Two surgical approaches can be employed; the first one is open surgical repair which is considered gold standard (operative mortality rate of 4% to 8.4%) and 5 year post-operative survival of 70% for patients ≤ 75 years old¹¹. The second approach is minimally invasive EVAR which has a 15% to 52% risk of endoleaks¹². Guidelines of the Vascular Society and the National Screening Committee (UK) recommend that asymptomatic aneurysms ≤ 4.5 cm in diameter should be followed up with ultrasound every 6 months, and those 4.5 to 5.5cm every three or six months¹³.

Conclusion

AAA, though uncommon, should be considered in any patient presenting with abdominal and lower back pains. The diagnosis of AAA can be elusive, especially when the symptoms are non-specific particularly in early phase leading to considerable diagnostic delays by non-suspecting clinicians. We recommend abdominal imaging with basic modalities like ultrasonography in the workup of abdominal pain of undifferentiated aetiology to facilitate earlier identification of these vascular problems which can timely inform definitive management. Even in the absence of EVAR, open repair remains a safe and durable option for the management of abdominal aortic aneurysms.

Conflict of interests

Eric Borgstein is the Board Chairperson of the Malawi Medical Journal but was not involved in the peer review process of this article and did not influence the decision to accept this article.

Funding

None

References

- Davey P, Wyatt M.G. (2006) Aneurysmal Disease. In: Vascular Surgery. Springer London; 2006 p. 191–219. Aggarwal S, Qamar A, Sharma V, Sharma A. Abdominal aortic aneurysm: A comprehensive review. *Exp Clin Cardiol.* 2011;16(1):11–5. PMID: PMC3076160
- Cury M, Zeidan F, Lobato AC. Aortic Disease in the Young: Genetic Aneurysm Syndromes, Connective Tissue Disorders, and Familial Aortic Aneurysms and Dissections [Internet]. *Int J Vasc Med.* 2013 [cited 2017 Jul 11].doi: 10.1155/2013/267215 Available from: <https://www.hindawi.com/journals/ijvm/2013/267215/>
- Domino FJ. The 5-Minute Clinical Consult 2011. Lippincott Williams & Wilkins; 2010. 1712 p 64-64.
- Robinson D, Mees B, Verhagen H, Chuen J. Aortic aneurysms - screening, surveillance and referral. *Aust Fam Physician.* 2013;42(6):364–9. PMID:23781541
- GBD 2013 Mortality and Causes of Death Collaborators. Global, regional, and national age-sex specific all-cause and cause-specific mortality for 240 causes of death, 1990-2013: a systematic analysis for the Global Burden of Disease Study 2013. *Lancet Lond Engl.* 2015;385(9963):117–71. doi: [https://doi.org/10.1016/S0140-6736\(14\)61682-2](https://doi.org/10.1016/S0140-6736(14)61682-2)
- Wassef M, Baxter BT, Chisholm RL, Dalman RL, Fillinger MF, Heinecke J, et al. Pathogenesis of abdominal aortic aneurysms: A multidisciplinary research program supported by the National Heart, Lung, and Blood Institute. *J Vasc Surg.* 2001;34(4):730–8. doi: <https://doi.org/10.1067/mva.2001.116966>
- Lederle FA, Wilson SE, Johnson GR, Reinke DB, Littooy FN, Acher CW, et al. Immediate Repair Compared with Surveillance of Small Abdominal Aortic Aneurysms. *N Engl J Med.* 2002;346(19):1437–44. doi: 10.1056/NEJMoa012573
- Mozaffarian D, Benjamin EJ, Go AS, Arnett DK, Blaha MJ, Cushman M, et al. Heart Disease and Stroke Statistics—2016 Update. *Circulation.* 2016;133(4):e38–360. doi: <https://doi.org/10.1161/CIR.0000000000000350>
- Karthikesalingam A, Vidal-Diez A, Holt PJ, Loftus IM, Schermerhorn ML, Soden PA, et al. Thresholds for Abdominal Aortic Aneurysm Repair in England and the United States. *N Engl J Med.* 2016;375(21):2051–9. doi: 10.1056/NEJMoa1600931
- Conrad MF, Crawford RS, Pedraza JD, Brewster DC, LaMuraglia GM, Corey M, et al. Long-term durability of open abdominal aortic aneurysm repair. *J Vasc Surg.* 2007;46(4):669–75. doi: <https://doi.org/10.1016/j.jvs.2007.05.046>
- Sun Z-H. Abdominal aortic aneurysm: Treatment options, image visualizations and follow-up procedures. *J Geriatr Cardiol JGC.* 2012(1):49–60. doi: 10.3724/SP.J.1263.2012.00049
- United Kingdom Small Aneurysm Trial Participants, Powell JT, Brady AR, Brown LC, Fowkes FGR, Greenhalgh RM, et al. Long-term outcomes of immediate repair compared with surveillance of small abdominal aortic aneurysms. *N Engl J Med.* 2002;346(19):1445–52. doi: 10.1056/NEJMoa013527