

Case Report: A child with acute lymphocytic leukaemia

R Bonanthaya^{1*}, L.Appaji² and K.C.Lakshmaiah¹

1. Department of Medical Oncology, Kidwai Memorial Institute of Oncology, Bangalore, India.

2. Department of Paediatric Oncology, Kidwai Memorial Institute of Oncology, Bangalore, India.

* Corresponding author: Ravikiran Bonanthaya ravikiran.bonanthaya@gmail.com

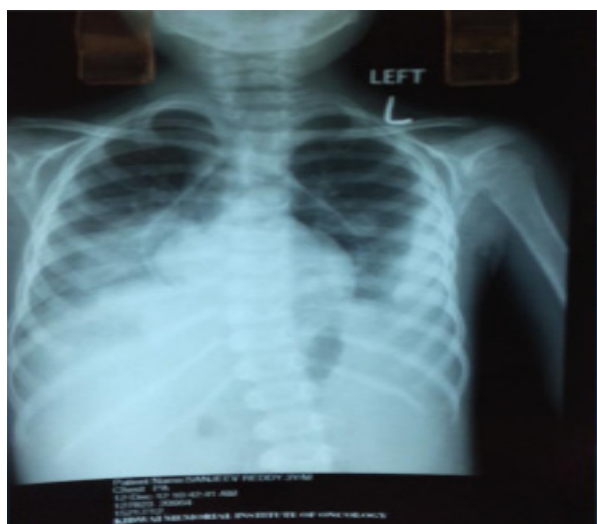
The patient was a child aged 5 years who had been diagnosed to have acute lymphocytic leukemia (ALL). Chemotherapy was given with wysolone, vincristine, daunomycin, l-asparaginase, and intrathecal methotrexate. In addition he was given fluconazole and co-trimoxazole to cover infections during the induction period of the chemotherapy).

During the second week after the start of treatment he complained of pain on the right lower chest. On examination, there was tenderness in the right 6th and 7th intercostal spaces. Breath sounds there were normal and there were no adventitious sounds. The following day he had cough and fever and continuing chest pain, and now a right basal pleural rub could be heard on auscultation. Over the next few days his condition worsened and he developed tachypnoea and dullness to percussion with crackles over the right lower chest. Chemotherapy drugs were temporarily discontinued.

The following test results were available: [Hb]6.8 g/dl; total lymphocyte count 500/ul; platelets 24,000/ul; blood taken for culture and sensitivity: initially this yielded no growth, and a further blood sample was taken for culture. Throat swab culture showed growth with *Klebsiella pneumoniae* resistant to all antibiotics except tigicycline. The second blood culture yielded a methicillin-resistant *Staphylococcus aureus* (MRSA).

Treatment over the next few days included oxygen and a variety of antibiotics. Blood products were transfused. He continued to have fever spikes.

Chest x ray: showed consolidation in the right middle and lower zones, with left pleural effusion



Discussion

Broncho alveolar lavage (BAL) revealed no fungal growth. A cardiologist consulted about the pneumopericardium advised no particular measures, except for careful and frequent observations and continuation of antimicrobial therapy.

After a further 20 days of treatment the patient improved, chest signs disappeared, the temperature fell, and chemotherapy for ALL was resumed. There was full remission of leukaemia upon completion of the induction phase of chemotherapy.

Pneumopericardium in the paediatric age group is a rare condition attributed to trauma during intubation, blunt injury to the chest, or to a variety of infections, notably pulmonary aspergillosis, pulmonary tuberculosis and *Pneumocystis jirovecii* pneumonia (PCP).

We have presented a case of pneumopericardium in a 5 year old boy suffering from acute lymphocytic leukemia (ALL) and undergoing chemotherapy for the same. Any of the infections mentioned above could have contributed to pneumopericardium in this patient, who was likely to be immunosuppressed as a result of the underlying leukaemia and/or the chemotherapy he was receiving.

The cause of the spontaneous pneumothorax remains uncertain in this patient. Bronchoalveolar lavage (BAL) did not yield any fungal material, pneumocystis or mycobacteria, and blood culture grew *Staphylococcus aureus*. The patient was treated with both antibiotics and antifungals, and finally achieved resolution of the pneumopericardium and clinical improvement.

Pneumopericardium does not usually require any specific treatment, apart from careful observation and management of the underlying putative cause, when the air around the heart is usually reabsorbed over the course of a few days.

Disclosures:

The authors have nothing to disclose and there are no conflicts of interest.

References

- Mansfield PB, Graham CB, Beckwith JB, Hall DG, Sauvage LR: Pneumopericardium and pneumomediastinum in infants and children. *J Pediatr Surg* 1973, 8:691-699.
- Brander L, Ramsay D, Dreier D, Peter M, Graeni R: Continuous left hemidiaphragm sign revisited: a case of spontaneous pneumopericardium and literature review. *Heart* 2002, 88:5.
- Haan JM, Scalea TM: Tension pneumopericardium: a case report and a review of the literature. *Am Surg* 2006, 72:330-331.
- Abdalla M, Gould L, Bharathan T. Spontaneous pneumopericardium: A case report. *Angiology* 1994;45:81-3.
- Bartal N, Zaarura S, Marvan H. Spontaneous pneumo-pericardium and pneumomediastinum. *Ann Otol Rhinol Laryngol* 1990;99:1005-6.
- Lonsky V, Mandák J, Harrer J, Tuna M, Dvorak P, Dedek T, et al. Posttraumatic pneumopericardium: A sign of severe injury or radiodiagnostic rarity. *Acta Medica (Hradec Kralove)* 2006;49:129-32.
- Baharudin A, Sayuti RM, Shahid H. The Macklin effect-pneumomediastinum and pneumopericardium following blunt chest trauma. *Med J Malaysia* 2006;61:371-3.

8. Capizzi PJ, Martin M, Bannon MP. Tension pneumopericardium following blunt injury. *J Trauma* 1995;39:775-80.
9. Ladurner R, Qvick LM, Hohenbleicher F, Hallfeldt KK, Mutschler W, Mussack T. Pneumopericardium in blunt chest trauma after high-speed motor vehicle accidents. *Am J Emerg Med* 2005;23:83-6.
10. Markarian MK, MacIntyre DA, Cousins BJ, Fildes JJ, Malone A. Adolescent pneumopericardium and pneumomediastinum after motor vehicle crash and ejection. *Am J Emerg Med* 2008;26:515.e1-2.
11. Merino JM1, Díaz MA, Ramírez M, Ruano D, Madero L. Complicated pulmonary aspergillosis with pneumothorax and pneumopericardium in a child with acute lymphoblastic leukemia. *Pediatr Hematol Oncol*. 1995 Mar-Apr;12(2):195-9.