

Ward Round - An acute abdominal emergency

David O. Irabor¹, Alaba A. Adesina²

1. College of Medicine University of Ibadan, Nigeria
2. University College Hospital Ibadan, Nigeria

Correspondence To: dirabor@comui.edu.ng, irabordavid@yahoo.com

Case Report

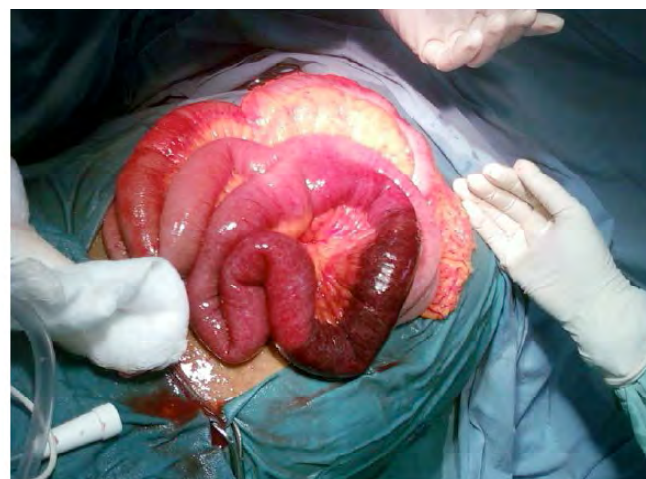
A 32 year old unemployed male was brought into the Accidents and Emergency Department of the University College Hospital, Ibadan, with a 2-day history of severe generalized abdominal pain, fever, vomiting and abdominal distension. He had been previously well until 2 days prior to presentation when he had abdominal pain with loose stools. He went to a general practitioner and anti-ulcer drugs plus metronidazole tablets were prescribed. His condition did not improve and he developed a fever, became constipated and his abdominal girth started increasing with worsening of the pain.

Examination at the emergency department showed a young adult male who looked acutely ill, he was febrile but not pale or jaundiced. His tongue was dry and coated with brownish material. The main findings were on abdominal examination; his abdomen was distended, tense and generally tender. There was a vague mass in the left iliac fossa which was tender. Auscultation revealed a silent abdomen. Rectal examination only yielded some mucus but not blood.

The diagnosis entertained was of a perforated left-sided colon cancer with differentials of typhoid perforation or perforated amoebic colitis. Plain abdominal x-rays ordered showed dilated small bowel with multiple air/fluid levels with an isolated loop of gas-filled bowel on the left side. A consideration of small bowel volvulus was also entertained at that juncture.

He was resuscitated and had an emergency exploratory laparotomy. Findings at surgery showed a 20cm length of jejunum that was a dusky red colour with a clear-cut demarcation between the affected part and a less erythematous but still rather hyperaemic part of the jejunum (Figure 1). The involvement of the mesentery of the affected part was also evident as a triangular thickened segment was also dusky-red. There were no enlarged mesenteric lymph nodes and there was about 500ml of serous peritoneal fluid. He had jejunal resection with end to end anastomosis using 3-0 Vicryl suture in 2 layers. He had an uneventful post-operative course and recovered bowel functions on the 4th post-operative day. He was discharged on the 9th post-operative day. The histopathology report of the resected small bowel stated 'acute on chronic jejunitis with peritonitis'. He has been seen for follow-up several times at the surgical outpatient clinic and he remains in good health.

What is the likely diagnosis?



Appearance of small gut at laparotomy. Note the sharply demarcated affected segment of bowel

Discussion

A localised segmental inflammation of a length of bowel with these appearances at laprotomy is highly suggestive of necrotizing enteritis due to infection with *Clostridium perfringens* type C.

This condition is otherwise known as pig-bel.

This syndrome was first described in Germany in the 1940s where the name 'Darmbrand' was coined. Darmbrand literally means 'burnt intestine'. In the early 1960s this syndrome was recognized as a common condition in Papua New Guinea (PNG) where it affected young adults and children. The introduction of the *Clostridium perfringens* was traced to poorly cooked meat especially pork¹, hence the name 'pig-bel'.

With the improvement in standards of living and hygiene after the world war, these cases disappeared from Germany, but in several countries including Thailand, PNG, Uganda and Ghana cases have been identified^{2,3,4}. To our knowledge this is the first report of Pig-bel disease in Nigeria. Poor cooking hygiene, especially of meat, predisposes to the proliferation of *Clostridium perfringens* type C1. This organism produces a β -toxin which has severe necrotising effects on tissues^{1,4}.

C perfringens type C is normally present in pig intestine and is also excreted in pig faeces^{5,6} thus poorly cooked pork was touted to be the main cause of pig-bel in PNG where it reached epidemic proportions in the early 1960s. Nonetheless, pork ingestion has been shown not to be the cause in some cases as this disease has occurred in patients following ingestion of raw sweet potato, peanuts and water chestnuts. Such incidents have been reported in vegetarians in England and Northern India^{5,7}.

Not all patients who ingest the C perfringens-contaminated meat develop the classical disease; an important catalyst in the development of this disease is a low trypsin activity in the intestinal contents⁵. Ingestion of foods containing antitrypsins e.g. sweet potato, soybean and peanut sauce coupled with a low protein diet is believed to interfere with the ability of the small gut to inactivate the toxin⁵. This is why some authors state that excessive eating of rich food by a malnourished population is an important causative factor

in the development of necrotising enteritis⁶.

The disease presents as a case of a surgical abdomen, with severe abdominal pain, vomiting, fever and bloody diarrhoea in some cases. If untreated it progresses to segmental ischaemic enteritis^{6,8} which may lead to gangrene of the affected segment with toxæmia, shock and death. The diagnosis is usually difficult to make pre-operatively (especially in non-endemic areas); thus it is at exploratory laparotomy that the segmental affectation of the jejunum or ileum is seen. Some areas may be frankly gangrenous. Many patients will require resection and anastomosis. In one study of 30 patients over a 5-year period, the jejunum was shown to be the most common site affected (63%) followed by the ileum (27%)⁸.

Our patient made a full recovery and it is possible that he may now have developed immunity to the disease: it has been shown that, after a vaccination programme against *Clostridium perfringens* type C was commenced in PNG in 1980, the admissions for pig-bel disease dropped to about one-fifth by 1984-1986⁹.

Key words: pig-bel, necrotizing enteritis, darmbrand

References

1. Sobel J, Mixter CG, Kolhe P, Gupta A, Guarner J, Zaki S et al. Necrotising enterocolitis associated with *Clostridium Perfringens* type A in previously healthy North American adults. *J Am Coll Surg* 2005; 201; 48-56.
2. Wright DH, Stanfield JP. Enteritis necroticans in Uganda. *J Pediatr* 1967; 71; 264-268.
3. van Erik A, van der Esch EP. Enteritis necroticans in Agogo, southern Ghana. *Trop Geogr Med* 1973; 25; 313-324.
4. Murrell TG, Walker PD. The Pigbel story of Papua New Guinea. *Trans Roy Soc Trop Med Hyg* 2001; 1; 119-122.
5. Farrant JM, Traill Z, Conlon C, Warren B, Mortensen N, Gleeson FV, Jewell DP. Pigbel-like syndrome in a vegetarian in Oxford. *Gut* 1996; 39; 336-337.
6. Severin WPJ, de la Fuente AA, Stringer MF. *Clostridium Perfringens* Type C causing necrotising enteritis. *J Clin Pathol* 1984; 37; 942-944.
7. Gupta SC, Mishra V, Mishra SP, Gupta AK, Keshwani NK. Necrotising enteritis simulating Pigbel disease in Northern India. *Indian J Gastroenterol* 1994; 13; 109-111.
8. Singh G, Narang V, Malik AK, Khanna SK. Segmental enteritis: "Enteritis necroticans": a clinicopathologic study. *J Clin Gastroenterol* 1996; 22; 6-10.
9. Lawrence GW, Lehmann D, Anian G, Coakley CA, Saleu G, Barker MJ, Davis MW. Impact of active immunisation against enteritis necroticans in Papua New Guinea. *Lancet* 1990; 336; 1165-1167.