

East African Medical Journal Vol. 95 No. 3 March 2018

### CORRECTED BLADDER EXSTROPHY- CAESAREAN BIRTH: CASE REPORT

Omar Kadra, Department of Obstetrics and Gynecology, University of Nairobi, Nairobi, Kenya, I.S.O. Maranga, Department of Obstetrics and Gynecology, University of Nairobi, Nairobi, Kenya, Department of Reproductive health, Kenyatta National Hospital, Nairobi, Kenya, E. Cheserem, Department of Obstetrics and Gynecology, University of Nairobi, Nairobi, Kenya, Department of Reproductive health, Kenyatta National Hospital, Nairobi, Kenya, P.A. Owende, Department of Obstetrics and Gynecology, University of Nairobi, Nairobi, Kenya, Department of Reproductive health, Kenyatta National Hospital, Nairobi, Kenya

Corresponding author: A.O. Kadra, Department of Obstetrics and Gynecology, University of Nairobi, Nairobi, Kenya

## CORRECTED BLADDER EXSTROPHY- CAESAREAN BIRTH

A.O. Kadra, I. S. O. Maranga, E. Cheserem and P. A. Owende

### ABSTRACT

**Case Summary:** We present a case of 26 yrs old Primigravida, who presented at the antenatal clinic of Kenyatta National Hospital at 20 weeks gestation, she was a known case of congenital bladder exstrophy. Patient was diagnosed with bladder exstrophy at birth and underwent a total of 3 bladder surgeries, has had suprapubic catheter for the last 15 years and underwent vaginoplasty and vaginal dilatation for vaginal atresia, and she has conceived naturally.

### INTRODUCTION

Bladder exstrophy (BE) is an anterior midline defect resulting into complex genitourinary malformation which require complex surgical management.<sup>1, 3</sup> The defect involves the infraumbilical abdominal wall including the pelvis, urinary tract, and external genitalia resulting in the exposure of the distal urinary tract to the outer abdominal wall.<sup>1, 3</sup> The surgical reconstructions for BE and their outcomes have improved with time resulting in higher survival rates.<sup>1,3</sup>

### CASE REPORT

We hereby report a case of 26 years old primigravida who presented at the Antenatal

clinic of Kenyatta National Hospital at 20 weeks gestation; she was a known case of bladder exstrophy.

She was diagnosed with bladder exstrophy at birth, and underwent a total of 3 bladder surgeries, She has had a suprapubic catheter for the last 15 years, and underwent vaginoplasty for vaginal atresia three years ago followed by two vaginal dilatation procedures three months later. Her menses had been regular since her menarche at 12 years of age.

In a pelvic ultrasound done 5 months after vaginal dilatation, the bladder was not visualized though the uterus was normal with no clear endomyometrial demonstration. The upper abdominal scan was unremarkable. Six months following these procedures, a

hysterosalpingography demonstrated a normal uterus with patent tubes.

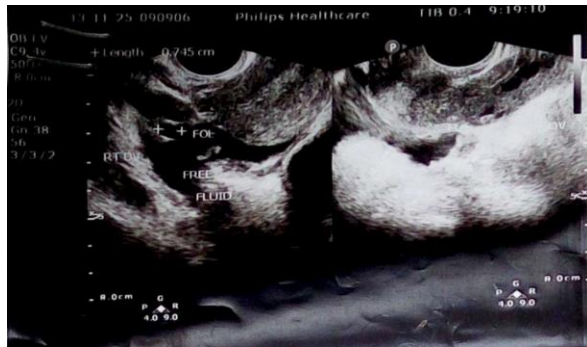

Figure A: Right ovary, follicle at the ovary

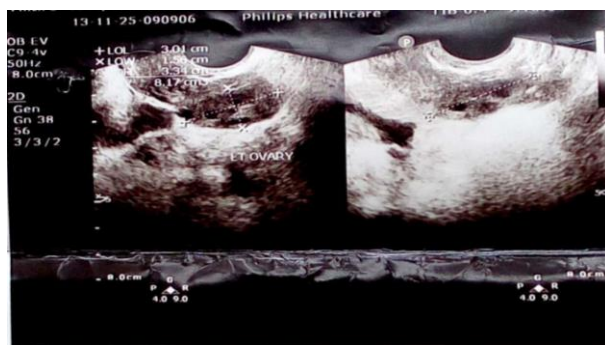

Figure B: left ovary

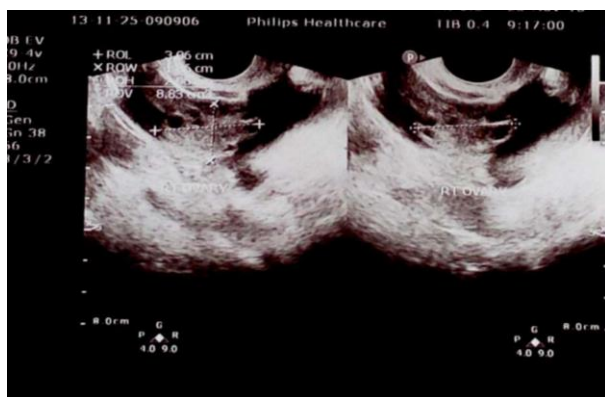

Figure C: right and left ovaries (though bladder was not visualized, other abdomino-pelvic organs were normal)

During her first visit to the ANC the patient was at 20 weeks gestation, an obstetric Ultrasound done six days prior to this visit revealed a single viable intrauterine

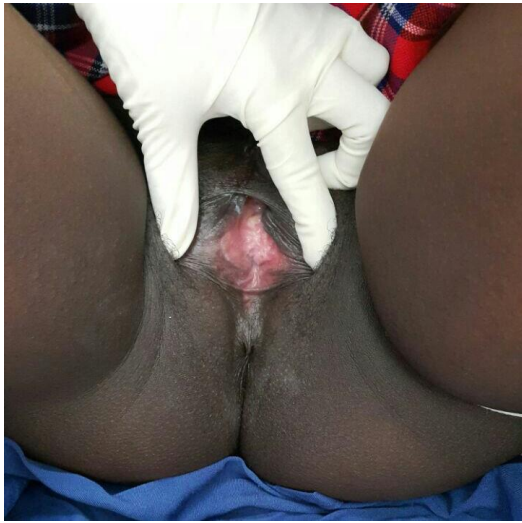
pregnancy in breech presentation at 20 weeks with no fetal anomalies. However, maternal bilateral hydronephrosis and hydroureter was demonstrated.

Urinalysis (Catheter specimen) had leucocytes (3+) and ketonuria 2+. Her antenatal profiles were normal with a Hemoglobin level of 11.2g/dl, Blood group A positive, HIV and Syphilis tests were both negative. Her mode of delivery being caesarean section at term was discussed with her, the planned abdominal incision being midline with a classical incision on the uterus so as to avoid undoing the urological correction procedures that had been done earlier.

At 32 weeks gestation, she was admitted with pyelonephritis and was treated with intravenous antibiotics with good response. At 33 weeks she had preterm rupture of membranes which was managed as per protocol of Kenyatta National Hospital. An emergency c-section was done after having giving dexamethasone, and a live female infant was delivered with birth weight of 1.4kg, with an Apgar score of 6<sup>1</sup>/8<sup>5</sup>/9<sup>10</sup> and no congenital anomalies were noted. The baby was admitted to newborn unit due to low birth weight and respiratory distress, where she did well and was discharged with a weight of 1.80kg.

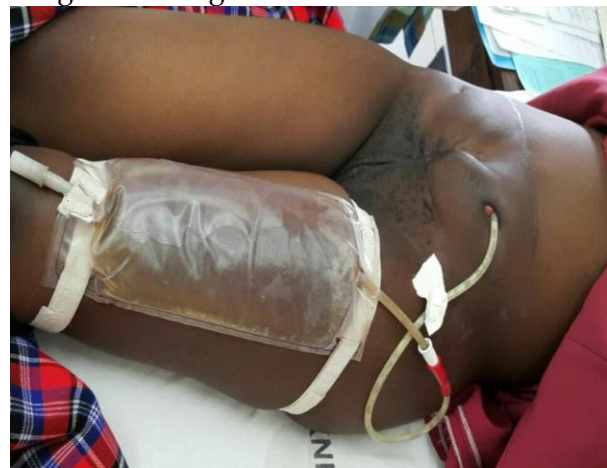

Figure D: supra-pubic catheter



**Figure E: bifid clitoris, buried urethra.**  
(Images taken with written patient's permission)

## DISCUSSION

Bladder exstrophy (BE) is an anterior midline defect with variable expression involving the infraumbilical abdominal wall including the pelvis, urinary tract, and external genitalia resulting in the exposure of the distal urinary tract to the outer abdomen. Its incidence varies from 1:30,000–1:50,000 live births.<sup>1</sup> It begins in the fourth week of gestation due to the failure of mesenchymal cells to migrate between the ectoderm of the abdomen and the cloaca, and results in eversion of bladder on the abdominal surface, divergence of pubis, abnormal external genitalia, and inferiorly displaced umbilicus.<sup>2</sup>

This patient underwent multistage bladder and pelvic reconstructive operations. With the history of multi-staged bladder and pelvic reconstruction operations in these kind of patients, obstetric management presents a big challenge which needs to be addressed by Obstetrician and Urologist.<sup>3</sup> Delivery of this patient including type of incision at the surgery was planned during her antenatal visits. Preconceptional renal evaluation with

regular follow up in antenatal period should be mandatory.<sup>3</sup> Planned Caesarean delivery at term is appropriate mode of delivery which allows for timely planning and expert opinion.<sup>3</sup> Its clinical characteristics vary from simple to most complex forms such as cloacal exstrophy<sup>4</sup>.

Renal abnormalities, such as agenesis, hydronephrosis, multicystic dysplastic kidney, or hydroureter, have been described in 60% of patients<sup>2</sup>, bifid genitals are frequent and BE is frequently associated with other congenital malformations.<sup>3</sup> In males the penis is short, stubby, curved upwards and is drawn into the exstrophic area.<sup>5</sup> Unilateral or bilateral cryptorchidism may be present with an associated inguinal hernia.<sup>5</sup> In females, the urethra is short, often buried in the exstrophied bladder and the clitoris tends to be bifid, the labia are also widely separated. The vagina is short and orifice may be stenotic, uterine prolapse or unicornuate uterus may be present.<sup>5, 6</sup> Anus is anteriorly placed and may be patulous, and this is more commonly seen in girls. Distal ends of ureters are slightly dilated, and curved laterally, then medially and slightly upwards in the shape of a hook before the bladder.<sup>5, 6</sup> In this patient as shown in figure (E), the identified abnormalities include bifid clitoris, buried urethra.

Women treated for BE are capable of having normal children, as evidenced in this case, whereby albeit preterm had a successful outcome. These pregnancies require a great demand of attention from the physicians since they are complex cases.<sup>1</sup>

In terms of sexuality, the beginning of sexual activity is usually delayed. Emotional disturbance due to their body image like genital appearance and size causes dissatisfaction, but nearly three fourth of both female and male patients with BE experience

normal orgasm with partner's satisfaction.<sup>7</sup> Though these were not assessed in this patient, her pregnancy is testament that she was engaging in coitus but satisfaction was not determined. Studies done have shown that both sexes have a feeling of insecurity and worry about their sexual relationships and its long-term stability.<sup>7</sup>

Most females with BE have normal libido and are adequately sexually active, the short and vertically lying vagina may need vaginoplasty as was the case in this patient for normal sexual intercourse. The menstruations are mostly normal,<sup>8</sup> just as described in the history and clinical findings of this case. The associated problems which adversely affect the sexual activity are leakage of urine during sexual intercourse and lack or reduction of clitoral sensation as well as dyspareunia and genital prolapse.<sup>8,9</sup>

Female patients with BE have normal fertility compared to males, because their genital reconstruction is not as complex as in the male.<sup>7,8</sup> however the fertility problems reported in some of the patients were secondary to extensive pelvic surgeries and tubal injuries.<sup>8,10</sup>

#### REFERENCES

1. Martins Giron A, Carlo Camargo P, Hiep Nguyen, et al, Bladder exstrophy: reconstructed female patients achieving normal pregnancy and delivering normal babies, *International Braz J Urol*, Vol. 37 (5): 605-610, September - October, 2011.
2. Seyfettin U, Onur , Murat A, et al, Bladder Exstrophy, Fetal and Pediatric Pathology, 31:225–229, 2012.
3. Akhilesh G, Nandkishor B, Prashant E, et al, A case of pregnancy in patient with reconstructed bladder exstrophy, *International J. of Healthcare and Biomedical Research*, Volume: 03, Issue: 02, January 2015.
4. S. Gupta, R. Gupta, S.Saraf, et al, Primarily Closed Bladder Exstrophy in a Female Patient Complicated by a Bladder Calculus and Squamous Cell Carcinoma-A Rare Presentation, *JK SCIENCE*, Vol. 12 No. 3, July-September 2010.
5. Shah AK, Joshi MA, Kumar S, Bladder Exstrophy- A case report, *Ind J Radiol Imag* 2006 16:1:103-106.
6. Ashwin V, Rajat S, Bladder Exstrophy, *People's Journal of Scientific Research*, Vol.2(2), July 2009.
7. Diseth TH, Bjordal R, Stange M, et al, Somatic function, mental health and psychosocial functioning in 22 adolescents with bladder exstrophy and epispadias, *J Urol*.1998;159:16684-90.
8. Ben-Chaim J, Jeffs RD, Reiner WG, et al, The outcome of patients with classic bladder exstrophy in adult life.*J Urol*.1996;155:1251-2.
9. Shapiro E, Lepor H, Jeffs RD, The inheritance of the extrophyepispadias complex.*J Urol*.1984;132:308-10.
10. Woudhouse CR, Prospects for fertility in patients born with genitourinary anomalies.*J Urol*.2001;2354-60.