

*East African Medical Journal Vol. 91 No. 11 November 2014*

## AN UNUSUAL CASE OF RECTAL FOREIGN BODY: CASE REPORT

J. G. Ondieki, MBChB, MMed, Consultant General Surgeon, Nazareth Hospital, P. O. Box 100510-00100, Nairobi and D. Kiptoon, MBChB, MMed, Consultant General Surgeon and Lecturer, Department of Surgery, College of Health Sciences, University of Nairobi, P. O. Box 19676-00202, Nairobi, Kenya

## AN UNUSUAL CASE OF RECTAL FOREIGN BODY: CASE REPORT

J. G. ONDIEKI and D. KIPTOON

### SUMMARY

**Foreign bodies within the rectum are an infrequent occurrence with a wide variety of objects either inserted or swallowed. Many techniques of removal have been described to remove these objects in case series mainly in developed countries. We report a case of unusually large rectal foreign body we managed by sigmoidotomy with primary closure.**

### INTRODUCTION

Foreign bodies within the rectum are an infrequent occurrence. The variety of objects either inserted or swallowed and lodge in the rectum is wide. Consequently many techniques of removal have been described to remove these objects (1).

### CASE REPORT

A 52 year old male patient presented in our surgical unit with a history of assault and insertion of a water glass into the rectum two days prior. He reported several attempts of removal at home without success. He had associated absolute constipation and abdominal discomfort but had no abdominal pains or vomiting. He reported no fever and had not passed blood per anal.

On examination, we found a middle aged man in good nutritional status, well hydrated and not febrile. The abdomen was flat, non-tender with a palpable firm object in the left iliac fossa. Rectal examination revealed bloody mucoid discharge, rectal tenderness but the object was non palpable.

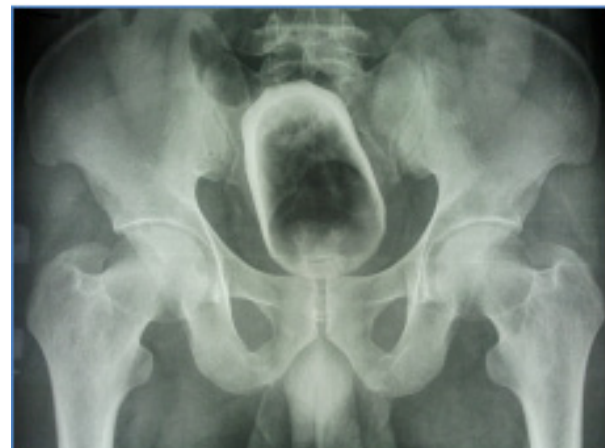A plain abdominal radiograph (Figure 1) showed a water glass in the pelvis around the rectal sigmoid junction with part of the brim broken. There was no evidence of free intra-peritoneal air. Haemogram and electrolyte results were normal.

The patient was advised on a plan for examination under anaesthesia to attempt trans-anal removal and the possibility of a laparotomy with or without a

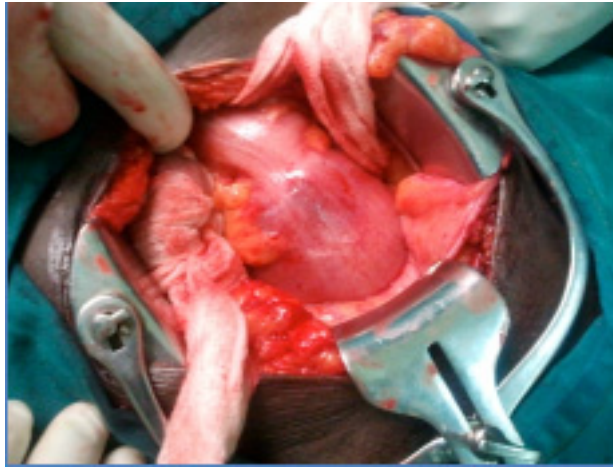
colostomy if the above fails. He consented for the procedure. Under general anaesthesia, with the patient in lithotomy position, attempts were made to massage the object distally for direct visualisation and removal but this was unsuccessful. Laparotomy was performed via a sub-umbilical midline incision and found the object in the rectal sigmoid junction (Figure 2). Through a sigmoidotomy along the *taenia coli* and well packed surrounding to minimise contamination, the glass was removed (Figure 3). There was no evidence rectal perforation or ischaemic recto-sigmoid wall. The sigmoidotomy was closed in two layers with continuous polyglatin 3.0 suture.

**Figure 1**

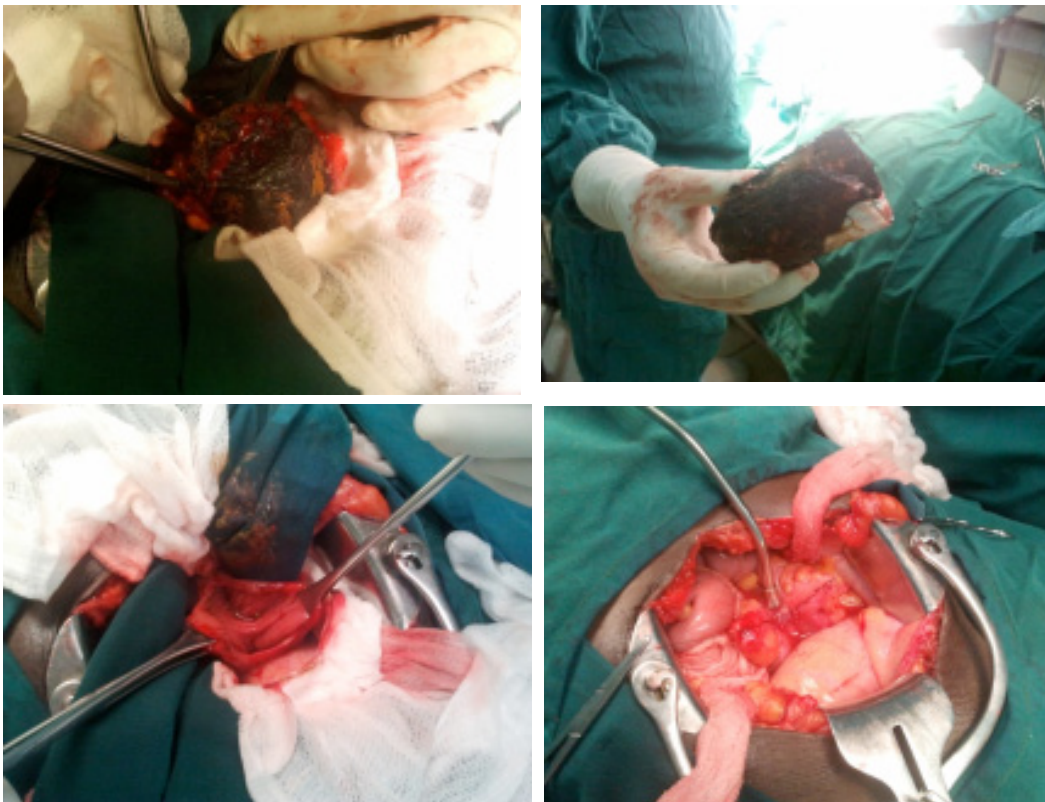
*Pelvic x-ray showing the foreign body*



**Figure 2**  
*Object as seen in surgery*



**Figure 3**  
*Removal of the object and closure of the sigmoidotomy*



Post-operatively, we administered antibiotics for five days, started oral fluids on the second day and full diet on day three. He had uneventful recovery and was discharged on the seventh day. On review two weeks later in the clinic, the laparotomy wound had healed well and he reported no complication.

## DISCUSSION

There are reports on rectal foreign bodies discussed in medical literature sporadically over many years. These are mainly case reports or series from developed countries (1, 2) with a few reports on the same published from Africa (3, 4). The affected age group

ranges from 16-80 years with two peaks observed in the twenties due to anal erotism and in the sixties mainly due to prostatic massage and breaking faecal impactions (1, 5).

In the vast majority of cases rectal foreign bodies are inserted as a result of erotic activity. These objects include dildoes or vibrators, light bulbs, candles, shot glasses, soda or beer bottles (6). However, some rectal foreign bodies such as toothpicks, popcorn, bones are initially swallowed and then transit through the gastrointestinal tract while others are as a result of assault or concealment (4).

These patients usually present because of pain, often after multiple attempts to remove the object. Presentation is almost always delayed because of embarrassment (6). They may also present with rectal pain or bleeding. If perforation has occurred, they may report fever, vomiting, and severe abdominal or rectal pain (7).

The patient evaluation should include an abdominal and rectal examination. Low lying foreign bodies will be palpable per rectal but if above the recto-sigmoid junction or more than ten centimetres from the anal verge, they may only be palpated on abdominal examination. High suspicion of the possibility of a large bowel perforation should be maintained in delayed presentations (4, 6, 7). Plain abdominal radiography or water soluble contrast enemas may be helpful to localise the object.

Bowel perforation warrants an immediate laparotomy but if there are no signs of perforation, several management approaches can be tried depending on the object and its location. Low lying objects may be removed under direct visualisation with the patient under sedation or general anaesthesia. This is aided by insertion of a rectal or vaginal speculum and grasping the foreign body with ring forceps or tenaculum forceps. Foley catheter inflation may be used to reduce the vacuum created between the object and rectal wall hence allowing removal.

High placed large objects, like in our case, usually warrant a laparotomy and a colotomy. The decision whether to create a proximal stoma or close the stoma depends on the visual assessment of the gut and the general condition of the patient (4). Most of the reported cases that required a laparotomy also required a diverting colostomy (2, 4). However, in selected patients it is possible to close the colotomy primarily as in our case and the two from the series reported by Clarke *et al* (4).

In conclusion, rectal foreign bodies, although not common in our setup, can present with unusually large objects that may require a laparotomy for removal. In select cases, it is possible to close the colotomy primarily with good outcome.

## REFERENCES

1. Rodriguez-Hermosa J.I, Codina-Cazador A., Ruiz B., *et al*. Management of foreign bodies in the rectum. *Colorectal Dis*. 2007; **9**:543-548.
2. Ooi B.S., Ho Y.H., Eu K.W., *et al*. Management of anorectal foreign bodies: a cause of obscure anal pain. *Aust N Z J Surg*. 1998; **68**:852-855.
3. Narjis Y., Rabbani K., Hakkou K., *et al*. Foreign body of the rectum: An unusual case. *J Emerg Trauma Shock*. 2010; **3**:306.
4. Clarke D.L., Buccimazza I., Anderson F.A., *et al*. Colorectal foreign bodies. *Colorectal Dis*. 2005; **7**:98-103.
5. Koornstra J. J. and Weersma R.K. Management of rectal foreign bodies: description of a new technique and clinical practice guidelines. *World J Gastroenterol*. 2008; **14**:4403-4406.
6. <http://emedicine.medscape.com/article/776795> accessed on 26/12/12.
7. Lake J.P., Essani R., Petrone P., *et al*. Management of retained colorectal foreign bodies: predictors of operative intervention. *Dis Colon Rectum*. 2004; **47**:1694-1698