

East African Medical Journal Vol. 90 No. 12 (Supplement) December 2013

OSTEOPAENIA AND OSTEONECROSIS IN HIV INFECTION: REPORT OF TWO CASES

E. O. Omonge, MBChB, MMed(Intl Med), C. F. Otieno, MBChB, MMed(Int.Med), Associate Professor, M. C. Maritim, MBChB, MMed, DT Med H, Senior Lecturer, C. S. Ilovi, MBChB, MMed(Int.Med), L. Achieng, MBChB, MMed(Int.Med) Department of Clinical Medicine and Therapeutics, College of Health Sciences, University of Nairobi, P. O. Box 19676-00202, Nairobi and A. E. O. Otedo, MBChB, MMed(Int.Med), Cert. Gastroenterology, Kisumu East District Hospital, P.O. Box 4685-40103, Kisumu, Kenya

Request for reprints to: Dr. E. O. Omonge, Lecturer, Department of Clinical Medicine and Therapeutics, College of Health Sciences, University of Nairobi, P. O. Box 19676-00202, Nairobi, Kenya, email:omongedr@yahoo.com

OSTEOPAENIA AND OSTEONECROSIS IN HIV INFECTION: REPORT OF TWO CASES

E. O. OMONGE, C. F. OTIENO, M. C. MARITIM, C. S. ILOVI, L. ACHIENG and A. E. O. OTEDO

SUMMARY

The introduction in the mid 1990's of highly active anti-retroviral drugs therapy (HAART) in the treatment of human immunodeficiency virus (HIV) infection has significantly changed the course, manifestation of HIV disease and improved the life expectancy of HIV infected patients .

The consequence of longer survival has manifested increasing rates of co-morbid diseases and aroused interest in the interaction of HIV and aging

The pathogenesis of the resultant conditions though not fully understood is likely multifactorial and may be related to direct effect of the HIV virus and associated immunodeficiency, underlying opportunistic events, immunoactivation ,related vasculopathies and inflammatory processes and toxic effects of anti-retroviral agents

Bone disorders as such osteopaenia, osteoporosis and bone fractures, osteonecrosis and accompanying metabolic changes, has been reported with increasing frequency.

We report two cases of patients known to be HIV positive and on HAART who presented with hip pain. The first patient had radiological evidence of osteonecrosis (avascular necrosis) of the head of femur, and second patient who presented with acute sudden onset pain had fracture of the neck of femur.

Literature is reviewed to elucidate possible mechanism of disease and a brief consideration of possible therapy is discussed.

CASE REPORT 1

AKN, a 38 year old HIV positive black male presents with one month's history of left hip pain. Over the last 6 days he has noted increasing intensity of this pain with associated radiation to the buttock and left inner thigh. The pain is unbearable on exerting weight and he has significant limitation of movement.

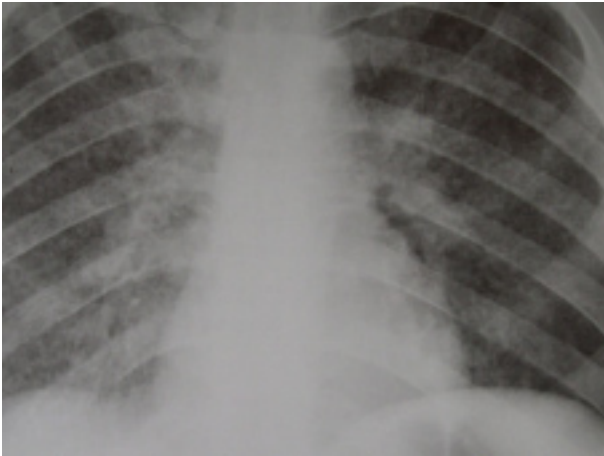
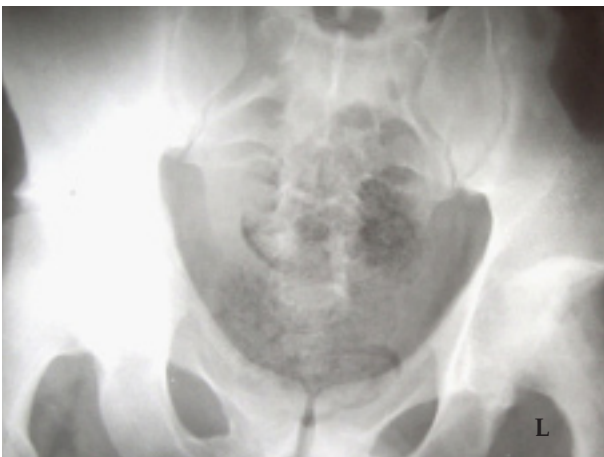AKN was treated for pulmonary tuberculosis five years ago with and intensive phase of rifampicin, isoniazid , pyrazinamide and ethambutol for two months followed by four months of rifampicin and isoniazid in the continuation phase.

He tested positive for HIV two years ago following admission to hospital with history of shortness of breath, fever, and non-productive cough chest pain and weight loss. During that admission, laboratory test revealed anaemia of 8.5gm/dl, leucocytosis of $19.6 \times 10^9/l$. His creatinine

was $156 \mu\text{mol/l}$ with both alanine aminotransferase and aspartate aminotransferase 2.5 x above normal values. LDH was not done. CD4+ was 137/ml by flow cytometry , with both hepatitis B and C markers screening negative.

A chest radiograph was suggestive of military tuberculosis and with a differential diagnosis of pneumocystis pneumonia. The patient was retreated with anti-tuberculosis drugs and empirically given high dose trimethoprim/sulfamethoxazole and prednisone for three weeks. He improved and was discharged home for follow up in the HIV clinic.

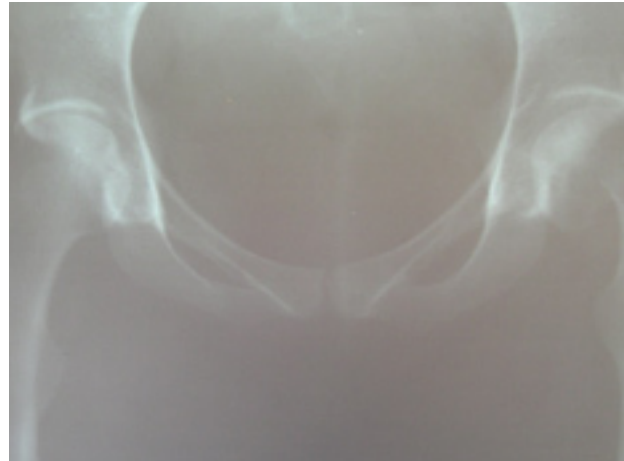
Radiograph of the hip during his last presentation was reported to be consistent with avascular necrosis of the femoral head. He improved following treatment with non-steroidal anti-inflammatory drug therapy and was discharged while ambulating on crutches for definitive care by the orthopaedic surgeons

Figure 1*Reticulo-nodular opacities on X-ray of the chest***Figure 2***Osteonecrosis head of the left femur***CASE REPORT 2**

A 30 years old HIV positive black female NW, had been on highly active anti-retroviral therapy with a regimen comprising stavudine, lamivudine and efavirenz over the last two years. Her nadir CD4+ count at time of initiation of therapy was 13cells/ml. There were no reports of her treatment follow up. She presented with acute spontaneous hip pain with severe exacerbation on movement. NW also had shortness of breath. Noted to have features of lipodystrophy, her temperature was 36.5°C, respiratory rate of 25/min and a blood pressure of 110/70mmHg. She had no calf swelling or tenderness.

Laboratory tests included normal blood counts, normal serum amylase and a raised serum lactate of 8.0 mmol/l. Radiograph documented osteopaenia with fracture of the neck of left femur. Her disease

progression was rapid and she died within 24 hours of admission.

Figure 3*Fracture neck of left femur in patient with osteopenia. Both hip joints demonstrate radiologic changes***DISCUSSION**

The association of bone disease and HIV has been increasingly observed in the era of highly active antiretroviral therapy (HAART) as patient life expectancy rises. Osteopaenia, osteoporosis, bone fractures and osteonecrosis are some of the documented bone disorders recognised as HIV complications. With the rising uptake of HAART and consequent survival benefits of treatment, an older HIV patient population may present significant rise in bone disease and necessitate strategic public health management interventions.

MRI studies have recorded osteonecrosis in 4.4% of patients, which is much higher than 0.01-0.135% prevalence seen in the general population (1, 2). This may impact on the national health budgets as it may represent a large need for surgical intervention particularly in sub-Saharan Africa where the burden of HIV disease is still quite high.

The cause of bone disease remains unclear but some of the proposed mechanisms of bone disease include; direct effects of the HIV virus and associated immunodeficiency, underlying co-infections and co-morbidity, immune activation coupled with inflammation, coagulopathies and associated vascular insufficiency and antiretroviral drug toxicities (3).

Direct effect of the HIV virus in the causation of osteopaenia and osteoporosis may be due to production of pro-inflammatory cytokines

responsible for osteoclast activation and consequent bone resorption. Low levels of bone formation marker osteocalcin, has been seen in HAART naïve advanced HIV disease, suggesting that HIV has independent effect on bone metabolism (4, 5).

Both the patients presented in the case reports had advanced HIV disease. The observed bone disease could have been attributable to direct effect of the HIV virus since the patients presented with relatively long duration of illness and opportunistic events consistent with WHO stage 3/4 disease. However a few questions need to be answered. Could the interaction of traditional risk factors of osteoporosis in this case prolonged use of corticosteroids in patient case report 1, with HIV viral infection and possible HAART related toxicities increase the risk of bone disease? Metabolic changes related to HAART have been shown to have a causal association with osteopenia and osteonecrosis (6). Could the mitochondrial toxicity of the drug regimen used in this patient or the possible consequent dyslipidemia explain the bone pathology? Is lipodystrophy predictive of higher risk of bone disease?

Patients on long periods of stavudine exposure have a significant risk of developing lipodystrophy and hyperlactataemia both being related to its high mitochondrial toxicity. Higher levels of lactate secondary to nucleoside reverse transcriptase inhibitors therapy have been found to be associated to osteopenia in HIV infected men (6). The use of HAART regimen containing stavudine, a highly mitochondrial toxic di-deoxynucleoside for a duration exceeding one year in both patients, with our second patient clearly manifesting lipodystrophy and lactic acidosis as evidence of drug toxicity may incriminate stavudine in the causation of osteopaenia and osteonecrosis.

The World Health Organization (WHO) guidelines for treatment of HIV infection in resource constrained settings 2010 and 2013 (7, 8). Have recommended the use of tenofovir based regimen replacing the thymidine analogue based as preferred first line intervention. This is because it offers lower toxicity, good therapeutic strategy in populations with high hepatitis B co-infection and better HAART sequencing options. Despite lower mitochondrial toxicity, tenofovir may be associated with greater degree of short term loss of bone density than other antiviral drugs (9). It would be important to evaluate the impact of switching from use of thymidine analogue based therapy to tenofovir on the incidence of osteopaenia and osteonecrosis as the national guidelines now recommend tenofovir as our preferred first line

agent. The needs to consider the use of abacavir or raltegravir as alternatives to tenofovir or use of these agents in treatment simplification in patients at high risk of kidney and bone disease is likely to provide significant consideration in planning of national guideline (10).

Controversy still exists on the independent role of protease inhibitors in osteopaenia, osteoporosis and osteonecrosis with some studies reporting benefit of protease inhibitor use and other indicating increasing bone loss. (11-13). Matos *et al* in their study suggests that protease inhibitors play a role in osteonecrosis through a tendency to cause hyperlipidemia (11, 12). A study by Sharma *et al* reports that bone loss among HIV-infected middle aged women was possibly mitigated by use of protease inhibitors with longer use appearing to be protective in gain in bone mineral density (13). There is great need to establish the varied role of different protease inhibitors on osteoblast activity, osteoclast differentiation and function and calcium deposition. This would help rationalise the selection of protease inhibitor particularly when considering therapy for patients with traditional risk factors of bone disease and those above the age of 50 years.

Other valuable considerations that would accelerate bone loss include nutritional deficiencies and in particular low levels of calcium and vitamin D and traditional risk factors of bone disease such as alcohol abuse, hyperlipidemias, sickle cell anaemia, coagulopathies, hyperuricemia and connective tissue disorders. Changes in vitamin D metabolism with deficit in one, 25 dihydroxycholecalciferol have been reported in HIV infected patients. Treatment of calcium or vitamin D deficiency in HIV positive patients on HAART has favorable effects on bone density (14). We need to establish the prevalence of vitamin D and calcium deficiency in treatment-naïve and HAART exposed patients in our setting to help inform and rationalise calcium and vitamin D supplementation.

Key interventions in addressing bone health in HIV infected patients will therefore involve rationalising the selection of HAART regimen, paying considerable attention to the risk and benefit use of corticosteroids in patients with opportunistic diseases, nutritional supplementation and lifestyle adjustments that address the impact of aging and immobility on bone disease.

The two patients we have presented would benefit from imaging of other joints since hip disease will present with bilateral involvement in a good

proportion of patients, knee, ankle and shoulder joint may also be affected. Multi-joint involvement is not infrequent (15). In addition to Calcium and vitamin D supplementation, some antiresorption agent such as oestrogens, calcitonin, bisphosphonates and bone formation stimulating agents such as sodium fluoride and PTH have been used in therapy of bone disease in these patients. Surgical decompression, osteotomies and arthroplasty may be vital; studies on surgical outcomes appear to indicate that total hip replacement in HIV positive patients is not worse than that of HIV negative patients (16).

REFERENCES

1. D Meyer, G Behrens, RE Schmidt, M Stroll. High prevalence of osteonecrosis of the femoral head in HIV patients receiving protease inhibitors. *AIDS*. 13, 1147-1148.
2. C. R. Mahoney, M. J. Glesby, E. F. Dicarlo., et al. Total hip arthroplasty in patients with human immunodeficiency virus infection. *Acta Orthop*. 2005; **76**: 198-203.
3. WG Powderly. Osteoporosis and bone health in HIV; *Curr HIV / AIDS Rep* 2012; **9**: 218-222.
4. J Thomas and SM Doherty. HIV infection, a risk factor of osteoporosis; *Journal of acquired immunodeficiency syndrome*. vol 33 no 3 pg 281-291 2003
5. Aukrust P, Haug CJ, Ueland T et al. Decreased bone formative and enhanced resorptive markers in human immunodeficiency virus infection: indication of normalization of bone remodeling process during highly active antiretroviral therapy. *J Clin Endocrinol. Metab*. 1999; **84**:145-150.
6. Carr, A, Miller J, Eisman JA, Cooper DA, Osteopenia in HIV infected men: association with asymptomatic lactic acidemia and lower weight pre-antiretroviral therapy. *AIDS* 2001; **15**:703-709.
7. Geneva: World health organization 2010
8. Geneva: World health organization 2013
9. Parsonage M.J, Wilkins EGL, Snowden N et al; the development of hypophosphataemic encephalopathy with myopathy in two patients with HIV infection receiving tenofovir therapy. *HIV Med* 2005; **6**: 341-346.
10. Bloch M, Tong W, Hoy J, Lee F, Richardson R, Carr A. Switch from tenofovir to raltegravir increases low bone mineral density and decrease markers of bone turnover over 48 weeks. *HIV Med*. 2014 (Epub ahead of print)
11. Matos MA, Alencar RW, Matos SS. Avascular necrosis of the femoral head in HIV- infected patient. *Braz J Infect Dis*. 2007; **11**: 31-34.
12. Brown P, Crane L, Avascular necrosis of bone in patients with human immunodeficiency virus infection, report of 6 cases and literature review. *AIDS* 2001; **32**: 1221 - 1226.
13. Sharma A, Cohen HW, Freeman R, Santoro N, Schoenbaum EE. prospective evaluation of bone mineral density among middle-aged HIV-infected and uninfected women : association between methadone use and bone loss. *Maturitas*. 2011; **70**:295-301.
14. Bech A, Van Bentum P, Telting D, Gisolf J, Richter C, De Boer H. Treatment of calcium and vitamin D deficiency in HIV-positive men on tenofovir containing antiretroviral therapy. *HIV Clin Trials*. 2012; **13**: 350-356.
15. Mehta P, Nelson M, Brand A, Bloag F; avascular necrosis in HIV : *Rheumatol int*. 2013; **33**: 235-238.
16. Tomero E, Garcia S, Larrousse M, Gallart X, Bori G, Riba J, Rios J, Gatell J, Martinez E. Total hip arthroplasty in HIV-infected patients : a retrospective controlled study. *HIV Med*. 2012; **13**: 623-629.