

East African Medical Journal Vol. 89 No. 1 January 2012

GIANT SOLITARY NEUROFIBROMA IN THE GLUTEAL AREA OF A PATIENT WITHOUT NEUROFIBROMATOSIS

A. Gyedu, Department of Surgery, School of Medical Sciences, College of Health Sciences, Kwame Nkrumah University of Science and Technology, Kumasi, Ghana; Directorate of Surgery, Komfo Anokye Teaching Hospital, Kumasi, Ghana

Request for reprints to: Dr. A. Gyedu, Department of Surgery, School of Medical Sciences, College of Health Sciences, Kwame Nkrumah University, University Post Office, Kumasi, Ghana

GIANT SOLITARY NEUROFIBROMA IN THE GLUTEAL AREA OF A PATIENT WITHOUT NEUROFIBROMATOSIS

A. GYEDU

SUMMARY

Neurofibromas are benign tumours arising from neurons and perineural cells. Although they are common in neurofibromatosis, occasionally solitary neurofibromas may occur. A rare case of solitary neurofibroma presenting as a giant gluteal mass in a male patient without a personal or family history of neurofibromatosis is presented. Pre-operative imaging gave useful information about the extent of the mass which was then totally excised with histology revealing a non-plexiform neurofibroma. Distinguishing between isolated neurofibromas and those associated with neurofibromatosis is important because the treatment and prognosis differ greatly with the former having a good prognosis after total excision.

INTRODUCTION

Neurofibromas are benign tumours arising from neurons and perineural cells. They are usually considered to be an essential characteristic of neurofibromatosis (NF), a neurocutaneous systemic disease that arises from an autosomal dominant mutation. Neurofibromatosis type 1 (NF-1) is the most common form and is characterised by a range of neurocutaneous and soft-tissue lesions. Neurofibromatosis type 2 (NF-2) is characterised by the development of bilateral acoustic neuromas (1). Although neurofibromas are common in NF, occasionally solitary neurofibromas can be found in healthy people (2). In this article, a rare case of solitary neurofibroma presenting as a giant gluteal mass in a male patient without a personal or family history of NF is presented.

CASE REPORT

A 63-year-old man was referred from another hospital after an operation to excise his right gluteal mass was aborted. The mass had gradually increased in size over the past two years making it difficult for the patient to sit. Ultrasonography had confirmed the clinical suspicion of a lipoma. During the operation, it was realised that the mass was not a lipoma as previously thought. It had also displaced the urinary bladder to the left. The operation was aborted because, the surgeon could not identify

the mass with confidence and also due to lack of progression.

On examination, the patient had a normal blood pressure, pulse and temperature. He had no symptoms of lower urinary tract obstruction. Systemic examination was normal while past clinical and family history were nil of note.

Two closed incisions (one over the gluteal mass, the other lower abdominal) were noted. There was a firm, irreducible mass in the right gluteal area which had displaced the anal orifice to the left (Fig. 1). On digital rectal examination, the mass was felt to be in continuity with an enlarged prostate gland. The overlying rectal mucosa was, however, mobile. The characteristics of the prostate was difficult to ascertain due to the effect of the mass. Pelvic ultrasonography revealed an enlarged prostate with well-defined margins while a cystogram revealed a deviated urinary bladder with normal contour and no intraluminal filling defect. A computed tomography (CT) scan with iv, oral and rectal contrast revealed the gluteal mass measuring about 12.5 × 8.5cm in close proximity to an enlarged prostate, displacing the urinary bladder superiolaterally to the left and compressing and displacing the rectum to the left (Fig. 2).

Hemogram, renal function tests, total prostate specific antigen were all normal.

The overall clinical impression was a benign tumour for which an excisional biopsy was performed through the gluteal incision. The mass, measuring 21 × 9 × 4cm, was soft to firm, light brown in colour,

well-circumscribed and appeared to arise from the subcutaneous tissue (Fig 3A). Histologically, the mass consisted of wavy spindle cells containing elongated nuclei and markedly wavy eosinophilic cytoplasm in a loose stroma (Fig 3B). The spindle cells displayed the wavy and focally whorled growth pattern of a neurofibroma. The pathological diagnosis was non-plexiform-neurofibroma. There was no evidence of malignancy noted. Post-operative course was uneventful and 20 months post-operatively, the patient is free of any symptoms and a watch-and-wait approach has been adopted with regard to his enlarged prostate since he has no symptoms of lower urinary tract obstruction.

Figure 1

Right gluteal mass displacing anal orifice to the left

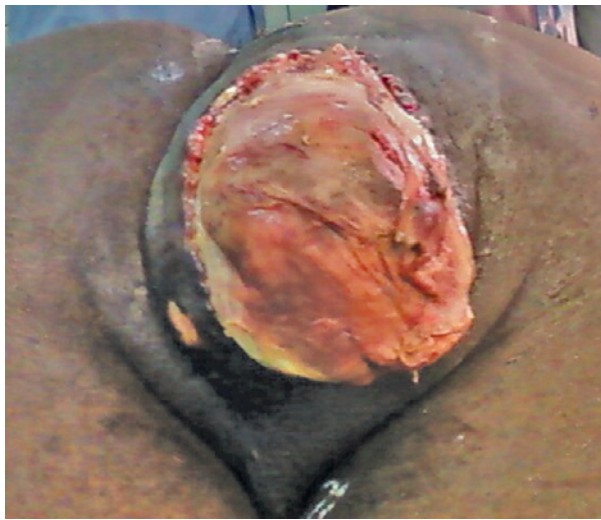

Figure 2

CT of the gluteus (A) and lower pelvis (B) showing the gluteal mass () displacing the rectum (lower arrow) and urinary bladder (upper arrow) to the left*

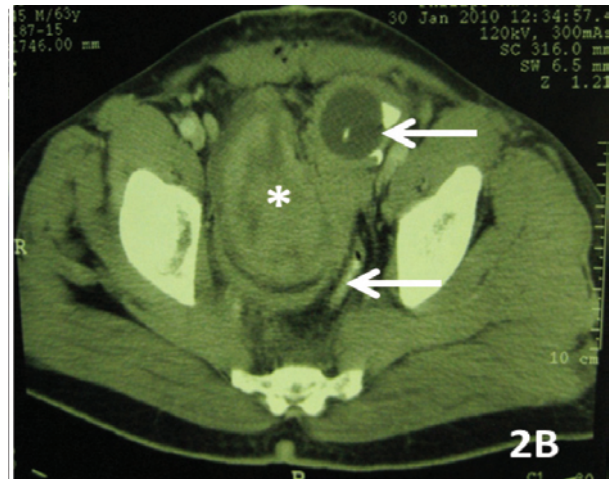
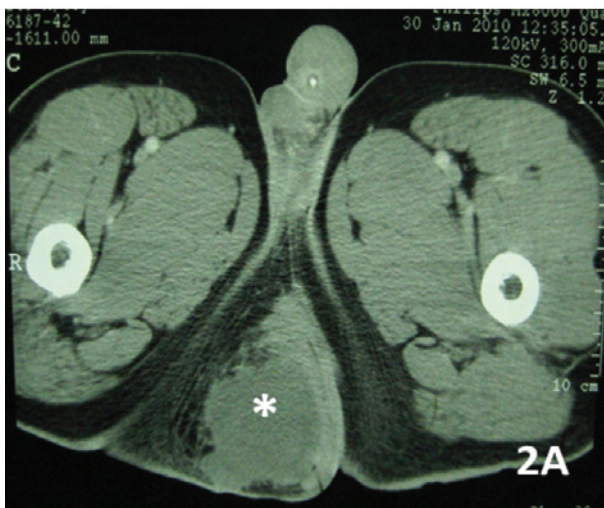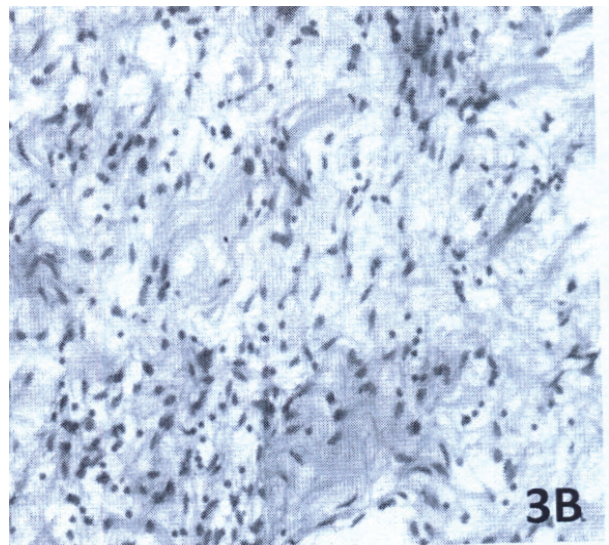
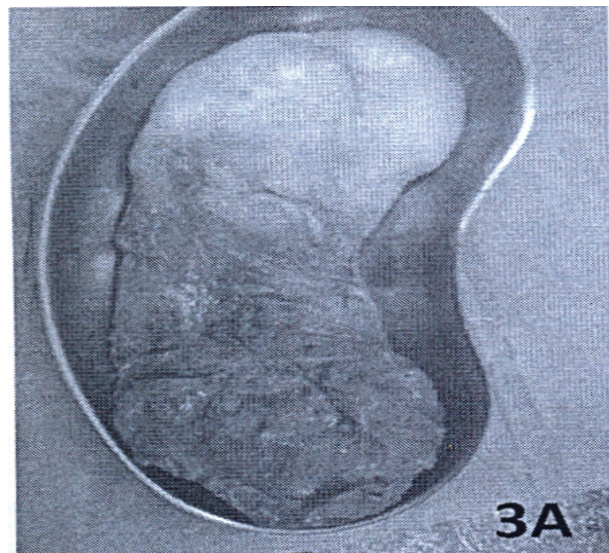


Figure 3

Gluteal mass after excision; B. H and E stain (X200): wavy spindle cells with markedly wavy eosinophilic cytoplasm in a loose stroma



DISCUSSION

Neurofibromas can be solitary or multiple and the multiple neurofibromas are usually classified as a neurofibromatosis. Although they can develop anywhere within the central or peripheral nervous system (3), to the best of my knowledge this is the first case of localisation in the gluteal area to be published in the English literature.

Solitary neurofibromas are solid, well-circumscribed, differentiated and non-encapsulated tumours that tend to grow slowly in the skin. Neurofibromas arising in other parts of the body are rare (4-6). Cutaneous tumours cause surface deformation, whereas deeper masses can cause functional compromise as a result of the compression of neighbouring organs (2).

With ultrasonography, neurofibromas appear as smooth, well-defined and lobulated masses; while on computed tomography, they have a homogeneous, smooth and round appearance and often contain multiple cystic spaces caused by myxoid degeneration. Making a definitive pre-operative diagnosis is very difficult. Histology and sometimes immunohistochemical studies are necessary for exact diagnosis. Complete surgical resection is the only treatment for these tumours. Malignant transformation is unusual (2).

The histopathological plexiform neurofibroma confirms the diagnosis of NF-1 in the patient with solitary neurofibroma even without other stigmas. In contrast, when a diagnosis of solitary neurofibroma is made via a histology of non-plexiform neurofibroma, it is necessary to rule out NF-1 (3). Distinguishing between isolated neurofibromas and those associated with NF-1 is important because the treatment and prognosis differ greatly. Furthermore, neurofibromas associated with NF-1 are more likely to recur or undergo malignant transformation (7). Our patient

did not have any other characteristic clinical feature of NF-1. In the case of solitary neurofibroma, good prognosis is usually obtained by surgical resection of the tumour (3).

In conclusion, the present case shows neurofibroma can occur in the gluteal area as an isolated benign tumour in patients with no family history or other features of NF-1. The additional information that can be provided by imaging modalities in the work-up of a gluteal mass is also highlighted.

REFERENCES

1. Tao, Q., Wang, Y., and Zheng, C. Neurofibroma in the left mandible: a case report. *Kaohsiung J. Med. Sci.* 2010; **26**: 217-221.
2. Barajas-Gamboa, J. S. and Frolez-Salamanca, A. Solitary neurofibroma in the abdominal wall of a patient without neurofibromatosis: case report. *Biomedica.* 2009; **29**: 501-505.
3. Shibano, S., Iguchi, T. and Nakatani, T. A case of scrotal neurofibroma originating from subcutaneous neural tissue. *Int. J. Urol.* 2010; **17**: 387-388.
4. Panteris, V., Vassilakaki, T., Vaitsis, N., et al. Solitary colonic neurofibroma in a patient with transient segmental colitis: case report. *World J. Gastroenterol.* 2005; **11**: 5573-5576.
5. Pearl, V., Vassilakaki, T., Vaitsis, N., et al. A case of large sporadic neurofibroma of the hand. *J. Plast Recon Aesthet Surg.* 2010 Jan 8. (Epub ahead of print).
6. Goel, D. P., Drosdowech, D. S., Turner, R. G., et al. Periarticular neurofibroma of the shoulder: a case report. *J. Bone Joint Surg Am.* 2010; **92**: 715-720.
7. Marocchio, L. S., Pereira, M. C., Soares, C. T. and Oliveira, D. T. Oral plexiform neurofibroma not associated with neurofibromatosis type I: case report. *J. Oral Sci.* 2006; **48**: 157-160.