

## Case Report

| Access this article online   |                                  |
|--|----------------------------------|
| Quick Response Code:   | Website:<br>www.annalsafrmed.org |
|  | DOI:<br>10.4103/1596-3519.126954 |
|  | PMID:<br>*****                   |

# Giant neurofibrolipoma of the tip of the tongue: Case report and review of the literature

Benjamin Fomete, Ezekiel T. Adebayo<sup>1</sup>, Charles N. Ononiwu, Kelvin O. Idehen

Maxillofacial Surgery Unit, Ahmadu Bello University Teaching Hospital, Zaria, <sup>1</sup>Army Dental Centre, Military Hospital, Ikoyi, Lagos, Nigeria

Correspondence to: Dr. Benjamin Fomete, P.O. Box 3772, Kaduna, Nigeria. E-mail: benfometey@hotmail.com

## Abstract

Neurofibrolipoma is a very rare benign oral tumor with other synonyms such as neural fibrolipoma, perineural lipoma and intraneural lipoma. A 50 years old female presented with a massive swelling of the tongue of 6 years duration. The tumor was attached to the mucosa of the tip of the tongue, disturbing mastication and speech. On excision, histopathology revealed neurofibrolipoma. This case report shows the atypical presentation of neurofibrolipoma and the challenges of its management.

**Keywords:** Giant, Neurofibrolipoma, tongue

## Résumé

Neurofibrolipoma est une tumeur bénigne très rare d'orale avec autres synonymes tels que fibrolipoma neuronal, péri-radulaire Lipome et Lipome intraneurale. Une femme de 50 ans présentée un énorme gonflement de la langue d'une durée de 6 ans. La tumeur était attachée à la muqueuse de la pointe de la langue, inquiétant de mastication et de discours. Sur l'excision, histopathologie a révélé neurofibrolipoma. Ce rapport de cas montre la présentation atypique de neurofibrolipoma et les défis de la gestion.

**Mot-clés:** Géant, Neurofibrolipoma, langue

## Introduction

Neurofibrolipoma (NFL), a rare benign tumor, was first reported in 1953.<sup>[1]</sup> Its other names include neural fibrolipoma, lipofibromatous hamartoma, perineural lipoma, intraneural lipoma, and lipomatosis of nerve. It rarely presents in oral structures with reported sites as buccal mucosa, floor of the mouth, tongue, lip, palate, and vestibule.<sup>[2]</sup> This report presents a giant NFL of the tongue in a 50-years-old Nigerian female patient, highlighting the management challenges in view of the available literature.

## Case Report

A 50-years-old Nigerian woman was seen at the oral and maxillofacial clinic for complaint of massive, initially slow but recently rapidly growing swelling on the tip of the tongue of 6 years duration. The rest of the medical history was not significant. Examination showed a soft, yellowish lesion on the tip of the tongue shown in Figure 1. The tumor was attached to the intact mucosa of the tip of the tongue. It was not tender. Closer examination showed many superficial blood vessels in the tumor. The patient could literally “spit out” and “swallow” the tumor, which stretched

the tongue to dangle outside the mouth. She also had poor oral hygiene with the mandibular anterior teeth splayed out by the pressure of the tongue. Speech was slurred, mastication was difficult, but she managed to maintain adequate nutrition. Among the differential diagnoses were granular cell tumor, neurofibroma, traumatic fibroma, and benign salivary gland tumor. Tumor excision was done via a “V”-shaped incision on the tongue substance, closure was done in layers, and the tip of the tongue was recreated as shown in Figure 2. The complete specimen was sent for histology that revealed features diagnostic for NFL shown in Figure 3. However, patient was lost to follow-up.

## Discussion

Lipomas are common tumors in the human body, but are less frequent in the oral cavity, comprising no more than 1-5% of all the neoplasms.<sup>[2,3]</sup> While 80% are ordinary lipomas, subtypes such as angiolipoma and NFL occur.<sup>[4]</sup> NFL presents as a soft, slowly growing mass of proliferating fibro-fatty tissue surrounding and infiltrating major nerves and their branches.<sup>[5]</sup> There may be a genetic predisposition, but there is no history of any hereditary disorders.<sup>[5]</sup>

Due to rarity, characteristic features to aid diagnosis of NFL of the tip of the tongue are scarce in the literature.

The differential diagnoses of the lesion in this patient were granular cell tumor, neurofibroma, traumatic fibroma, and benign salivary gland tumor. NFL should be suspected in patients presenting with non-syndromic macroglossia.

Although MRI is an important tool in diagnosis, it should be supported by a tissue biopsy.<sup>[5]</sup> MRI and ultrasonography were not carried out for this patient due to inadequate financial resources. MRI shows the lesion as low intensity linear structures interposed in between high intensity structures, which get suppressed on fat suppression sequence. They appear as “coaxial cable-like” pattern on axial images and “spaghetti string” pattern on coronal images, a pattern considered pathognomonic for the diagnosis of neurofibrolipoma by Diwakar *et al.*<sup>[1]</sup>

NFL are believed to develop by abnormal proliferation and development of fibro-adipose tissue of nerve sheath.<sup>[1]</sup>

Grossly, it presents as a soft, gray-yellow, fusiform, sausage-shaped mass that has diffusely infiltrated and replaced portions of a large nerve and its branches.<sup>[6]</sup> The present case was a well-circumscribed nodular tissue, with mature adipose and fibrous tissue infiltrating epineural and perineural compartments. Affected nerves may also show pseudo-onion bulb

and metaplastic new bone formation.<sup>[6]</sup> The present case showed sheets of spindle and oval cells with wavy to oval nuclei in a myxoid background. These were delimited by areas of fibrocollagenous tissues and inflammatory cells including mast cells. Other area showed nerve bundles and lobules of mature adipocytes.

The present case was well-encapsulated, and excision was carried out with some margin of normal tissues. Complete excision is contraindicated in some cases when it may cause severe sensory or

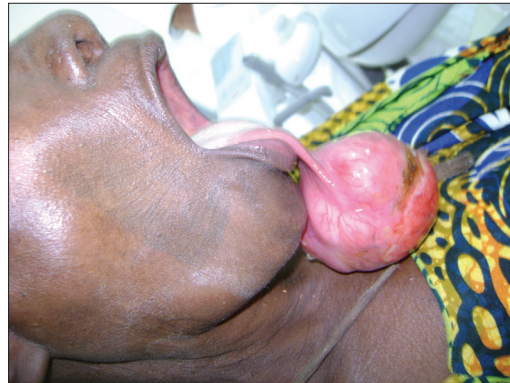

Figure 1: This is the profile view of the patient

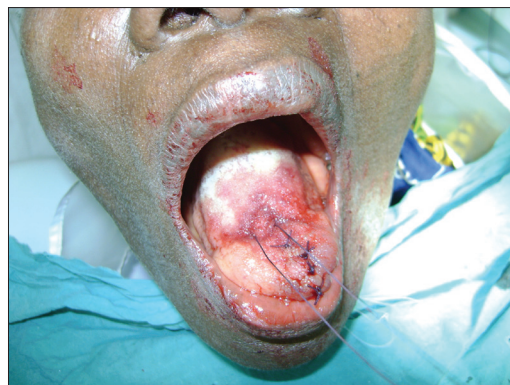

Figure 2: This is postsurgical view of tongue showing closure and new shape

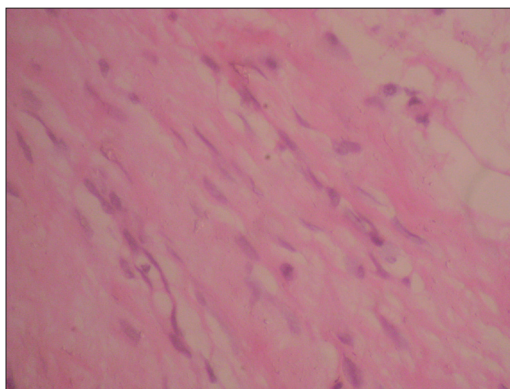


Figure 3: This is H and E stain of section of resected NFL of tongue, the neurofibroma part at x400 magnification

motor disturbances.<sup>[5]</sup> Recurrence is not expected following complete excision, but follow-up for a few years are advisable. However, the patient in this case did not present for follow-up.

## Conclusion

NFL are rare tumors, and their appearance on the tongue makes them peculiar. This case reported showed the challenges of diagnosis, especially when on the tip of the tongue.

## References

1. Diwakar N, Kamble RB, Gidaganti M. Imaging of neurofibrolipoma of median nerve. *Neurol India* 2011;59:488-9.
2. Ikram R, Rehman Al-Eid AA. Oral lipoma in elderly

saudi patient: A case report. *Int J Health Sci (Qassim)* 2012;6:97-103.

3. Chidzonga MM, Mahomva L, Marimo C. Gigantic tongue lipoma: A case report. *Med Oral Patol Oral Cir Bucal* 2006;11:E437-9.
4. Ndukwe KC, Ugboko VI, Somotun G, Adebisi KE, Fatusi OA. A Clinico pathological study of lipoma of the head and neck. *Nig J Surg Res* 2003;1-2:12-7.
5. Ardakani AS, Nematolah P, Mohammadzadeh F, Akhoondinasab MR. A case of fibrolipomatous hamartoma of nerve arising from superficial peroneal nerve. *JRMS* 2007;5:271-4.
6. Gupta A, Geetha V, Monappa V, Bhat SS. Multiple neural fibrolipomas with macrodactyly. *Indian J Dermatol* 2011;56:766-7.

**Cite this article as:** Fomete B, Adebayo ET, Ononiwu CN, Idehen KO. Giant neurofibrolipoma of the tip of the tongue: Case report and review of the literature. *Ann Afr Med* 2014;13:50-2.

**Source of Support:** Nil, **Conflict of Interest:** None declared.

## New features on the journal's website

### Optimized content for mobile and hand-held devices

HTML pages have been optimized of mobile and other hand-held devices (such as iPad, Kindle, iPod) for faster browsing speed.

Click on [**Mobile Full text**] from Table of Contents page.

This is simple HTML version for faster download on mobiles (if viewed on desktop, it will be automatically redirected to full HTML version)

### E-Pub for hand-held devices

EPUB is an open e-book standard recommended by The International Digital Publishing Forum which is designed for reflowable content i.e. the text display can be optimized for a particular display device.


Click on [**EPub**] from Table of Contents page.

There are various e-Pub readers such as for Windows: Digital Editions, OS X: Calibre/Bookworm, iPhone/iPod Touch/iPad: Stanza, and Linux: Calibre/Bookworm.

### E-Book for desktop

One can also see the entire issue as printed here in a 'flip book' version on desktops.

Links are available from Current Issue as well as Archives pages.

Click on  View as eBook