



Official journal of the Pan African Urological Surgeon's Association  
web page of the journal

[www.ees.elsevier.com/afju](http://www.ees.elsevier.com/afju)  
[www.sciencedirect.com](http://www.sciencedirect.com)



## Pediatric urology

### Original article

# Early outcome of pediatric pyeloplasty in kidneys with split renal function less than 10%: A prospective study of 25 cases

A.Y. Abdelaziz<sup>1,\*</sup>, H. Shaker<sup>2</sup>, H. Aly<sup>1</sup>, H. Aldaqados<sup>2</sup>,  
E.M. Hussein<sup>3</sup>

<sup>1</sup> Departments of Urology, Faculty of Medicine, Cairo University, Egypt

<sup>2</sup> Nuclear Medicine, Faculty of Medicine, Cairo University, Egypt

<sup>3</sup> Urology Department, Faculty of Medicine, Alfayoum University, Egypt

Received 18 May 2018; received in revised form 14 July 2018; accepted 5 August 2018; Available online 29 November 2018

## KEYWORDS

Pediatric;  
Pelvic anteroposterior  
diameter;  
Pyeloplasty;  
Split renal function

## Abstract

**Objectives:** To detect the outcome of pyeloplasty in kidneys with split renal function (SRF) less than 10% in the pediatric age group.

**Subjects and methods:** We prospectively analyzed the data from 25 cases of ureteropelvic junction obstruction (UPJO) candidate for pyeloplasty with SRF less than 10%. Abdominopelvic ultrasonography and diuretic renogram using technetium-99 m diethylenetriamine Penta acetic acid (DTPA) were done in all cases. We studied the improvement in pelvic anteroposterior diameter (APD) postoperatively. We compared pre and postoperative SRF after six months and one year.

**Results:** The median age was 24 months (3 months–11 years), male to female 2:1. The median preoperative SRF was 5% (range: 0%–10%) and the median APD of the renal pelvis was 3 cm (range: 2.2–5). There was significant improvement of median APD 0.8 cm (range: 0.5–1.9) (P value <0.05). There was a significant postoperative improvement in the median SRF (P-value <0.05) as the median SRF after 6 months and 1 year were 21% and 20%, respectively but there was no significant difference between SRF at six months and one year (P value 0.174).

**Conclusion:** Pyeloplasty provides high rates of functional success even in very poorly functioning kidneys with SRF ≤10% by DTPA renogram in pediatric age group.

© 2018 Pan African Urological Surgeons Association. Production and hosting by Elsevier B.V. This is an open access article under the CC BY-NC-ND license (<http://creativecommons.org/licenses/by-nc-nd/4.0/>).

\* Corresponding author at: Urology Department, Faculty of medicine, Cairo University, 11562, Egypt.

E-mail address: [dr\\_ahmedyehia81@yahoo.com](mailto:dr_ahmedyehia81@yahoo.com) (A.Y. Abdelaziz).

Peer review under responsibility of Pan African Urological Surgeons' Association.

<https://doi.org/10.1016/j.afju.2018.08.003>

1110-5704/© 2018 Pan African Urological Surgeons Association. Production and hosting by Elsevier B.V. This is an open access article under the CC BY-NC-ND license (<http://creativecommons.org/licenses/by-nc-nd/4.0/>).

## Introduction

Ureteropelvic junction obstruction (UPJO) is one of the most common causes of upper urinary tract obstruction in the pediatric age group. It is reported that it occurred from 1:500 to 1:1250 live births [1,2]. Despite being a congenital disease, a large number of cases present in adolescence, adulthood, or even in old age group. Surgical repair is indicated in cases with significantly impaired renal drainage or progressive deterioration of renal function. Other indications for intervention are to relieve pain or treat secondary pathologies to urinary obstruction as renal calculi or recurrent infection [3,4].

Surgical repair of UPJO in poorly functioning kidneys remains controversial. Nephrectomy is usually recommended in poorly functioning kidneys with split renal function (SRF) less than 10% [5,6]. However, recent studies indicate a significant improvement in renal function even in poorly functioning kidneys [7–10].

This study aims to detect the outcome of pyeloplasty for UPJO in the pediatric kidneys with SRF less than 10% to avoid nephrectomy in this age.

## Subjects and methods

Data of children below 12 years old presented to the outpatient clinic with ureteropelvic junction obstruction (UPJO) were prospectively collected from November 2013 to February 2016. The study included the children with unilateral UPJO and poorly functioning renal units with differential renal function less than or equal to 10% on an isotope renal scan. A written informed consent was obtained from all patients' guardians (parents). The study protocol, as well as the suggested informed consent, were approved by the Institutional Review Board (IRB) of the Urology Department before the start of enrolling participants.

Cases with bilateral UPJO, duplex systems, crossed fused kidney, anatomically abnormal kidney, previous surgery for UPJO, chronic renal failure and associated vesicoureteral reflux (VUR) were excluded from the study.

Preoperatively detailed history was taken, clinical examination and investigations in the form of urine analysis and culture, serum creatinine, abdominopelvic ultrasonography and diuretic renogram using technetium-99 m diethylenetriamine Penta acetic acid (DTPA) were done to all cases. We used ultrasonography to measure the pelvic anteroposterior diameter (APD) in all cases to standardize the comparison. Voiding cystourethrography was done to all patients but excretory urography was not routinely performed.

The parameters measured by diuretic renogram with <sup>99m</sup>Tc-DTPA included absolute glomerular filtration rate (GFR), split renal function, half-time drainage, and wash-out diuretic curve.

<sup>99m</sup>Tc-DTPA dynamic images were carried out for all patients in the present study using a dual head gamma camera equipped with all-purpose, low-energy, parallel hole collimator covering a NaI (TI) crystal of 3/8 in. thickness. We used DTPA although mercaptoacetyl-triglycine (MAG3) is more accurate as it is not available in Egypt and many other developing countries.

## Measurement of split renal function

The split renal function was measured in a composite image (1–3 min after the injection). Renal and semilunar background regions of interest (ROIs) were drawn manually around the frame of the kidney and on the lower outer renal margin, respectively.

## Outflow measurement

Outflow in response to the administered diuretic was evaluated by visual and quantitative evaluation of the study. We used the F + 0 protocol for diuresis administration and post-micturition images were taken in all patients.

The main indication for surgery is significant obstruction by abdominopelvic ultrasound, and on diuretic renogram curve,  $t_{1/2} > 20$  min with rising curve was defined as obstructed drainage or the significant drop in kidney function. If the diuretic renogram showed equivocal obstruction, patients were operated on if they were symptomatic, SRF was decreased by 5% or more, or consecutive ultrasonography revealed a decrease in cortical thickness.

None needed preoperatively urinary diversion as ureteric stent or nephrostomy. Preoperatively, relatives of all cases have consented for the possibility of later nephrectomy.

All patients underwent open Anderson-Hyens dismembered pyeloplasty through anterior retroperitoneal approach with adequate excision of the intrinsically narrow part of the ureter and small part of renal pelvis to avoid the effect of major pelvic reduction on postoperative APD. A double J (DJ) stent was placed ante-gradely in all patients during surgery. Ureteropelvic anastomosis was made in a single-layer continuous nature using either 4–0 or 5–0 Vicryl suture. The patients discharged after two days from the hospital. We evaluated postoperative results by comparing pre and postoperative anteroposterior diameter, pre and postoperative split renal function and the curve of drainage. Postoperative relief of symptoms, decrease of hydronephrosis and anteroposterior diameter and non-obstructed curve were the main indicators for success of surgery, otherwise redo is needed.

Follow up occurred at one week to assess symptoms improvement and for urine culture and serum creatinine. The stent was removed 4–6 weeks postoperatively in all cases.

Abdominopelvic ultrasound with evaluation of pelvic anteroposterior diameter was done three months postoperatively. Diuretic renogram was repeated six months and one year postoperatively. We compared the results of ultrasound and renogram pre and postoperatively and we study the operative and postoperative complications of all cases.

## Statistical analysis of data

The collected data were organized, tabulated and statistically analyzed using SPSS software statistical computer package version 18 (SPSS Inc., USA). For quantitative data, the median and interquartile range (IQR) or mean and standard deviation (SD) were calculated, when appropriate. Wilcoxon signed rank test was used to test differences in APD and renogram before and after the intervention. Qualitative data were presented as number and percentages.

H:127 cm W:30.0 kg BSA (Gehan): 1.047 msq			
RD Method: Tonnesen,Bolus Arrival Time : 21 sec			
KIDNEY	LEFT	RIGHT	TOTAL
Split Function (%):*	0	100	
(for 2:00- 3:00 mm:ss)			
T 1/2 (mm:ss):	0:40	-	
Peak Time (mm:ss):	9:22	3:08	
Dose (%):	0.00	8.24	
Depth (cm):	3.82	3.84	
Gates Split (%):	0.00	100.00	100
GFR (ml/min):	0.00	74.02	74.02
Normalized GFR :	0	122	122
(ml/min/1.73msq)			
Peak Counts (cps):	0	640	
Upslope (cpm):	0	243	
Rise Time (mm:ss):	8:44	2:14	
20/MAX (%):	-	57.03	
20/3 (%):	-	60.08	
EOS (cps):	-1	343	
TEOS (mm:ss):	13:12	19:26	
Tot. Counts (cps):	-8	56976	
Tot. Cts within range(cps):	0	3132	

Figure 1 Preoperative renogram of one of our cases.

For the interpretation of the results of significance, significance was adopted at  $P \leq 0.05$ .

## Results

The study included 25 patients with unilateral ureteropelvic junction obstruction (UPJO) and split renal function (SRF)  $\leq 10\%$  presented to the clinic from November 2013 to February 2016. Seventeen patients (68.1%) were males and 8 (32%) were females, median age was 24 months (3 months–11 years). UPJO was on the right side in eleven (44%) cases and on the left side in 14 (56%) cases. UPJO was diagnosed by antenatal ultrasound in ten cases (40%), five cases (20%) presented with abdominal swelling while ten cases (40%) presented with loin pain.

The median preoperative SRF was 5% (range: 0%–10%) and the median anteroposterior (AP) diameter of the renal pelvis was 3 cm (range: 2.2–5). There were no intraoperative complications, the mean operative time was  $86.4 \pm 18.4$  min, and there was no significant intraoperative blood loss or blood transfusion.

Nineteen cases (76%) have a smooth postoperative period with no complications, but 6 cases (24%) developed postoperative complications. Four cases (66.7%) developed postoperative fever and significant urinary tract infection with elevated leukocytes count (Clavien grade II) which treated conservatively with intravenous fluids and antibiotic. Two cases (33.3%) developed postoperative urinary leakage, one case treated conservatively with no need for intervention as leakage stopped after one week but the other case needed postoperative ureteral stent repositioning (Clavien grade 3A). In the last case, the leakage continuous for two weeks and retrograde showed the tip of DJ impeded in the suture line, it was retracted and replaced by another one in the upper calyx, the leakage stopped after two days of stent replacement.

Table 1 Preoperative vs postoperative APD and SRF.<sup>a</sup>

		P-Value
Preoperative APD	Postoperative APD	
3 (2.2–5)	0.8 (0.5–1.9)	<0.0001
Preoperative SRF	6 months postoperative SRF	
5 (2.5–8.5)	21 (14.5–27.5)	<0.0001
Preoperative SRF	One year postoperative SRF	
5 (2.5–8.5)	20 (15–28.5)	<0.0001
6 months postoperative SRF	One year postoperative SRF	
21 (14.5–27.5)	20 (15–28.5)	0.174

APD: renal pelvic antero-posterior diameter.

SRF: split renal function.

IQR: interquartile range.

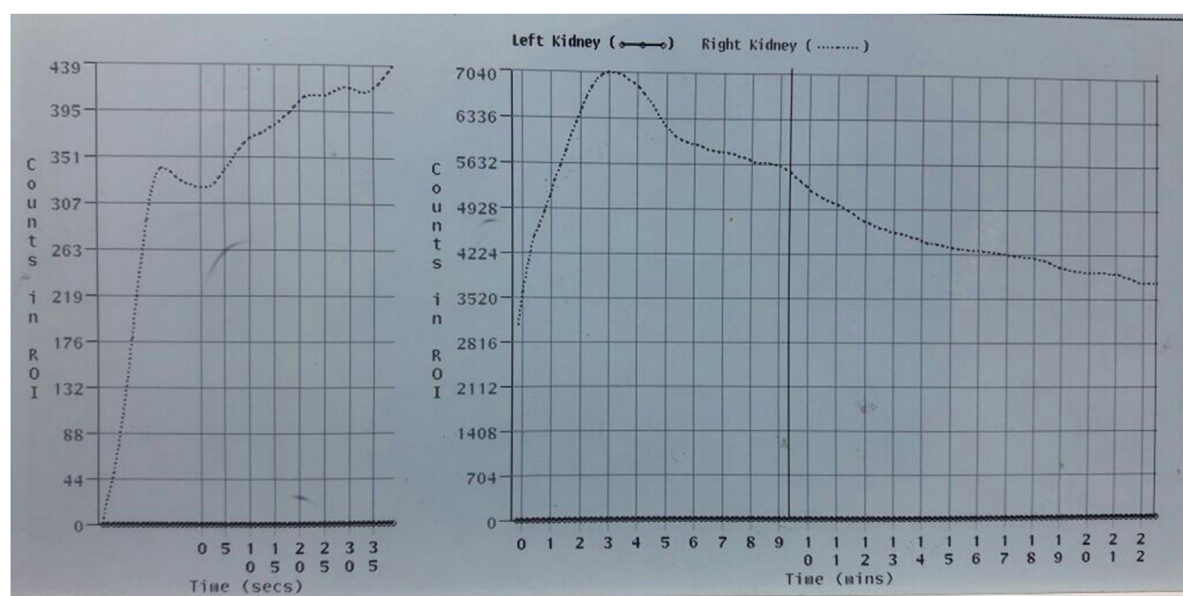
P Value less than 0.05 is significant.

<sup>a</sup> All values are expressed as median (IQR).

All non-complicated cases were discharged from the hospital after two days but the cases complicated with fever were discharged after the infection cleared with the median hospital stay five days. The first case of urinary leakage was discharged after one week while the other case stayed in the hospital for seventeen days.

All cases clinically improved postoperatively, preoperative symptoms improved and their postoperative renogram showed the non-obstructive curve.

Table 1 shows the difference between preoperative and postoperative APD and SRF. The median postoperative pelvic anteroposterior diameter was 0.8 cm (range: 0.5–1.9) with significant improvement ( $P$ -value <0.05). Postoperative renogram studies showed improvement of split renal function in all cases except two patients whose split renal function didn't improve. In these two cases, their preoperative SRF was 10% and 8% with the obstructed curve, post-



**Figure 2** Preoperative renogram of one of our cases.

H:110 cm W:20.0 kg BSA (Gehan): 0.800 msq RD Method: Tonnesen,Bolus Arrival Time : 5 sec			
KIDNEY	LEFT	RIGHT	TOTAL
Split Function (%): (for 2:00- 3:00 mm:ss)	15	85	
T 1/2 (mm:ss):	-	-	
Peak Time (mm:ss):	20:55	8:35	
Dose (%):	1.30	7.54	
Depth (cm):	3.10	3.12	
Gates Split (%):	14.68	85.32	100
GFR (ml/min):	11.76	68.11	79.87
Normalized GFR (ml/min/1.73msq):	25	147	173

**Figure 3** Postoperative renogram of one of our cases.

operatively their renogram studies were not obstructed but still have the same SRF. Their APD preoperatively were 2.5 and 3.5 cm and improved to 1.2 and 2 cm postoperatively with nearly the same parenchymal thickness. These two patients did not need nephrectomy as their follow up renogram studies showed no deterioration of the renal function and they did not develop any symptoms or urinary tract infection.

Other than these two patients there was a highly significant improvement in SRF in postoperative renogram after six months and one year. The median SRF after six months and one year were 21% and 20%, respectively with significant postoperative improvement (P-value <0.05) but there was no significant difference between renogram studies at six months and one year (P value 0.174). Figs. 1 and 2 show preoperative renogram of one of our cases, Figs. 3 and 4 show postoperative renogram after 6 months.

We studied the effect of preoperative presentation on postoperative SRF improvement, and we found that there was no significant effect of preoperative presentation on postoperative outcome. There was significantly different (P value=0.016) between SRF at 6 months and one year only in cases prenatally diagnosed. (Table 2).

**Table 2** Improvement of SRF<sup>a</sup> in different presentations.

Time	Prenatal	Abdominal swelling	Loin pain
	Median (IQR) <sup>b</sup>		
At baseline	7 (4.5–8.8)	2 (1.0–5.5)	5 (4.3–9.0)
After 6 months	16.5 (11.0–25.5)	21 (15.5–32.5)	16.5 (8.3–23.3)
After 1 year	22.5 (16.3–29.3)	20 (15–30.0)	15.5 (11–24.5)
P-Value <sub>baseline/6 m</sub>	0.027	0.008	0.012
P-Value <sub>baseline/1 year</sub>	0.012	0.008	0.012
P-Value <sub>6 m/1 year</sub>	0.016	0.776	0.477

The P-value less than 0.05 is significant.

<sup>a</sup> SRF: split renal function.

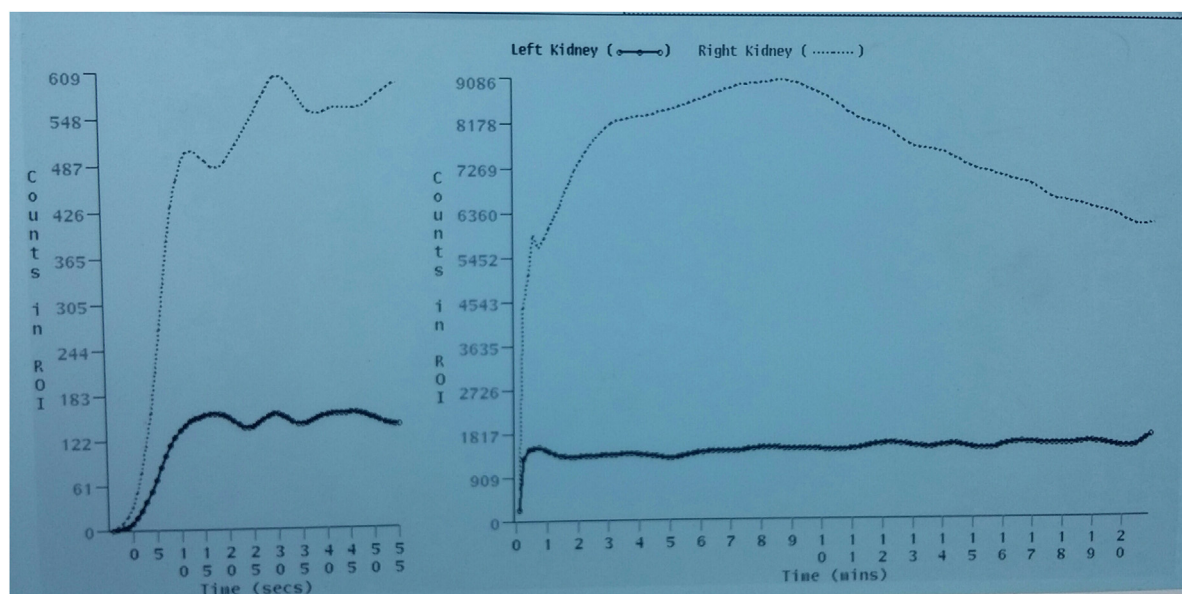
<sup>b</sup> IQR: interquartile range.

## Discussion

Ureteropelvic junction obstruction (UPJO) is an obstruction of the urine flow from the pelvis to the proximal ureter. There are many theories explaining the cause of this obstruction but usually, there is an abnormal segment of the proximal ureter should be excised during surgical repair. As a result of this obstruction, back pressure within the renal pelvis causes progressive renal damage and deterioration of its function. This condition may appear in adult or pediatric age group, but widespread use of prenatal ultrasonography and the advent of modern imaging techniques resulting in the early diagnosis of UPJO. It is more common in males and on the left side as noted in this study [11,12].

The natural history of UPJO is variable, while some cases undergo severe and irreversible renal damage, others remain stable for long periods or even improve with time. There is an increase in the single nephron filtration rate when the number of functioning nephrons decreases [13]. Jindal et al. studied the renal functional reserve in cases with UPJO by measurement of baseline GFR and stimulated GFR after protein load. They measured the renal function reserve as the difference between the two GFR measurements. They found that this reserve is preserved in children with hydronephrosis, which





**Figure 4** Postoperative renogram of one of our cases.

ultimately contributes to the improvement in renal function after surgical repair [14].

We studied the improvement of renal function after pyeloplasty in 25 patients with preoperative split renal function  $\leq 10\%$  in the renal scan. We diagnosed the cases using abdominopelvic ultrasound and diuretic renogram using DTPA. Intravenous pyelography (IVP) was not done routinely as in a poorly functioning kidney with SRF  $<10\%$ , contrast uptake is poor.

#### *The effect of preoperative presentation*

Ten cases of our patients (40%) were diagnosed by antenatal ultrasonography while 15 cases (60%) presented with abdominal swelling or loin pain. No cases presented with pyonephrosis or needed urgent drainage by nephrostomy or ureteric stents. There was no significant effect of preoperative presentation on postoperative outcome. Capolicchio et al. also found higher preoperative split renal function in patients diagnosed antenatally in his group of patients with SRF  $<40\%$  [15]. Salem et al. showed the same finding in all his cohort of patients [16].

We observed that the mean improvement in SRF was high in cases presented with a palpable mass. Although a palpable mass was associated with preoperative poor split function and grossly thin parenchyma by ultrasonography yet hydronephrosis affecting these kidneys reflect their capability to produce urine and that their glomerular function may be temporarily affected by the pressure of the urine in the obstructed system. This observation is similar to the results of Salem et al. [16] and Menon et al. [17].

#### *Outcome in poorly functioning kidneys*

The outcome of pyeloplasty in a unilateral poorly functioning kidney is debatable. In poorly functioning renal units (split function  $<10\%$ ), the decision traditionally was in favor of nephrectomy, but there are many studies that support pyeloplasty, as there is an improvement in the drainage as well as renal function. The poorly functioning

renal unit with UPJO behaves differently from the one with VUR as scar formation is rare. Our study showed postoperative significant improvement in pelvic anteroposterior diameter and split renal function after 6 months and one year. The minor pelvic reduction was done in all cases to exclude the effect of major reduction on postoperative APD. There was no significant difference between postoperative SRF after 6 months and one year.

Many studies showed improvement in split function in poorly functioning kidneys (SRF  $<10\%$ ) after fixation of nephrostomy. [7,8,17]. Menon et al. found a highly significant improvement in SRF in forty cases with preoperative SRF less than 20%. They diagnosed UPO based on ultrasound and obstructed drainage on a standardized ethylene dicysteine scan with dynamic and static images taken at regular intervals after injection of the radionuclide along with lasix (1.0 mg/kg dose). Follow-up ranged from 1 to 8 years (4.6 – 1.34 years). The first postoperative scan was done at 9 months and 2 years and this SRF was considered for comparison with preoperative scans. The mean increase in SRF was seen from  $3.16 \pm 2.87$  to  $18.46 \pm 14.17\%$  and ten cases needed nephrectomy. They fixed nephrostomy in twenty cases with the significant mean increase in SRF from  $2.96 \pm 2.8$  to  $13.8 \pm 3.89$  and improved to  $16.2 \pm 6.57$  after pyeloplasty. [17]

Gupta et al. fixed nephrostomy in 17 patients with the split renal function of less than 10%. Twelve of them improved after nephrostomy drainage and split function increased to 29.2% and after pyeloplasty to 31.4% thus emphasizing that all these kidneys should not be removed without a trial of nephrostomy [7]. Aziz et al. also placed a nephrostomy in kidneys with  $<10\%$  split renal function. The renal split function improved significantly after nephrostomy fixation and SRF increased to 20%, thus avoiding the need for nephrectomy in children [8].

Other studies showed the same our results and favor pyeloplasty in poorly function kidneys. Wagner et al. studied the results of pyeloplasty in thirty-two patients and divided them into three groups (I  $>40\%$ , II  $10-40\%$ , III  $<10\%$ ). They noted significant improve-

ment of SRF 12 months after pyeloplasty in patients with <10% split function [9]. Vihma et al. also studied the effect of pyeloplasty in 23 children and observed that hydronephrotic kidneys that had reduced glomerular function preoperatively improved after pyeloplasty and this improvement were more pronounced in the kidneys with severely reduced preoperative glomerular function [10]. Bansal et al. retrospectively studied the post pyeloplasty improvement of renal function in 39 cases. They divided them into two groups: group 1 with split renal function (10%–30%) and group 2 with split renal function less than 10%. They used routinely F '0' diuretic renogram and  $t_{1/2} > 20$  min with continuously rising curve was defined as obstructed drainage. Postoperatively, the mean postoperative function increased to 38.9% in group I (mean increase 14.2%) and 19% in group II (mean increase 13.9%). They follow up the patients at a mean 41.6 months (8–75), the overall success rate was 90% [18].

Lone et al. studied 24 patients with SRF  $\leq 15\%$  undergoing pyeloplasty. The improvement in the postoperative period to a mean of  $18.08 \pm 7.3\%$ ,  $18.17 \pm 8.63\%$  and  $18.42 \pm 8.42\%$  at 3 months, 9 months and 18 months follow up, respectively, indicating that the maximum improvement occurs early the operation [19].

On the other hand, Rishi et al. studied 32 cases with split renal function  $\leq 20\%$ . All patients were followed for a mean period of 26.8 months. UPJO was diagnosed on F "0" diuretic L-ethyl cysteine renogram with an obstructed pattern defined as  $T_{1/2} > 20$  min. Thirteen patients (40.6%) showed significant improvement in renal function ( $>5\%$  over preoperative), and in all, except 1 (3.1%) case there was no further deterioration of function [20].

In the present study, renal units with  $\leq 10\%$  split function were directly taken up for pyeloplasty without prior placement of a nephrostomy. If a nephrectomy is required it can be done at a later date. But this has to be with the full knowledge and consent of parents.

There are some limitations in our study such as the small number of cases involved in the study and the short duration of follow up. It is early to say that all cases of UPJO with markedly reduced renal function are for pyeloplasty and not for the nephrectomy as it needs more studies on a larger number of cases and with longer follow up to ensure that they will not cause any complications or need nephrectomy later on. Another limitation is the use of DTPA in renogram as mercaptoacetyl triglycine (MAG3) is better regarding extraction efficiency especially in children, however, unfortunately, it is not available in our institution and actually all over Egypt.

## Conclusion

Pyeloplasty should be considered even in very poorly functioning kidneys with SRF  $\leq 10\%$  by DTPA renogram in the pediatric age group with the significant postoperative improvement of split renal function in short-term follow up for one year.

## Conflict of interests

All included authors declare absence of any financial or personal relationships with other people or organizations that could inappropriately influence and bias the work.

## Ethical committee approval

Ethical committee approval of Urology department, Faculty of Medicine, Cairo University.

## Authors' contributions

Elshaymaa Mohamed Hussein: Design of the study and final approval of the version.

Hossam Shaker: Acquisition of data, and article revision.

Hussein Aldaqados: Analysis of data, and article revision.

Ahmed Yehia Abdelaziz: Interpretation of data and drafting the article and article submission.

Hussein Aly Hussein: Article revision.

## Consent from the patient

A written informed consent was taken from all participants.

## Source of funding

No fund.

## References

- [1] Arger PH, Coleman BG, Mintz MC, Snyder HP, Camardese T, Arenson RL, et al. Routine fetal genitourinary tract screening. *Radiology* 1985;156:485–9.
- [2] Grignon A, Filiatrault D, Homsy Y, Robitaille P, Filion R, Boutin H, et al. Ureteropelvic junction stenosis: antenatal ultrasonographic diagnosis, postnatal investigation, and follow-up. *Radiology* 1986;160:649–51.
- [3] Joyner BD, Mitchell ME. Ureteropelvic junction obstruction. In: Grosfeld JL, O'Neill JA, Coran AG, Fonkalsrud EW, editors. *Pediatric surgery*. 6th ed. Mosby; 2006. p. 1723–40.
- [4] Mouriquand P. Congenital anomalies of the pyeloureteral junction. In: Grosfeld JL, Fonkalsrud EW, Coran AG, editors. *Pediatric surgery*. 5th ed. Mosby Year Book; 1996. p. 1591–604.
- [5] Thorup J, Jokela R, Cortes D, Nielsen OH. The results of 15 years of consistent strategy in treating antenatally suspected pelviureteric junction obstruction. *BJU Int* 2003;91:850–2.
- [6] Dhillion HK. Prenatally diagnosed hydronephrosis: the Great Ormond Street experience. *Br J Urol* 1998;81:39–44.
- [7] Gupta DK, Chandrasekharam VVSS, Srinivas M, Bajpai M. Percutaneous nephrostomy in children with ureteropelvic junction obstruction and poor renal function. *Urology* 2001;57:547–50.
- [8] Aziz MA, Hossain AZ, Banu T, Karim MS, Islam N, Sultana H, et al. In hydronephrosis less than 10% kidney function is not an indication for nephrectomy in children. *Eur J Pediatr Surg* 2002;12:304–7.
- [9] Wagner M, Mayr J, Häcker FM. Improvement of renal split function in hydronephrosis with less than 10% function. *Eur J Pediatr Surg* 2008;18:156–9.
- [10] Vihma Y, Korppi-Tommola T, Parkkulainen KV. Pelviureteric obstruction in children: the effect of pyeloplasty on 99mTc-DTPA uptake and washout. *Z Kinderchir* 1984;39:358–63.
- [11] Lebowitz RL, Griscom NT. Neonatal hydronephrosis: 146 cases. *Radiol Clin North Am* 1977;15:49.
- [12] Haq A, Khan I. Tubeless and stentless pyeloplasty. *J Pak Med Assoc* 2003;17:124–7.

- [13] Pascual L, Oliva J, Vega PJ, Principal I, Valles P. Renal histology in ureteropelvic junction obstruction: are histological changes consequence of hyperPltration. *J Urol* 1998;160:976–9.
- [14] Jindal B, Bal CS, Bhatnagar V. The role of renal function reserve estimation in children with hydronephrosis. *J Indian Assoc Paediatr Surg* 2007;12:196–201.
- [15] Capolicchio G, Leonard MP, Wong C, Jednak R, Brzezinski A, Pippi Salle JL. Prenatal diagnosis of hydronephrosis: impact on renal function and its recovery after pyeloplasty. *J Urol* 1999;162:1029–32.
- [16] Salem YH, Majd M, Rushton HG, Belman AB. Outcome analysis of pediatric pyeloplasty as a function of patient age, presentation and differential renal function. *J Urol* 1995;154:1889–93.
- [17] Menon P, Rao KL, Bhattacharya A3, Mittal BR. Outcome analysis of pediatric pyeloplasty in units with less than 20% differential renal function. *J Pediatr Urol* 2016;12(June (3)), 171.e1–7.
- [18] Bansal R, Ansari MS, Srivastava A, Kapoor R. Long-term results of pyeloplasty in poorly functioning kidneys in the pediatric age group. *J Pediatr Urol* 2012;8:25–8.
- [19] Lone YA, Samujh R, Bhattacharya A, Kanojia RP. Outcome of poorly functioning kidneys secondary to PUJO preserved by pyeloplasty. *J Pediatr Surg* 2017;52(4):578–81, <http://dx.doi.org/10.1016/j.jpedsurg.2016.11.039>. Epub ahead of print 2016 Nov 26.
- [20] Nayyar R, Yadav S, Singh P, et al. Outcomes of pyeloplasty in very poorly functioning kidneys: examining the myths. *Urology* 2016;92:132–5, <http://dx.doi.org/10.1016/j.urology.2016.02.045>. Epub ahead of print 2016 Mar 9.