



## African Journal of Urology

Official journal of the Pan African Urological Surgeons' Association  
web page of the journal

[www.ees.elsevier.com/afju](http://www.ees.elsevier.com/afju)  
[www.sciencedirect.com](http://www.sciencedirect.com)



**Uro-oncology**  
*Original article*

# Pattern and clinical management of penile cancer in Rwanda

**E. Ngendahayo<sup>a</sup>, M. Nzayirambaho<sup>b,\*</sup>, A. Bonane<sup>c</sup>, G.A. Gasana<sup>d</sup>,  
R. Ssebuufu<sup>e</sup>, F. Umurangwa<sup>a</sup>, E. Muhawenimana<sup>f</sup>,  
A. Nyirimodoka<sup>f</sup>, I. Nzeyimana<sup>f</sup>, B. Rugwizangoga<sup>g</sup>, T.Z. Muvunyi<sup>h</sup>,  
E. Musoni<sup>g</sup>, S. Bwogi<sup>i</sup>, T. Hategekimana<sup>j</sup>, R. Kalengayi<sup>a</sup>,  
E. Rwamasirabo<sup>a</sup>**

<sup>a</sup> King Faisal Hospital, Department of Surgery, Urology Unit, King Faisal Hospital, P.O. Box 2534, Kigali, Rwanda

<sup>b</sup> University of Rwanda, College of Medicine and Health Sciences, School of Public Health, P.O. Box 5229, Kigali, Rwanda

<sup>c</sup> University Teaching Hospital of Kigali, Department of Surgery, Urology Unit, University of Rwanda, College of Medicine and Health Sciences, School of Medicine and Pharmacy, P.O. Box. 655, Kigali, Rwanda

<sup>d</sup> Rwanda Military Hospital, Department of Surgery, Urology Unit, P.O. Box 3377, Kigali, Rwanda

<sup>e</sup> University Teaching Hospital of Butare, Department of Surgery, University of Rwanda, College of Medicine and Health Sciences, School of Medicine and Pharmacy, Butare, Rwanda

<sup>f</sup> University of Rwanda College of Medicine and Health Sciences, School of Medicine and Pharmacy, Rwanda

<sup>g</sup> University Teaching Hospital of Kigali, Pathology Unit, University of Rwanda, College of Medicine and Health Sciences, School of Medicine and Pharmacy, P.O. Box. 655, Kigali, Rwanda

<sup>h</sup> Rwanda Military Hospital, Pathology Unit, P.O. Box. 3377, Kigali, Rwanda

<sup>i</sup> University Teaching Hospital of Butare, Pathology Unit, Butare, Rwanda

<sup>j</sup> University Teaching Hospital of Kigali, Department of Surgery, Urology Unit, P.O. Box. 655 Kigali, Rwanda

Received 25 June 2017; received in revised form 4 June 2018; accepted 3 July 2018; Available online 17 October 2018

### KEYWORDS

Penile cancer;  
Penectomy;  
Inguinal lymph node  
dissection;  
Pelvic lymphadenectomy;  
Rwanda

### Abstract

*Introduction:* Penile cancer is rare in developed countries but has a high prevalence in some developing countries. Surgery includes inguinal lymphadenectomy, which remains the mainstay treatment of the disease.

*Objective:* This study reports on the epidemiological profile of penile cancer and clinical management options in Rwanda.

\* Corresponding author.

E-mail address: [mnzayira@nursph.org](mailto:mnzayira@nursph.org) (M. Nzayirambaho).

Peer review under responsibility of Pan African Urological Surgeons' Association.

<https://doi.org/10.1016/j.afju.2018.07.001>

1110-5704/© 2018 Pan African Urological Surgeons Association. Production and hosting by Elsevier B.V. This is an open access article under the CC BY-NC-ND license (<http://creativecommons.org/licenses/by-nc-nd/4.0/>).

*Patients and methods:* From January 2015 to June 2016, a multicenter cross-sectional, prospective cohort study was conducted involving all male patients presenting with penile cancer after two national radio campaigns and a Ministry of Health instruction to all district hospitals. All patients with positive biopsy were included. Surgical treatment aligned with published guidelines. Clinical characteristics, surgery, pathology, and early follow-up data were collected.

*Results:* Over 18 consecutive months, 30 male patients were enrolled. The mean age was 60 years [range 33–83]. All patients were uncircumcised before symptom onset; 50% had phimosis and 20% were HIV-positive. The estimated prevalence of penile cancer in Rwanda was 0.37 per 100,000 men. At presentation, 96.7% of patients had a T2-4 disease and 43.3% were with clinically non-palpable inguinal lymph nodes (cNO). After penectomy, bilateral inguinal lymphadenectomy was performed in 10 (33.3%) patients (modified and radical in 16 and 4 limbs, respectively). Complications included surgical site infection (10%), lymphocele (10%), urethral meatus stenosis (6.7%), skin necrosis (3.3%) and two (6.7%) patients with metastatic disease died in hospital.

*Conclusion:* Penile cancer is a rare but significant disease in Rwanda. Patients present with advanced disease. After treatment of the primary tumor, modified inguinal lymphadenectomy appears to be a safe method of cure and staging for patients with clinically impalpable inguinal lymph nodes. Our early results provide a compelling insight into this rare but serious disease.

© 2018 Pan African Urological Surgeons Association. Production and hosting by Elsevier B.V. This is an open access article under the CC BY-NC-ND license (<http://creativecommons.org/licenses/by-nc-nd/4.0/>).

## Introduction

Cancer of the penis has a marked variation in geographic distribution. In developed countries, the overall incidence of penile cancer is less than 1 in 100,000 males [1], while it is more prevalent in some parts of South America, South East Asia and Africa [2]. Variation has also been observed in terms of disease stage at presentation. Whereas most patients present with early stage disease in developed countries [3], a delayed consultation may lead to auto-amputation of the penis (penectomy) with severe consequences in some developing countries throughout the world [4–7]. Important risk factors include phimosis, chronic penile inflammation, psoralene and UVA phototherapy, smoking, human papillomavirus (HPV) infection, and poor penile hygiene [8–12]. The most commonly affected age group for penile cancer is between 50 and 70 years [13,14]. Surgery remains the mainstay treatment of penile cancer [15]. Inguinal lymphadenectomy has both curative [16] and prognostic [17] value, hence it is the major component of overall treatment since systemic treatment is not particularly effective [18], while additional adjuvant radiotherapy has no added value [19]. The lack of cancer registries and epidemiological surveillance programs in most developing countries (including Rwanda) makes it difficult to estimate the prevalence and incidence of penile cancer in those parts of the world. This study was conducted to estimate the prevalence of penile cancer in Rwanda and to ascertain the disease pattern and clinical management.

## Patients and methods

### *Study design and settings*

A multicenter, prospective male cohort study involving patients presenting with penile cancer was conducted in Rwanda from January 2015 to June 2016. The study was conducted in four main referral University Teaching Hospitals. These were the University Teaching

Hospital of Butare (CHUB) in the South, the University Teaching Hospital of Kigali (CHUK), Rwanda Military Hospital (RMH), and King Faisal Hospital (KFH) in Kigali City, the national capital. Only the three hospitals in Kigali have both urological and pathological services, hence surgical treatment of patients was only performed in these particular locations.

### *Preliminary campaigns*

Shortly before and after the beginning of the study, two national radio-campaigns were conducted. During a 30-min radio interactive program on Radio Rwanda (a national radio channel followed by the great majority of the Rwandan population), symptoms and signs of penile cancer were explained to the population. The dates and venue for screening of this disease were communicated. The same information was also broadcasted on National Television. Patients with suspicious penile lesions were requested to present to the nearest district hospitals for a transfer to referral hospitals for diagnosis and treatment. Announcements were also repeatedly released during the most popular programs on Radio Rwanda, explaining dates and venue of screening campaigns. In addition, the Ministry of Health released an announcement to directors of district hospitals requesting them to facilitate transfer of such patients. The screening campaigns were carried out in February and March 2015, respectively at CHUK in Kigali City and at CHUB in the Southern Province. Patients had no financial barrier since most of them were insured under a national mutual insurance scheme that allows transfer to higher levels.

### *Study population*

The study involved all male patients that presented over a period of 18 months, from January 2015 to June 2016 at any of the study hospitals, during screening campaigns or for regular consultation. Patients with clinically apparent penile cancer or with premalignant penile lesions were included in the study after obtaining their written

informed consent. Data was captured using a pre-designed questionnaire that included demographics, risk factors for penile cancer, clinical presentation, stage of the disease and both perioperative, and early follow-up data. A negative biopsy was the only exclusion criterion. Patients with histopathologically-confirmed penile cancer were then offered surgical treatment in accordance with the Tumor-Node-Metastasis (TNM) stage as per previously defined guidelines.

#### *Clinical management guidelines*

The research team developed guidelines for the management of penile cancer in Rwanda, inspired by the European Association of Urology guidelines (EAU, 2014) on the management of penile cancer, while also taking into account the available local resources.

#### *The primary tumor*

All tumors less than T2 had to be treated with a wide excision, while T2 tumors were treated with glansectomy or partial penectomy, and T3 lesions were treated with partial or total penectomy using a perineal urethrostomy. Partial penectomy had to respect a safe margin of 10 mm from the lesions. Patients with T4 tumors were only considered for palliative surgery in instances where they were not able to pay for neoadjuvant chemotherapy themselves since mutual health insurance did not cover chemotherapy for penile cancer.

#### *Inguinal and pelvic lymph nodes*

Having no facilities for dynamic sentinel node biopsy at the aforementioned locations in Rwanda, modified inguinal lymph node dissection (ILND) was our means for cure and staging. Patients with clinically non-palpable inguinal lymph nodes (cN0) had to undergo modified ILND. As frozen biopsy was not available in the course of the study, immediate extension of a modified ILND to a radical ILND or pelvic lymphadenectomy was not part of our guidelines. Treatments had to be delayed until histological examination of excised lymph nodes. In cases with palpable inguinal lymph nodes, a fine needle aspiration (FNA) for cytology was simultaneously performed with an abdomino-pelvic CT scan and a chest radiograph to rule out any inguinal, pelvic lymph nodes, or lung metastases. Radical ILND had to be performed when a positive FNA cytology was confirmed on palpable inguinal lymph nodes. In cases where significant pelvic lymph nodes were identified by CT scan, a concomitant ipsilateral pelvic lymphadenectomy was performed, or as a deferred procedure where 2 or more histologically invaded inguinal lymph nodes were noted. During radical ILND, a sartorius muscle flap had to be transposed on to the inguinal ligament to cover the exposed femoral vessels, followed by a fascia lata rotation flap in instances where a significant gap was induced by groin skin excision.

#### *Statistical analysis*

Statistical analysis was performed using EpiInfo 3.3.2 (CDC, Atlanta, GA, USA). The median ranges were calculated for continuous variables, whereas proportions and frequency tables were used to summarize categorical variables. The hospital-based prevalence of penile cancer was calculated by using a denominator of 100,000 for the number of cases per year in a population of 11,274,221, with men representing 48% of this total [20].

## **Results**

### *Socio-demographic profile*

During the study period, 35 male patients presented with penile lesions that were either clinically malignant or premalignant. Eleven of them were recruited during screening campaigns and 24 during consultations throughout the study period. After penile lesion biopsy, 30 patients with histopathology-confirmed penile malignancy were enrolled in the study and all of them were born in Rwanda. The 5 benign lesions were identified as being lichen sclerosis in four patients and a fibro-epithelial polyp in the fifth patient. The hospital based prevalence was 0.37 per 100,000 males. The age at diagnosis ranged from 33 to 83 years with a median age of 60 years. The commonest age group was those aged 50–70 years, which represented 66.6% of patients. Patients came from all over the country. Twenty-five patients (83.3%) had received only primary education or none at all. Twenty-six (86.7%) of the patients were traditional farmers with no formal employment or income-generating business. However, all patients had at least the community-based health insurance allowing them treatment at the research hospitals through the national referral system.

### *Risk factors*

None of our patients were circumcised prior to symptom onset. Through questioning of patient history, half of the cases were identified as having phimosis since this was not possible to visually observe in patients with large lesions. Twenty-four patients (80%) including those with phimosis had either had sporadic or no sub-preputial hygiene in their life by the time they had the disease. Seventeen (56.7%) cases had experienced tobacco smoking to some extent for more than 5 years but this was difficult to quantify. Lichen sclerosis was identified in four (13.3%) patients with penile cancer. HPV infection was not investigated due to financial limitations.

### *Clinical and pathological profile*

In this study, twelve (40%) patients presented within one year of symptoms and 26.7% had evidence of disease for more than 5 years. HIV infection was the most prevalent co-morbidity in 20% of patients. The first symptom experienced was a subpreputial burning, swelling, or discharge in 63.3% of patients, followed by a visible penile ulceration in 26.7% patients and a urethral meatus growth in the remaining 10% of patients. The most frequent initial site of the lesion was the glans of the penis (46.7%). Almost all patients (96.7%) presented with a T2-4 disease stage. The grade of the disease was identified as being G1 in 43.3%, G2 in 50%, and G3 in 6.7% of patients. Squamous cell carcinoma was the cancer subtype observed in all patients. Inguinal lymph nodes were impalpable in 13 (43.3%) cases and fixed in 4 (13.3%) cases. Of the 17 (56.7%) patients with palpable inguinal lymph nodes, 2 died shortly after penile biopsy, with no CT scan performed. In total, lung metastases were observed on chest X-ray in four (13.3%) patients. Four (13.3%) patients with 2–4 cm unilateral palpable inguinal lymphadenopathies had a FNA for cytology, which concluded in node involvement. More detailed data are provided in [Table 1](#).

### *Clinical management*

Most surgical operations were performed in camps at one of the research hospitals, CHUK, during the weekend. This was especially

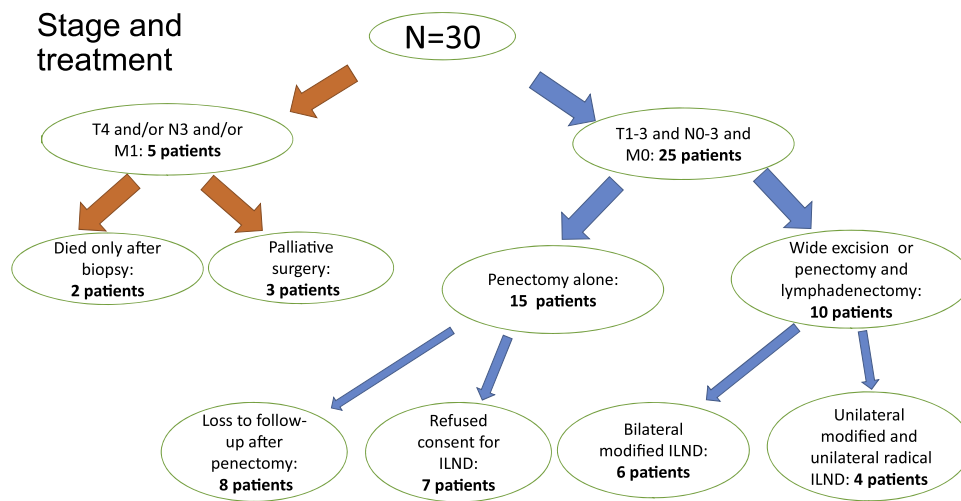
**Table 1** Socio-demographic, clinical and pathological profiles.

Variable (n = 30)	Response	Frequency	Percentage
<b>Socio-demographic profile</b>			
Age group (years)	<50	5	16.7
	50–70	20	66.6
	>70	5	16.7
Level of education	Uneducated	7	23.3
	Primary	18	60
	Secondary	5	16.7
Occupation	Unemployed	26	86.7
	Employed or running a business	4	13.3
<b>Clinical and pathological profiles</b>			
Duration of symptoms	1 year	12	40
	1–5 years	10	33.3
	>5 years	8	26.7
First symptom experienced	Itching/burning/discharge	7	23.3
	Subpreputial swelling	12	40
	Ulceration	8	26.7
	Urethral growth	3	10
Location of initial site	Glands penis	14	46.7
	Prepuce	5	16.7
	Subprepuce	8	26.7
	Urethral meatus	3	10
Comorbidities	HTN	1	3.3
	HIV	6	20
	None	23	76.7
Risk factors	Phimosis	15	50
	Lack of circumcision	30	100
	Lack or sporadic s/preputial hygiene	24	80
	Smoking >5 years	17	56.7
	Lichen sclerosis	4	13.3
T stage in TNM classification	T1	1	3.3
	T2	11	36.7
	T3	17	56.7
	T4	1	3.3
N stage in TNM classification	N0	13	43.3
	N1	6	20.0
	N2	7	23.3
	N3	4	13.3
Early and intermediate complications (n = 11)	SSI (penectomy)	3	10
	Lymphocele	3	10
	Skin necrosis	1	3.3
	In-hospital death	2	6.7
	Meatal stenosis	2	6.7

true for lymphadenectomy. The reason for this was to apply a standardized surgical technique to all patients, teach urology trainees, and shorten the delay due to typically long waiting lists for surgery. Fig. 1 summarizes the disease stage and treatment of the enrolled patients.

Partial penectomy was performed in 24 (80%) patients and 4 (13.3%) patients experienced total penectomy with perineal urethrostomy. All specimen margins were free of tumor after partial penectomy. Of the 30 enrolled patients, 25 (83.3%) were due for treatment with curative intent. However, 8 patients (26.7%) were lost to follow-up after penectomy alone and 7 (23.3%) did not consent to ILND after treatment for the primary tumor. Only 10 (33.3%) patients had both penectomy and bilateral ILND; bilat-

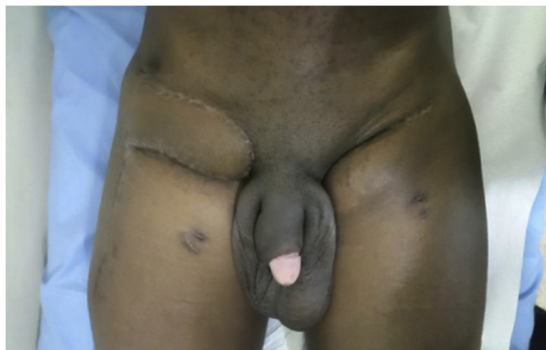eral modified ILND was used in 6 patients and unilateral modified and contralateral radical ILND in 4 patients (Table 2). Of the latter 4 patients, one had a T1 lesion (excised) and unilateral fixed inguinal lymph nodes (Fig. 2). For patients who had penectomy and bilateral modified ILND, both limbs were addressed in one setting after the penectomy wound had been allowed to heal. Patients who had unilateral modified and contralateral radical ILND were operated on in 2 settings, where combined penectomy and modified ILND was followed by radical ILND after wound healing. FNA for the palpable lymph nodes was conducted between the 2 surgeries. The status of the dissected lymph nodes is depicted in Table 2. Of the 30 enrolled patients, five had very advanced disease. These patients are summarized in Table 3.



**Figure 1** Diagram of the disease stage and treatment of the 30 enrolled patients with SCC of the penis.

**Table 2** Characteristics of inguinal lymph nodes (LN) — n = 10.

Number of patients	Number of limbs	Lymphadenectomy	Mean number of LN	Number of positive LN
6	12	Bilateral modified	8.4 (6–14)	0
4	4	Unilateral modified		
	4	Unilateral radical	10.2 (7–19)	7



**Figure 2** Left modified and right radical inguinal lymphadenectomy with a fascia lata myocutaneous flap after sartorius muscle transposition. This was a 33 year-old patient with a pT1N3M0 SCC of the penis. The primary lesion was initially excised.

*Complications and follow-up results*

In-hospital complications included surgical site infection in 3 (10%) patients following penectomy, lymphocele in 3 (10%) patients, skin flap necrosis in one (3.3%) patient, and in-hospital deaths in two (6.7%) patients with metastatic disease. During follow-up, two patients (6.7%) developed a partial urethral meatus stenosis managed by a meatal dilatation in the first patient, and urethral meatus re-fashioning in the second patient. After a minimum of 6 months of follow-up, no tumor recurrence was present either on the primary tumor site or in the inguinal region in all patients treated with curative intent and who were not lost to follow-up (Fig. 2).

**Discussion**

While cancer of the penis is rare in the developed world, it is a significant clinical problem in some developing countries, especially in Africa [2]. However, more epidemiological studies and cancer registries are needed in the most affected parts of the world.

**Table 3** TNM stage and outcome of patients with very advanced disease.

Nr	TNM stage	Pelvic lymph nodes on abdominal CT scan	Lung metastases on chest X-ray	Palliative treatment/early outcome
1	T3N2MX	CT not done	X-ray not done	Died at home after penile biopsy
2	T3N2M1	CT not done	Present	Died in hospital before surgery
3	T3N3M1	Present	Present	Penectomy/discharged
4	T3N3M1	Present	Present	Penectomy/discharged
5	T4N3M1	Pelvic and para-aortic nodes	Present	Penectomy, orchiectomy and scrotal flap on the suprapubic ulcer/died in hospital 2 months later



One example of how the epidemiological data can be misconstrued is that of Uganda, which still wrongly cites penile cancer as the most commonly diagnosed male cancer in Uganda [15]. However, through a regional cancer registry the disease has an incidence rate of 2.2/100,000 in males and does not appear in the 10 most prevalent cancers in the country [2]. In our study, the hospital-based prevalence of penile cancer was estimated to be 0.37/100,000 males in Rwanda. Our study does not reflect the true clinical picture of the problem in the Rwandan population as some patients with penile cancer may not have been diagnosed or reached health facilities. However, there is high coverage of health insurance in Rwanda where more than 90% of the Rwandan population is insured (including the very poor whose health insurance is paid by the government [21]). Consequently, we can assume that the prevalence of penile cancer in health facilities is probably not very different from community prevalence. Nevertheless, further studies are needed to confirm a more accurate prevalence.

The peak age group for diagnosis of penile cancer is reported to be 50–70 years [13,14], an interval that includes the sixth [22] and the seventh [23] decades. Similarly in this study, 66.6% of patients were aged between 50 and 70 years with a median age of 60 years. The lower peak age group of 41–50 years [7] and mean age of 47.9 years [5] found respectively in Tanzania and Kenya, neighbors to Rwanda, should be further investigated since penile cancer in Westernized countries such as the United States and the United Kingdom have peak prevalence in those over 80 years of age.

In this study, phimosis, lack of subpreputial hygiene, and lack of circumcision were the most prevalent risk factors for invasive penile carcinoma. However, HPV was not tested for. Phimosis alone is a strong risk factor with an odds ratio of between 11 and 16 [8,9]. Lack of subpreputial hygiene is equivalent to phimosis in that it leads to build-up of smegma in the preputial sac, resulting in chronic inflammation and fibrosis that precipitates phimosis [24]. Therefore, having found that a large majority (83.3%) of our patients have low or no formal education, the expansion of pre-pubertal circumcision should be considered as the cost-effective means of prevention against invasive penile cancer as supported by the literature [25]. In this study 6 (20%) patients had HIV-driven disease and were on regular anti-retroviral treatment for more than 2 years. However, they had no special disease presentation or progression when compared to their peers who did not have HIV. However an aggressive presentation of penile cancer in HIV patients has been reported by some authors in case reports [26,27]. The HIV prevalence in Rwanda is 3% and it has been stable since 2005 among adults aged 15–49 years [20].

Late presentation was noted in most of the patients in this study. On one hand, the low index of suspicion of penile cancer in peripheral health facilities with a subsequent late transfer may be the cause. On the other hand, as 63.3% of patients reported the first symptom experienced to be itching, discharge, or swelling from the preputial sac, this lack of direct observation of the initial lesion, associated with likely personal neglect of predominantly uneducated patients may have contributed to delayed presentation. Once again, an early decision to circumcise would ease early detection of any penile lesion. In this study, almost all patients presented at an advanced disease stage. This finding is common in developing countries [5,7].

This disease stage pattern is different to the one reported by Lindsay et al. in the United States, where 64.8% of patients presented with a T1 disease and 28.5% of them were able to benefit from a local excision of the primary tumor, hence preserving the penis [3]. This has significant implications for both physical and mental health, and self-esteem of the patient.

Compared to early lymph node surgical staging and management, the historical management of inguinal lymph nodes by surveillance in penile cancer is no longer recommended as it is associated with a higher risk of recurrence [28] and a lower survival rate [29]. In light of this evidence, all pT1–pT3 patients were due for early inguinal lymphadenectomy as per the protocol. Apart from very advanced disease, even clinically fixed lymph nodes can be excised, provided that adequate coverage of exposed femoral vessels is performed using a sartorius muscle transposition and fasciocutaneous fascia lata rotation flap. The refusal of consent for lymphadenectomy and the loss to follow-up noted in 50% of the enrolled patients could be justified by the low level of education in most of the patients. Indeed, once the patient had the foul-smelling primary lesion removed, some patients may have believed they were cured, despite significant counseling. Addressing the primary tumor and inguinal lymph nodes in the same setting may have been the best option to complete the treatment package. However, the limited number of ICU beds and the fear of inguinal wound contamination from infected large, penile lesions in some patients were the main reasons not to combine all surgeries in one session.

The 10 (30%) patients who underwent penectomy and inguinal lymphadenectomy had no recurrence of the primary lesion or the inguinal lymph nodes 6 months after surgery. Further follow-up is ongoing. Of the 4 patients who had radical ILND, two had one positive lymph node each, with no capsular involvement, hence no further pelvic lymphadenectomy was indicated. The two other patients had 2 and 3 positive lymph nodes; one had been HIV-positive for 5 years and was suitable for pelvic lymphadenectomy but refused this intervention, while the other patient was hemiplegic following hypertension complicated with stroke. He was not deemed clinically fit for another operation. Our overall rate of lymphadenectomy was 33.3% and even higher (40%) when only 25 curable patients were considered. This rate is higher than the 26.5% reported in Europe in patients who presented with penile cancer having a clear indication for lymphadenectomy [30]. In this study, the number of lymph nodes was 8.4 (6–14) in modified ILND and 10.25 (7–19) in radical ILND. This number is satisfactory and is in line with 8 lymph nodes recommended by the National Comprehensive Cancer Network (NCCN) for curative surgery in melanoma [31]. In this study, the most common early complication was surgical site infection (10%) after penectomy. This was also a common observation in Tanzania in 236 patients [13] but with a higher rate of infection (44.8%). Our low rate of infection may be justified by the systematic perioperative antibiotic therapy offered, assuming that all large penile lesions were infected prior to surgery. Within 6 months of early follow-up, two (6.7%) patients developed a urethral meatal stricture after partial penectomy. This complication might have been avoided by a proper meatal fashioning or a definitive perineostomy. Of the 20 lymphadenectomies performed (on 10 patients), there was one (5%) skin flap necrosis and three (15%) lymphoceles. A higher complication rate has been shown in inguinal lymphadenectomy even in specialized high volume centers [32].

### Study limitations

Despite a nationwide campaign before patients' enrollment, a number of patients may not have come for treatment. This may have partly distorted the disease epidemiology in our country. In this study, we could not investigate HPV as a risk factor, yet it is known to be a very important risk factor worldwide. As the HPV vaccine is part of the vaccination package in our country but exclusively for females, it is possible that any collected data from males could have informed a gender-neutral vaccine programme.

### Conclusion

The findings of this study show that the burden of penile cancer in Rwanda is not inconsiderable and prompts significant clinical concern and management. Although not generalizable to the whole population of Rwanda, these hospital-based results suggest that more efforts are needed in the prevention against penile cancer. On one hand, efforts should focus on the education of the population in terms of early consultation and behavioral changes such as regular genital hygiene and most importantly neonatal or pre-pubertal circumcision. On the other hand, strengthening of health systems through the raising of index of suspicion of the disease by peripheral healthcare providers for a timely transfer would prevent dramatic consequences of delayed interventions that can mitigate against poor outcomes. Finally, modified ILND should be carried out routinely in penile cancer patients with impalpable inguinal lymph nodes.

### Conflict of interest

The authors declare that they have no competing interests.

### Authors' contributions

E. Ngendahayo and M. Nzayirambaho initiated the research. All authors participated in the design of the study and the drafting of the manuscript. E. Ngendahayo, A. Bonane, G.A. Gasana, R. Ssebuufu, F. Umurangwa, E. Muhawenimana, A. Nyirimodoka, I. Nzeyimana, T. Hategekimana and E. Rwamasirabo prepared clinical management guidelines, enrolled patients, performed surgery and carried out patient follow-up. B. Rugwizangoga, T.Z. Muvunyi, E. Musoni, S. Bwogi and R. Kalengayi analyzed all patient specimens. M. Nzayirambaho and E. Ngendahayo performed data analysis under supervision of E. Rwamasirabo. M. Nzayirambaho and E. Ngendahayo wrote the manuscript in collaboration with all other authors.

### Ethical Committee Approval

Ethical approval was obtained from the Internal Review Board of the University of Rwanda.

### Source of funding

This research was funded by the University of Rwanda through its Research and Post graduate Studies unit. In fact, through a competing process, we applied for the 2014 cycle of Ordinary Research Grants under the University of Rwanda-Sweden collaboration. Fortunately, our proposal was approved and awarded a grant of 16,000,000 Rwanda francs.

### Acknowledgments

The authors acknowledge the contribution of the University of Rwanda for financial support, and those who contributed to the treatment of the enrolled patients.

### References

- [1] Chau A, Netto GJ, Rodríguez IM, Barreto JE, Oertell J, Ocampos S, et al. Epidemiologic profile, sexual history, pathologic features, and human papillomavirus status of 103 patients with penile carcinoma. *World J Urol* 2013;31:861.
- [2] Cancer incidence in five continents, vol. X. Lyon: The International Agency for Research on Cancer; 2014. No. 164.
- [3] Burt Lindsay M, Shrieve Dennis C, Tward Jonathan D. Stage presentation, care patterns, and treatment outcomes for squamous cell carcinoma of the penis. *Int J Radiat Oncol Biol Phys* 2014;88(1):94–100.
- [4] Rajaian S, Gopalakrishnan G, Kekre NS. Auto amputation of penis due to advanced penile carcinoma. *Urology* 2010;75(2):253–4.
- [5] Magoha GAO, Ngumi ZWW. Cancer of the penis at Kenyatta National Hospital. *East Afr Med J* 2000;77:526–30.
- [6] Williams EH. A local cancer registry in a mission hospital in Uganda. *East Afr Med J* 1966;43:200–7.
- [7] Chalya Phillip L, Rambau Peter F, Masalu Nestory, Simbila Samson. Ten-year surgical experiences with penile cancer at a tertiary care hospital in northwestern Tanzania: a retrospective study of 236 patients. *World J Surg Oncol* 2015;13:71.
- [8] Maden C, Sherman KJ, Beckmann AM, Hislop TG, Teh CZ, Ashley RL, et al. History of circumcision, medical conditions, and sexual activity and risk of penile cancer. *J Natl Cancer Inst* 1993;85:19.
- [9] Tsen HF, Morgenstern H, Mack T, Peters RK. Risk factors for penile cancer: results of a population-based case-control study in Los Angeles County (United States). *Cancer Causes Control* 2001;12:267.
- [10] Archier E, Devaux S, Castela E, Gallini A, Aubin F, Le Maître M, et al. Carcinogenic risks of psoralen UV-A therapy and narrowband UV-B therapy in chronic plaque psoriasis: a systematic literature review. *J Eur Acad Dermatol Venereol* 2012;26(Suppl 3):22.
- [11] Stern RS. The risk of squamous cell and basal cell cancer associated with psoralen and ultraviolet A therapy: a 30-year prospective study. *J Am Acad Dermatol* 2012;66:553.
- [12] Stankiewicz E, Kudahetti SC, Prowse DM, Ktori E, Cuzick J, Ambroisine L, et al. HPV infection and immunochemical detection of cell-cycle markers in verrucous carcinoma of the penis. *Mod Pathol* 2009;22:1160.
- [13] Blais Normand, Kassouf Elie. Managing advanced penile cancer in 2014. *Curr Opin Support Palliat Care* 2014;8(September (3)).
- [14] Favorito LA, Nardi AC, Ronalsa M, Zequi SC, Sampaio FJB, Glina S. Epidemiologic study on penile cancer in Brazil. *Int Braz J Urol* 2008;34:587–93.
- [15] Hakenberg OW, Compérat E, Minhas S, Necchi A, Protzel C, Watkin N. EAU guidelines on penile cancer. European Association of Urology; 2016 <https://uroweb.org/wp-content/uploads/EAU-Guidelines-Penile-Cancer-2016-1.pdf>.
- [16] Horenblas S. Lymphadenectomy for squamous cell carcinoma of the penis. Part 2: the role and technique of lymph node dissection. *BJU Int* 2001;88:473–83.
- [17] Ficarra V, Akduman B, Bouchot O, Palou J, Tobias-Machado M. Prognostic factors in penile cancer. *Urology* 2010;76(2):S66–73.
- [18] Protzel C, Ruppin S, Milerski S, Klebingat KJ, Hakenberg OW. The current state of the art of chemotherapy of penile cancer: results of a nationwide survey of German clinics. *Urologe A* 2009;48(December (2)):1495–8, <http://dx.doi.org/10.1007/s00120-009-2108-z> [Article in German].
- [19] Burt LM, Shrieve DC, Tward JD. Stage presentation, care patterns, and treatment outcomes for squamous cell carcinoma of the penis. *Int J Radiat Oncol Biol Phys* 2014;88:94.

- [20] National Institute of Statistics of Rwanda. Rwanda demographic and health survey; 2014–2015.
- [21] Nyandekwe Médard, Nzayirambaho Manassé, Baptiste Kakoma Jean. Universal health coverage in Rwanda: dream or reality. *Pan Afr Med J* 2014;17:232, <http://dx.doi.org/10.11604/pamj.2014.17.232.3471> [Published online 27 March 2014].
- [22] Barnholtz-Sloan JS, Maldonado JL, Pow-sang J, Giuliano AR. Incidence trends in primary malignant penile cancer. *Urol Oncol* 2007;25:361.
- [23] Horner MJ, Ries LAG, Krapcho M, Neyman N, Aminou R, Howlander N, et al. SEER cancer statistics review 1975–2006; 2009.
- [24] Pettaway Curtis A, Crook Juanita M, Pagliaro Lance C. Tumors of the penis. In: Wein Allan J, Kavoussi Louis R, Partin Alan W, Peters Craig A, editors. *Campbell-Walsh urology*. 11th ed. Philadelphia: Elsevier; 2016. p. 846–78.
- [25] Larke Natasha L, Thomas Sara L, dos Santos Silva Isabel, Weiss Helen A. Male circumcision and penile cancer: a systematic review and meta-analysis. *Cancer Control* 2011;22:1097–110.
- [26] Konan PG, Vodi CC, Dekou AH, Fofana A, Gowé EE, Manzan K. Cancer of the penis associated with HIV: a report of three cases presenting at the CHU cocody, Ivory Coast. *BMC Urol* 2015, <http://dx.doi.org/10.1186/s12894-015-0101-y> <https://www.ncbi.nlm.nih.gov/pmc/articles/PMC4647508/>.
- [27] Théodore C, Androulakis N, Spatz A, Goujard C, Blanchet P, Wibault P. An explosive course of squamous cell penile cancer in an AIDS patient. *Ann Oncol* 2002;13:475–9.
- [28] Leijte JAP, Kirrander P, Antonini N, Windahl T, Horenblas S. Recurrence patterns of squamous cell carcinoma of the penis: recommendations for follow-up based on a two-centre analysis of 700 patients. *Eur Urol* 2008;54:161–9.
- [29] Kroon BK, Horenblas S, Lont AP, Tanis PJ, Gallee MP, Nieweg OE. Patients with penile carcinoma benefit from immediate resection of clinically occult lymph node metastases. *J Urol* 2005;173:816–9.
- [30] Johnson Timothy V, Hsiao Wayland, Delman Keith A, Jani Ashesh B, Brawley Otis W, Master Viraj A. Extensive inguinal lymphadenectomy improves overall 5-Year survival in penile cancer patients. *Cancer* 2010;116(12).
- [31] National Cancer Institute. Penile cancer treatment. Atlanta, GA: National Cancer Institute; 2010.
- [32] Stuijver Martijn M, Djajadiningrat Rosa S, Graafland Niels M, Vincent Andrew D, Lucas Cees, Horenblas Simon. Early wound complications after inguinal lymphadenectomy in penile cancer: a historical cohort study and risk-factor analysis. *Eur Urol* 2013;64:486–92.