



Pan African Urological Surgeons' Association

African Journal of Urology

www.ees.elsevier.com/afju
www.sciencedirect.com



Case report

Thoracoscopic repair of renal ectopia associated with congenital diaphragmatic hernia: Report of two cases



R.S. Kamble^{a,*}, R.K. Gupta^a, A.R. Gupta^a, R. Marchant^b,
P.R. Kothari^a, V. Dikshit^a, G.A. Kekre^a, P.S. Patil^a, K. Mudkhedkar^a

^a Department of Pediatric Surgery, LTMMC & LTMG Hospital, Sion, Mumbai, India

^b Consultant Paediatrician, Ex Dean Wadia Hospital, Mumbai, India

Received 14 May 2015; received in revised form 19 June 2015; accepted 24 June 2015

Available online 4 December 2015

KEYWORDS

Congenital diaphragmatic hernia;
Renal ectopia;
Thoracoscopic repair

Abstract

Renal ectopia is a rare anomaly which may occur due to an abnormal ascent of the kidney. It is usually asymptomatic and does not require treatment. Intrathoracic renal ectopia with concomitant congenital diaphragmatic hernia (CDH) is extremely rare. All symptomatic CDH cases must be treated with open or thoracoscopic repair. During plication of the diaphragm, care must be taken to avoid renal injury. Following, we present two rare variants of CDH with concomitant renal ectopia managed thoracoscopically. Post-operative recovery was uneventful. Doppler ultrasound study performed one month after surgery confirmed normal vascularity of the kidneys and the absence of urinary outflow obstruction.

© 2015 Pan African Urological Surgeons' Association. Production and hosting by Elsevier B.V. All rights reserved.

Case presentation

Case 1

An 8-month-old female child presented with cough and fever of 5 days' duration. She had had similar episodes twice before. The

results of hematological investigations and blood gas analysis were within normal limits. Chest radiography done on admission showed a round homogeneous shadow in the left lower part of the thorax in the para-vertebral region (Fig. 1). Thorax CT revealed herniation of the left kidney with its vascular pedicle protruding through a posteromedial defect in the diaphragm. No other organs were involved (Fig. 2).

After treatment of the patient's respiratory condition with antibiotics and nebulization, she was scheduled for thoracoscopic repair. Thoracoscopy revealed a posteromedial defect in the diaphragm with a thin membrane. The left kidney could easily be identified in the

* Corresponding author at: Department of Pediatric Surgery, LTMMC and LTMG Hospital, Sion, Mumbai, Maharashtra 400022, India.
E-mail address: drkambleravi80@gmail.com (R.S. Kamble).

Peer review under responsibility of Pan African Urological Surgeons' Association.

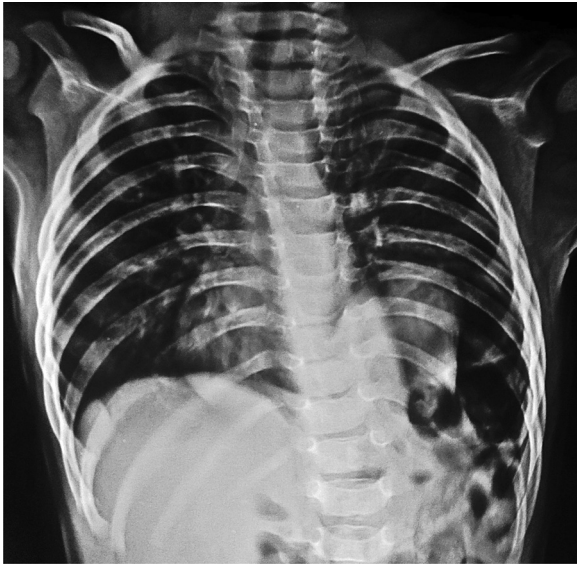

Figure 1 Case 1 – chest radiograph showing a round radio-opaque shadow to the left side of the heart.

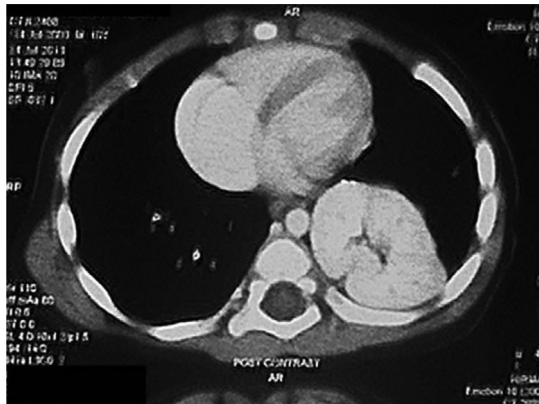


Figure 2 Case 1 – thorax CT showing isolated herniation of the kidney in the left thoracic cavity.

hernia sac (Fig. 3). A pneumothorax was created using the CO₂ insufflator at a pressure of 6 mmHg and a flow rate of 2 L/min. The hernial contents were reduced easily with a little push to the kidney. Plication of the diaphragm was done, taking care to place the sutures at a short distance from the kidney to avoid renal and vascular injury. Post-operative recovery was uneventful. One month after surgery, renal Doppler ultrasonography showed normal vascularity of the left kidney without any narrowing of the renal vessels or urinary outflow obstruction.

Case 2

A 10-year-old female child, a known case of Down's syndrome with a large ventricular septal defect (VSD) and convulsive disorder, presented with a history of dull aching abdominal pain of 2 months' duration. She had a history of repeated attacks of respiratory infection. Chest X-ray showed bilateral infiltrates. The results of hematological investigation were normal, as were those of blood gas analysis. Ultrasonography revealed that the right kidney had been dislocated into the thorax, just above the liver, and that it had

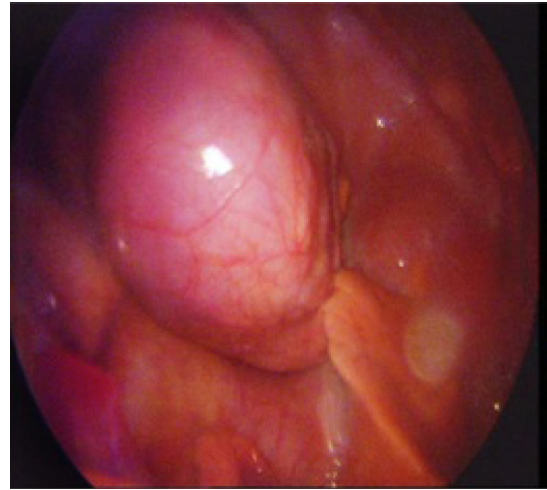


Figure 3 Case 1 – thoracoscopic view of the herniating left kidney.

herniated through a defect in the diaphragm along with some bowel loops. The liver and the left kidney were in their normal positions. CT scan revealed herniation of the right kidney with bowel loops through a posterolateral defect in the right dome of the diaphragm. The right kidney was malrotated and located high up above the liver (Figs. 4 and 5).

After treatment of the child's respiratory condition, she was scheduled for thoracoscopic repair. Thoracoscopy revealed a large posterolateral defect of the diaphragm with a thin membrane (Fig. 6). A bulge in the kidney was seen posteriorly. A pneumothorax was created using the CO₂ insufflator at a pressure of 8 mmHg and a flow rate of 2 L/min. The hernial contents were reduced and plication of the diaphragm was done, taking care to avoid renal and/or vascular injury. Postoperative recovery was uneventful. Abdominal ultrasonography with renal Doppler study carried out one month after surgery showed normal vascularity of the kidney and normal renal vessels without any narrowing or kinking. It also showed that the kidney was located just below the liver and was malrotated, but without any hydronephrosis or hydroureter.

Both patients are on regular follow-up and have not had any renal symptoms since.

Discussion

Renal ectopia is an anomaly, which may occur due to an abnormal ascent of the kidney. Ectopic kidney occurs in one in 1000 patients, but only 1% of these get diagnosed [1]. Mostly, these patients are asymptomatic and the condition is usually detected incidentally during evaluation for unrelated conditions. Intrathoracic renal ectopia is rare and represents less than 5% of all renal ectopia cases [1,2]. The first case of intrathoracic kidney was reported by Wolfromm in 1940 [3].

Pfister-Goedeke and Brunier [4] classified thoracic kidneys into 4 groups: thoracic renal ectopia with closed diaphragm, eventration of the diaphragm, diaphragmatic hernia (congenital diaphragmatic defects or acquired hernia such as Bochdalek hernia), and traumatic rupture of the diaphragm with renal ectopia. Congenital

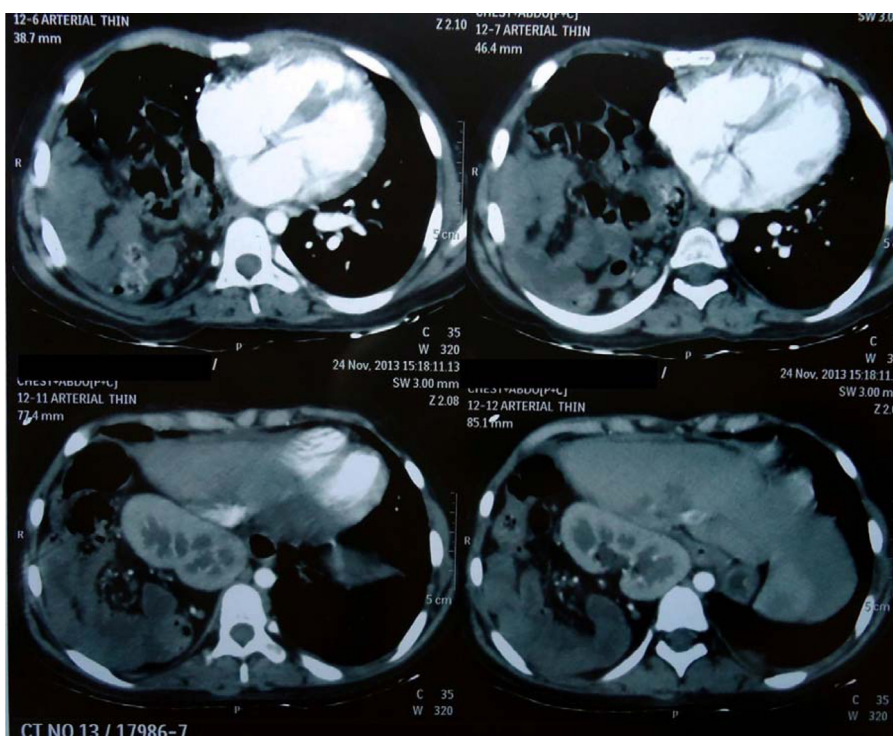


Figure 4 Case 2 – thorax CT showing herniation of bowel and kidney into the right side of the thorax.

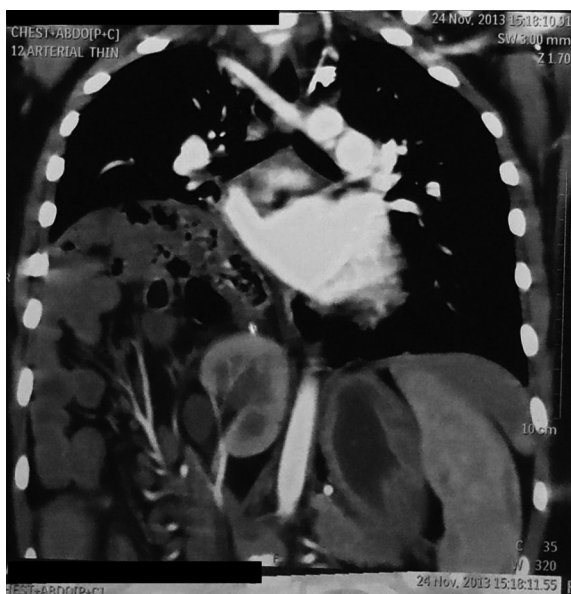


Figure 5 Case 2 – thorax CT showing the long vascular pedicle of the herniating kidney.

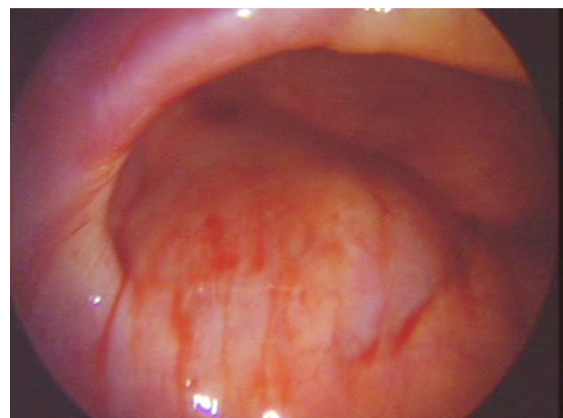


Figure 6 Case 2 – thoracoscopic view of the hernia sac showing renal impression.

diaphragmatic hernia associated with an intrathoracic kidney is found to be rare and accounts for less than 0.25% [2].

Various theories have been proposed to explain the phenomenon of an intrathoracic kidney. An accelerated ascent of the kidney before closure of the diaphragm, i.e. in the 8th week of gestation, is thought to be a possible explanation [5]. A persistence of the nephrogenic

cords in the thorax leading to an intrathoracic kidney has also been suggested [6]. However, none of these theories has been widely accepted.

The location of the thoracic kidney may be supra, infra or trans-diaphragmatic. Anatomical features of the ectopic kidney are a long ureter, a high origin of renal vessels and rotational anomalies. The thoracic kidney in diaphragmatic hernia is mostly mobile and can be easily relocated into the abdomen [7]. Ureteropelvic junction obstruction, vesicoureteric reflux and multicystic renal dysplasia in an intrathoracic kidney have also been reported in the literature [1].

Renal ectopia is usually asymptomatic and does not require treatment. However, all symptomatic CDH cases must be treated with open or thoracoscopic repair.

In case 1 the defect was posteromedial on the left side with an isolated herniation of the kidney which had a long vascular pedicle and a long ureter. The kidney could easily be mobilized and returned to the abdominal cavity.

In case 2 we found a Bochdalek hernia on the right side with herniation of the right kidney along with some bowel loops. This kidney also had a long ureter and vascular pedicle. The contents of the sac could be easily relocated into the abdominal cavity.

In both cases thoracoscopic repair was possible.

Creation of a pneumothorax helped to reduce the contents, and care was taken not to injure the kidney or renal vessels during plication of the diaphragm. Due to the long vascular pedicle and ureter, renal vascularity and urinary outflow were not compromised after repositioning. This was confirmed on ultrasonography and Doppler study of the kidneys one month after surgery.

In some cases, mobilization of the kidney may be difficult, and closure of the diaphragmatic defect may not be easy. The use of Gerota's fascia for closure of the diaphragmatic defect has been reported in the literature [8]. An abdominal muscle flap or a prosthetic mesh can also be used to close the diaphragmatic defect.

In conclusion, the association of diaphragmatic hernia and renal ectopia is rare. In both our cases, one with an isolated renal ectopia with a left-sided congenital diaphragmatic hernia and one with renal ectopia with a right-sided Bochdalek hernia, thoracoscopic repair of the diaphragmatic defect was feasible and beneficial.

Consent

Written informed consent was obtained from the patients' parents for publication of this case report and any accompanying images.

Conflict of interest

None.

Source of funding

None.

References

- [1] Shapiro E, Bauer S, Jeanne S. *Anomalies of the upper urinary tract*. Philadelphia, USA: Campbell's Urology, Saunders; 2012. p. 3138–40.
- [2] Fiaschetti V, Velari L, Gaspari E, Mastrangeli R, Simonetti G. Adult intra-thoracic kidney: a case report of Bochdalek hernia. *Case Rep Med* 2010;2010, pii: 975168. PMID: PMC2939567.
- [3] Wolfroth MG. Situation du rein dans l'événement diaphragmatique droite. *Mémoires. Acad Chir* 1940;60:41–7.
- [4] Pfister-Goedeke L, Brunier E. Intrathoracic kidney in childhood with special reference to secondary renal transport in Bochdalek's hernia. *Helv Paediatr Acta* 1979;34(4):345–457.
- [5] Cullen ML, Klein MD, Philippart AI. Congenital diaphragmatic hernia. *Surg Clin N Am* 1985;65(5):1115–38.
- [6] Aydın HI, Sarici SU, Alpay F, Gokcay E. Thoracic ectopic kidney in a child: a case report. *Turk J Pediatr* 2000;42:253–5.
- [7] Kageyama Y, Kihara K, Oshima H. Intrathoracic herniation of the kidney. *Urology* 2000;55:143–4.
- [8] Sözübir S, Demir H, Ekingen G, Güvenc BH. Ectopic thoracic kidney in a child with congenital diaphragmatic hernia. *Eur J Pediatr Surg* 2005;15:206–9.