



Pan African Urological Surgeons' Association

**African Journal of Urology**

[www.ees.elsevier.com/afju](http://www.ees.elsevier.com/afju)  
[www.sciencedirect.com](http://www.sciencedirect.com)



# Management of encrusted ureteral stents

Y. Dakkak \*, A. Janane , T. Ould-Ismail , M. Ghadouane , A. Ameer , M. Abbar

Mohammed V Military Hospital of Rabat, Morocco

Received 1 November 2011; received in revised form 18 May 2012; accepted 14 July 2012

## KEYWORDS

Ureteral stent;  
JJ stent;  
Encrustation

## Abstract

*Objectives:* To present our experience in managing encrusted ureteral stents and to review the literature on the subject.

*Methods:* A total of 22 patients with encrusted ureteral stent were treated in our department. Encrustation of the stent and associated stone burden were evaluated using plain radiography, sometimes supplemented by intravenous urography or ultrasonography. The treatment method was determined by the site of encrustation, the size of the stone burden and the availability of endourologic equipment.

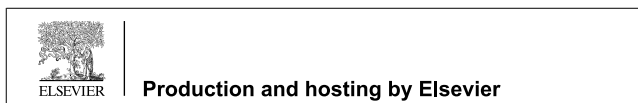*Results:* Stents were inserted for stone disease in 17 patients, for congenital abnormality in 3 and for ureteric obstruction by malignancy in 2. Stents were left in place for a mean of 10.8 months (range 5–34 months). The site of encrustation was in the bladder in 15 (68.2%), ureter in 13 (59%) and kidney in 8 patients (36.4%); more than one site was involved in 11 (50%) cases. For upper coil encrustations, retrograde ureterorenoscopy was performed in 9 cases, percutaneous nephrolithotomy in 4 and open pyelolithotomy in 2. For lower coil encrustation, fragmentation by grasper and/or transurethral cystolithotripsy was attempted in 11 cases, and suprapubic cystolithotomy was required for failure in 7 cases. Sixteen patients (72.7%) were rendered stone-free and 5 (22.7%) had clinically insignificant residual stones (3 mm or less).

*Conclusions:* Encrustation is one of the most difficult complications of ureteral stents and its management is a complex clinical scenario for the treating surgeon. The combination of several surgical techniques is often necessary but the best treatment remains the prevention of this problem by providing patient education.

© 2012 Production and hosting by Elsevier B.V. on behalf of Pan African Urological Surgeons' Association.

\* Corresponding author at: Department of Urology, Mohammed V Military Hospital of Rabat, Morocco. Tel.: +212 661257146; fax: +212 537776432. E-mail address: [y.dakkak@hotmail.com](mailto:y.dakkak@hotmail.com) (Y. Dakkak).

Peer review under responsibility of Pan African Urological Surgeons' Association.



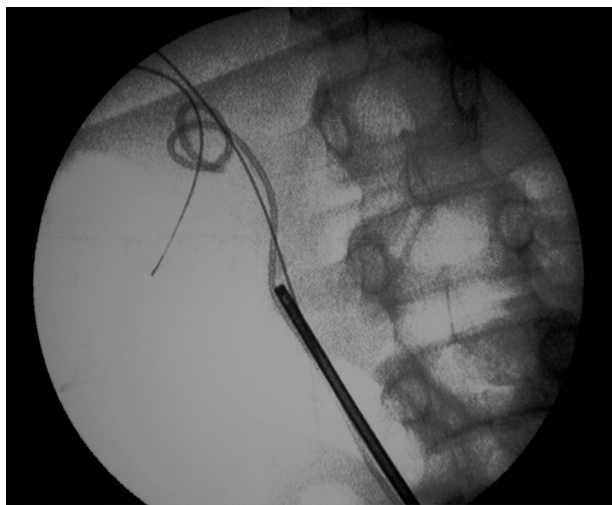
Production and hosting by Elsevier

## Introduction

Ureteral stents have become a fundamental part of urological practice. They are chiefly used for managing ureteral obstruction due to intrinsic or extrinsic causes (stones, tumours, and fibrosis) and for providing drainage after ureteral surgery or iatrogenic injuries. However, some problems related to their use still occur despite the improvements in materials and design. A well-known complication of this situation is stent encrustation, which can result in significant morbidity such as stone formation, recurrent obstruction and urinary tract infection (UTI). Various procedures can be used for the retrieval of encrusted stents. We present our experience with the management of this complication.

## Subjects and methods

Twenty-two patients (18 men and 4 women) were admitted to our department with a retained encrusted ureteral stent between January 2002 and October 2011. Information was obtained through a retrospective study of the patients' records. A retained ureteral stent was defined as one that could not be removed at the first attempt using gentle manual traction with grasping forceps passed through a cystoscope under local anaesthesia. All the patients were thoroughly evaluated for stent encrustation and stone burden by plain-film radiography, sometimes supplemented by intravenous urography (6 cases) or ultrasonography (5 cases). Serum creatinine measurement and urinalysis with culture were also performed to evaluate renal function and to detect UTI. Retrograde ureteroscopy using a 7.5F rigid ureteroscope and intra-corporeal lithotripsy with a pneumatic lithotripter were used as initial treatment for encrustation involving the stent body. The ureteroscope was advanced beside the retained stent and lithotripsy was used to fragment encrustations on and around the stent (Fig. 1). Thereafter, an attempt was made to retrieve the stent with the help of a ureteroscopic grasper. If this technique failed, if encrustations involved the upper coil of the stent, percutaneous nephrolithotomy (PCNL) using a rigid 24F nephroscope or open nephrolithotomy was performed. If encrustations involved the lower coil of the stent, fragmentation was performed using a rigid grasper or transurethral cystolithotripsy. If the endovesical options failed, open surgery was performed to remove the stone

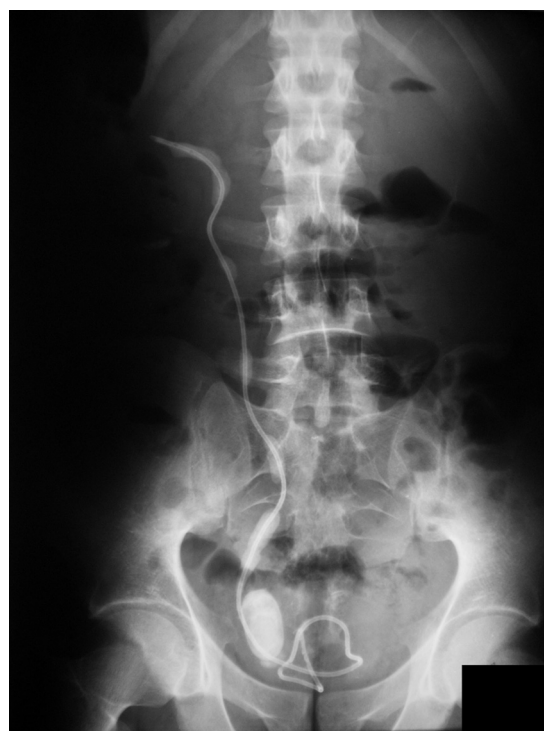

**Figure 1** Fluoroscopic image showing the ureterscope beside the retained ureteral stent.

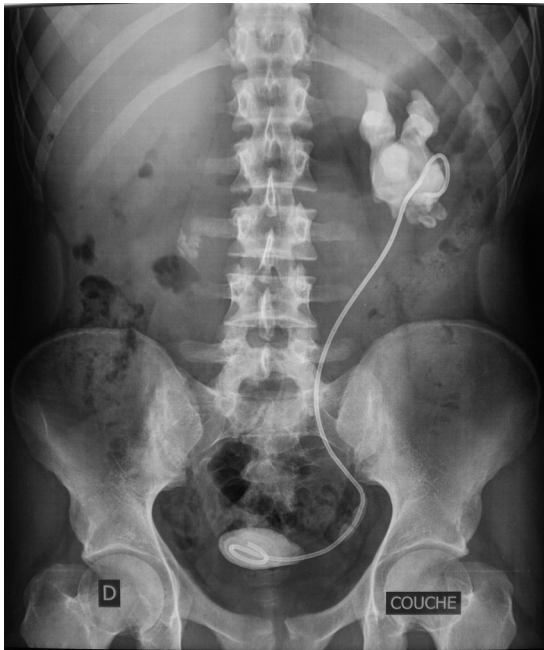
and the encrusted stent. Postoperatively, plain-film radiography was obtained to confirm the stone-free and stent-free status.

## Results

The mean patient age was 33.4 years (range 7–64 years). Stents were left in place for a mean of 10.8 months (range 5–34 months), 5 stents (22.7%) were indwelling for 5–6 months and 5 (22.7%) were indwelling for  $\geq 12$  months. Seventeen patients (77.3%) had required stenting due to obstruction caused by stone disease. In two cases, the stent had been placed to prevent obstruction by malignancy (uterine choriocarcinoma and cervical cancer). The stent was inserted after endopyelotomy for pelvi-ureteric junction obstruction, after surgery for megaureter and after surgery for a retroiliac ureter in one case each. Encrustations were radiopaque in 20 cases (90.1%). Renal function was preserved in all cases. UTI was found in 10 cases (45.5%). Encrustations were localized to the stent coils and/or throughout the length of the stent body (Figs. 2 and 3). The site of encrustation was in the bladder in 15 (68.2%), ureter in 13 (59%) and kidney in 8 patients (36.4%); more than one site was involved in 11 (50%) cases. Extracorporeal shock-wave lithotripsy (ESWL) was used unsuccessfully in three patients (13.6%) before referral to our department. For lower coil encrustation, fragmentation by grasper and/or transurethral cystolithotripsy was attempted in 11 cases, and suprapubic cystolithotomy was required for failure in 7 cases. For upper coil encrustations, retrograde ureterorenoscopy was performed in 9 cases, PCNL in 4 and open pyelolithotomy in 2. A single anesthetic session was required in 18 patients (81.8%) and a second session was necessary in 4 patients due to breakage of the stent at the first attempt at removal. No intraoperative complications occurred in any patient. All the stents were removed intact, except



**Figure 2** Plain-film radiograph showing encrusted ureteral stent with large stone burden in bladder, kidney and ureter.



**Figure 3** Plain-film radiograph showing encrusted ureteral stent with large stone burden in bladder, kidney and lower part of ureter.

in 4 patients (Fig. 4). Examination of the broken stents showed that breaks had occurred at points where the encrustation had made the stent very brittle. All the removed encrusted stents were made of silicone. Sixteen patients (72.7%) were rendered stone-free and 5 (22.7%) had clinically insignificant residual stones (3 mm or less). The mean hospital stay was 3.8 days (range 1–9 days).



**Figure 4** Examples of removed ureteral stents.

## Discussion

Encrustation of forgotten ureteral stents is a serious problem, especially when a large stone burden has developed. The main causes of this complication are poor patient compliance with instructions to return for stent removal, and inadequate counsel by practitioners. The exact mechanism of encrustation is not clear. However, it appears to be dependent on several factors [1–6]. UTI is one of these factors. Urease produced by bacteria hydrolyses urea in the urine to produce ammonia causing elevated urinary pH and favoring the precipitation of magnesium and calcium as struvite and hydroxyapatite onto the stent surface [5,7]. Duration of placement is another factor: various authors have reported that indwelling time between 2 and 4 months is safe [8–12]. Patients requiring stents beyond this period should be kept on prophylactic antibiotics and have their stents frequently changed. Stent material may contribute to encrustation: silicone containing stents tend to be more resistant to encrustation, followed by polyurethane, silitek, percutflex and hydrogel coated polyurethane [13]. Other factors include urinary composition (hypercalciuria, hyperoxaluria, hypocitraturia, homocystinuria, and hyperuricosuria), a history of urolithiasis, and congenital urinary tract anomalies. Malignancy predisposes to stent encrustation, possibly due to urinary stasis induced by dehydration and poor fluid intake, chemotherapy-induced hyperuricosuria, persistent or recurrent UTI, multiple serial stents, and poor compliance [14].

Stent breakage is sometimes associated with encrustation in forgotten stents. Stents may fracture spontaneously after being in situ for a long time, due to hardening and loss of tensile strength [15].

Most studies showed a predominance of encrustation at the upper coil of the stent. This may be because more effective peristalsis at the lower part of the stent sweeps any deposits off the stent, thus minimizing encrustation at the lower end [6,14]. In this study, stent encrustation was more common in the bladder (68.2%) and ureter (59%) than in the kidney (36.4%), possibly because urine remains in the bladder for a longer time than in the upper urinary tract.

The management of ureteral stents with encrustation remains a challenging task for urologists. The site of encrustation, the size of the stone burden and the function of the affected kidney dictate the method of treatment. Very often, multiple approaches are needed because of encrustations involving the bladder, ureter and kidney [4,8,11,14–17].

For encrustations located at the upper coil and/or stent body, ESWL has been reported to be a non-invasive and effective first line therapy [10,11,18,19]. The shock waves can be directed at the proximal or ureteral part of the encrusted stent under fluoroscopic guidance. ESWL is indicated mainly for localized, low volume encrustations [20,21].

Ureteroscopy using pneumatic or ultrasonic lithotripsy may also be attempted, either as first-line therapy or after failure of ESWL [9,14,22,23]. Flexible ureteroscopy with holmium laser lithotripsy is an alternative minimally invasive treatment option [19,22,24,25]. More invasive procedures, such as PCNL or open pyelolithotomy are often necessary for treating a severely encrusted stent [11,15].

Encrustations located at the lower coil are generally managed by endovesical procedures (cystolithotripsy, cystolithopaxy or manual fragmentation) [4,5,18].

One must evaluate preoperatively the exact size and location of the stone burden, determine the point at which the stent is stuck and then manage it accordingly to minimize the number of therapeutic sessions and so the morbidity of additional procedures. However, therapeutic strategy is also determined by the availability of technology. In this series lower coil encrustations were managed by forceps fragmentation before the availability of endovesical lithotripsy. Similarly, for upper coil encrustations open pyelolithotomy was used when PCNL was not yet available.

Although encrusted stents can be managed successfully in the majority of cases, the best treatment is prevention. Patients must be counselled as to when their stent should be changed, and must be tracked very closely. It is advisable to maintain a record of all stents inserted and to keep track of their date of removal. Some authors have proposed the use of a computer tracking program to ensure that stents are removed or changed in a timely fashion. Ather et al. reported a significantly lower incidence of overdue ureteral stents (from 12.5% to 1.2% during a 1-year period) by the use of a computer program [26].

### Conclusion

Stent encrustation constitutes one of the most difficult complications of ureteral stents. Its management is a complex clinical scenario for the treating surgeon. Accurately determining the location and the degree of encrustation is an important part of preoperative planning. Most encrusted and retained ureteral stents can be removed using endoscopic techniques. This minimally invasive approach is recommended as first-line therapy. Open surgery is an option if endourology fails or in the presence of a large stone burden. However, the best treatment is the prevention of this complication by providing detailed patient education and developing a computerized tracking system.

### References

- [1] Keane PF, Bonner MC, Johnston SR, Zafar A, Gorman SP. Characterization of biofilm and encrustation on ureteric stents in vivo. *British Journal of Urology* 1994;73(June (6)):687–91.
- [2] Schulze KA, Wettlaufer JN, Oldani G. Encrustation and stone formation: complication of indwelling ureteral stents. *Urology* 1985;25(June (6)):616–9.
- [3] El-Faqih SR, Shamsuddin AB, Chakrabarti A, Atassi R, Kardar AH, Osman MK, et al. Polyurethane internal ureteral stents in treatment of stone patients: morbidity related to indwelling times. *Journal of Urology* 1991;146(December (6)):1487–91.
- [4] Borboroglu PG, Kane CJ. Current management of severely encrusted ureteral stents with a large associated stone burden. *Journal of Urology* 2000;164(September (3 Pt 1)):648–50.
- [5] Robert M, Boularan AM, El Sandid M, Grasset D. Double-J ureteric stent encrustations: clinical study on crystal formation on polyurethane stents. *Urologia Internationalis* 1997;58(2):100–4.
- [6] Finney RP. Double-J and diversion stents. *Urologic Clinics of North America* 1982;9(February (1)):89–94.
- [7] Wollin TA, Tieszer C, Riddell JV, Denstedt JD, Reid G. Bacterial biofilm formation, encrustation, and antibiotic adsorption to ureteral stents indwelling in humans. *Journal of Endourology* 1998;12(April (2)):101–11.
- [8] Monga M, Klein E, Castañeda-Zúñiga WR, Thomas R. The forgotten indwelling ureteral stent: a urological dilemma. *Journal of Urology* 1995;153(June (6)):1817–9.
- [9] Mohan-Pillai K, Keeley Jr FX, Moussa SA, Smith G, Tolley DA. Endourological management of severely encrusted ureteral stents. *Journal of Endourology* 1999;13(June (5)):377–9.
- [10] Flam TA, Brochard M, Zerbib M, Debre B, Steg A. Extracorporeal shock-wave lithotripsy to remove calcified ureteral stents. *Urology* 1990;36(August (2)):164–5.
- [11] Somers WJ. Management of forgotten or retained indwelling ureteral stents. *Urology* 1996;47(March (3)):431–5.
- [12] Kawahara T, Ito H, Terao H, Yoshida M, Matsuzaki J. Ureteral stent encrustation, incrustation, and coloring: morbidity related to indwelling times. *Journal of Endourology* 2012;26(February (2)):178–82 [Epub 2011 October 18].
- [13] Tunney MM, Keane PF, Jones DS, Gorman SP. Comparative assessment of ureteral stent biomaterial encrustation. *Biomaterials* 1996;17(August (15)):1541–6.
- [14] Singh I, Gupta NP, Hemal AK, Aron M, Seth A, Dogra PN. Severely encrusted polyurethane ureteral stents: management and analysis of potential risk factors. *Urology* 2001;58(October (4)):526–31.
- [15] Mursi K, Fayad A, Ghoneim I, El-Ghamrawy H. Stones on a forgotten double-J stent: a case report of multiple stones casting a multi-fractured ureteral stent. *African Journal of Urology* 2005;11(3):247–9.
- [16] Weedon JW, Coburn M, Link RE. The impact of proximal stone burden on the management of encrusted and retained ureteral stents. *Journal of Urology* 2011;185(February (2)):542–7 [Epub 2010 December 18].
- [17] Rana AM, Sabooh A. Management strategies and results for severely encrusted retained ureteral stents. *Journal of Endourology* 2007;21(June (6)):628–32.
- [18] Shandera KC. Minimally invasive management of the calcified ureteral stent. *Techniques in Urology* 1997;3(Spring (1)):54–7.
- [19] Vanderbrink BA, Rastinehad AR, Ost MC, Smith AD. Encrusted urinary stents: evaluation and endourologic management. *Journal of Endourology* 2008;22(May (5)):905–12.
- [20] Aravantinos E, Gravas S, Karatzas AD, Tzortzis V, Melekos M. Forgotten, encrusted ureteral stents: a challenging problem with an endourologic solution. *Journal of Endourology* 2006;20(December (12)):1045–9.
- [21] Ahallal Y, Khallouk A, El Fassi MJ, Farih MH. Risk factor analysis and management of ureteral double-J stent complications. *Reviews in Urology* 2010;12(Spring (2–3)):e147–51.
- [22] Bukkapatnam R, Seigne J, Helal M. 1-step removal of encrusted retained ureteral stents. *Journal of Urology* 2003;170(October (4 Pt 1)):1111–4.
- [23] Murthy KV, Reddy SJ, Prasad DV. Endourological management of forgotten encrusted ureteral stents. *International Brazilian Journal of Urology* 2010;36(July–August (4)):420–9.
- [24] Xu C, Tang H, Gao X, Gao X, Yang B, Sun Y. Management of forgotten ureteral stents with holmium laser. *Lasers in Medical Science* 2009;24(March (2)):140–3 [Epub 2008 January 10].
- [25] Kawahara T, Ito H, Terao H, Ogawa T, Uemura H, Kubota Y, et al. Encrusted ureteral stent retrieval using flexible ureteroscopy with a Ho: YAG Laser. *Case Reports in Medicine* 2012;2012:862539 [Epub 2012 April 3].
- [26] Ather MH, Talati J, Biyabani R. Physician responsibility for removal of implants: the case for a computerized program for tracking overdue double-J stents. *Techniques in Urology* 2000;6(September (3)):189–92.