

**Case Report****Darning Needle Impacted in the Male Urethra****S. L. Singla, S. Parshad, O. Jindal and S. Sharma***Department of Surgery, Pandit Bhagwat Dayal Sharma Post Graduate Institute of Medical Sciences (PGIMS), Rohtak, Haryana, India***ABSTRACT**

Foreign bodies of varied nature have been introduced into the urethra to achieve sexual stimulation. We report the case of a long (9.5 cm) darning needle impacted in the urethra of a male patient following urethral masturbation. After a failed trial at endoscopic extraction the needle had to be removed via open surgery. Follow-up was uneventful.

**Key Words:** Needle, foreign body, sexual stimulation, male urethra.

**Corresponding Author:** Dr Sanjeev Parshad, 22/9J, Medical Campus, PGIMS, Rohtak, Haryana (India)  
E-mail: [sanjeevparshad@rediffmail.co](mailto:sanjeevparshad@rediffmail.co)

**Article Info :** Date received: 28/08/2008

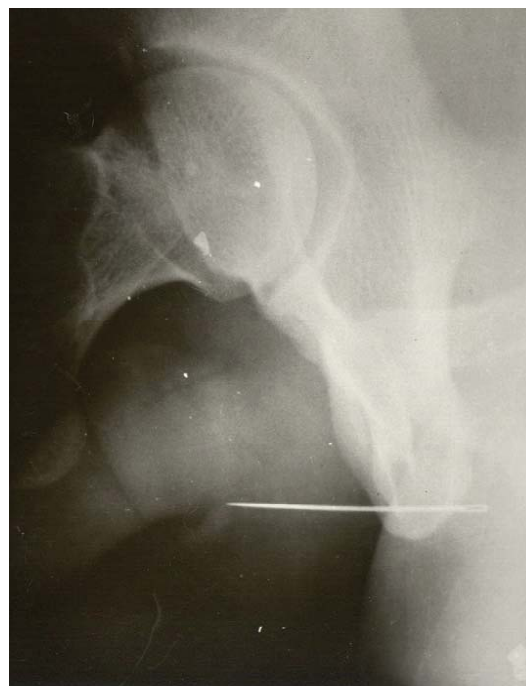
Date accepted (after revision): 19/12/2008

**INTRODUCTION**

Foreign bodies of varied nature have been introduced into the urethra for sexual stimulation<sup>1</sup>. Sometimes these move too far into the urethra to be retrieved by the individual. The management of each such case has to be decided individually, depending on the size, mobility and location of the foreign body. The varieties of foreign bodies that have been introduced into the urethra defy imagination<sup>1</sup>. We report the case of a 9.5 cm long darning needle, impacted in the anterior urethra of an adult male following masturbation.

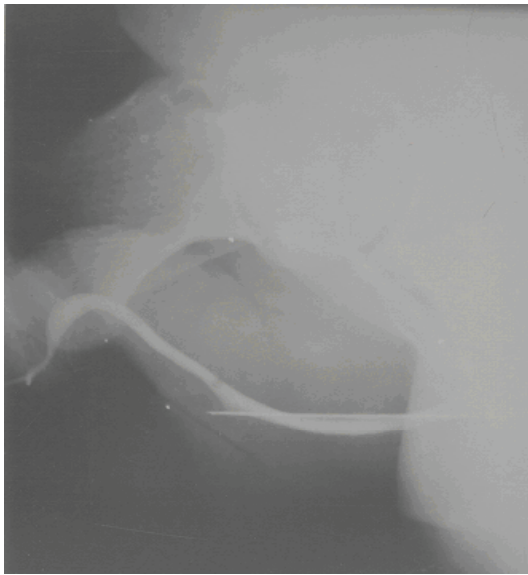
**CASE REPORT**

A 22-year-old man presented with dysuria and severe pain in the perineum for the preceding 24 hours. He reported self-introduction (without the aid of a sexual partner) of a steel needle for urethral masturbation about 24 hours earlier. He had performed this act regularly during the past year, but was unable to retrieve the needle this time. There was blood at the external meatus and a hard, linear object could be palpated, extending from the mid-shaft of the penis to the perineum. A lateral abdominal X-ray confirmed



**Fig. 1:** Abdominal X-ray (lateral view) showing the darning needle impacted in the urethra.

it to be a darning needle (Fig. 1). Retrograde urethrography showed that the needle was located in the proximal anterior urethra with its sharp end impacted in the urethral wall (Fig.

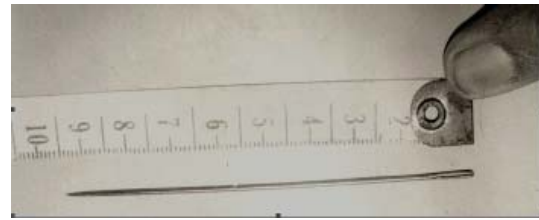


**Fig. 2:** Retrograde urethrogram showing an impacted darning needle in the anterior urethra.

2). Extraction using a foreign body forceps was unsuccessful. To avoid further damage to the urethra, forceful disimpaction was not attempted and open surgical extraction was planned. A small incision was made in the skin over the sharp distal end of the needle. The needle was forced through the inferior wall of the urethra and extracted without resorting to formal urethrotomy. The skin incision was closed with a single silk suture and a Foley's catheter was inserted for 48 hours. Peri-operatively the patient was given broad spectrum antibiotics (ampicillin and gentamycin). Urine culture demonstrated *E. coli* sensitive to gentamycin, which was continued for 7 days post-operatively. No post-operative complications were encountered. The patient was discharged on the third post-operative day following removal of the catheter. Follow-up using retrograde urethrography and uroflow studies at three-month intervals for one year was uneventful; the patient remained asymptomatic without any signs of urethral stricture.

## DISCUSSION

A variety of bizarre objects, such as peas, chalk, pencils, small pins, needles, fish hooks, hair clips, thermometers, pieces of candle, wires, rifle bullets, a decapitated snake, fish,



**Fig. 3 :** 9.5 cm long darning needle specimen.

lobster tentacles and safety pins, to name a few, have been reported as foreign bodies in the urethra<sup>1-7</sup>. Most of these were introduced in order to obtain sexual stimulation. Senility, a state of inebriation, urethral itching, childhood exploratory activities and physical assault are other reported causes<sup>1,2,4</sup>.

Needles have been used for urethral masturbation<sup>3,8</sup> and our patient used a 9.5 cm long darning needle for the same purpose.

Foreign bodies in the urethra may cause symptoms, such as urinary frequency, dysuria, nocturia, hematuria, gross bleeding per urethram, urinary retention or occasionally priapism<sup>1,4</sup> as a result of mechanical urethritis. Periurethral abscess or ascending genitourinary infection, septicemia and death have also been reported<sup>9</sup>. Needles may remain impacted in the urethra for some time before they cause local sepsis as reported by Campbell. His patient who presented with dysuria and urethral discharge was treated as a case of gonorrhoea but later confessed that he had inserted two darning needles (5 cm long) into the urethra 2 weeks before. Periurethral abscess developed and subsequent external urethrotomy was curative<sup>3</sup>.

Methods for the removal of foreign bodies include endoscopic techniques, milking, magnetic extraction, Fogarty balloon catheterisation, injection of solvents or open procedures like meatotomy, external urethrotomy, suprapubic cystostomy and percutaneous transvesical removal using laparoscopy instruments<sup>1,4,6,8</sup>. In a recent review, it was observed that groping with clamps for foreign bodies within the urethra is often unsuccessful<sup>1</sup>.

Our patient presented within 24 hours due to pain and dysuria. Urethrosopic extraction of the needle was tried, but failed because the needle was quite long (9.5 cm) (Fig.3) and its proximal end could not be pushed further proximally into the prostatic urethra. Forceful endoscopic disimpaction might have succeeded, but this would have led to further trauma to the urethral bulb. The technique recommended by Mitchell for the retrieval of a needle in the urethra was used in our case<sup>10</sup>.

We conclude that the management of foreign bodies in the urethra has to be decided individually for each case, depending on the size, mobility and location of the foreign body. The method chosen has to ensure the least possible trauma to the urethra to avoid further complications.

## REFERENCES

1. Van Ophoven A, deKernion JB. Clinical management of foreign bodies of the genitourinary tract. *J.Urol.* 2000; Aug;164(2):274-87.
2. Al Durazi M, Saleem I, Mohammed AA. Urethral foreign body. *Br.J.Urol.* 1992; Apr;69(4):434.
3. Campbell MF. Needles in the deep urethra, stone and periurethral abscess - Case report in a seven-year-old boy. *Am.J.Surg.* 1933;;21:452.
4. Ali Khan S, Kaiser CW, Dailey B, Krane R. Unusual foreign body in the urethra. *Urol.Int.* 1984;39(3):184-6.
5. Wadhwa SN, Luthra AK, Hemel AK. Safety pin in the urethra. *Trop.Doct.* 1991; Oct;21(4):179.
6. Ansari MS, Goel A, Hemal AK, Gupta NP. Open thumb forceps. An unusual foreign body in the urethra: Technique of its removal. *Urol.Int.* 2000;64(1):43-4.
7. Herman JR. Candiru: Urinophilic catfish. Its gift to urology. *Urology.* 1973; Mar;1(3):265-7.
8. Thomas WJC. Unusual presentation of retained urethral foreign body with review of other cases. *Br.J.Surg.* 1964;51(12):921-2.
9. Pec J, Straka S, Novomesky F, Kliment J, Pec M, Lazarova Z. Mechanical urethritis and ascendent genitourinary infections due to sexual stimulation of the urethra by inserted foreign bodies. *Genitourin.Med.* 1992; Dec;68(6):399-400.
10. Mitchell JP. The urethra. In: Bailey H, Dudley HAF, editors. *Hamilton Bailey's Emergency Surgery.* 11<sup>th</sup> ed.: Butterworth-Heinemann; 1986. p. 522-33.