

# Giant simple hepatic cyst: a case report and review of relevant literature

Maurice Asuquo<sup>1</sup>, Victor Nwagbara<sup>1</sup>, Cyril Agbor<sup>1</sup>, Fidelis Ootobo<sup>1</sup>, Ayodele Omotoso<sup>2</sup>

1. University of Calabar Teaching Hospital, Calabar, Surgery
2. University of Calabar Teaching Hospital, Pathology

## Abstract

**Background:** Giant cysts of the liver are uncommon. Symptoms are related primarily to the mass effect of the enlarging cyst.

**Objective:** To highlight the challenges of management of giant simple hepatic cyst in a resource limited setting.

**Case report:** Presented is a 58-year-old seamstress with a 5-year history of an enlarging abdominal mass with easy satiety. Surgery revealed an exophytic giant simple hepatic cyst arising from liver segment IV that drained 4.6 litres of serous fluid.

**Conclusion:** Simple hepatic cyst can attain giant dimensions and should be considered in the differential diagnosis of intra-abdominal masses.

**Keywords:** Laparotomy, giant hepatic cyst, drainage, wide excision

**DOI:** <http://dx.doi.org/10.4314/ahs.v15i1.40>

## Introduction

The term hepatic cyst usually refers to solitary non-parasitic cysts of the liver also known as simple cysts<sup>1,2</sup>. Giant cysts of the liver are uncommon<sup>3</sup>. The cause of simple liver cysts is not known, but they are believed to be congenital in origin<sup>1</sup>. Simple hepatic cysts rarely cause symptoms, however they become symptomatic due to mass effect, rupture, haemorrhage, and infection. Large cysts can produce atrophy of the adjacent hepatic tissue while huge cysts can cause complete atrophy of a hepatic lobe with compensatory hypertrophy of the other side<sup>4</sup>. The optimal management of non-parasitic hepatic cyst is a topic of debate<sup>5</sup>. Management options include percutaneous aspiration, injection of sclerosing agents, laparoscopic or open fenestration, and surgical cystectomy<sup>6</sup>. We report a case of giant hepatic cyst that presented with an abdominal mass with gross disten-

sion of the abdomen to highlight management challenges in a resource-limited setting.

## Case report

A 58-year-old seamstress presented with a progressively increasing abdominal mass of 5 years duration. Pain that was localised over the mass had been recurrent in the past 2 years. There was no prior history of trauma, no associated fever, nausea and vomiting. She however admitted to a history of easy satiety noticed over the past 2 years but not associated with any weight loss. There was no history of yellowness of the eyes, breathlessness, vomiting of blood, passage of blood in stool, and swelling of the lower extremities.

Examination showed a lady in good nutritional status. She was neither pale nor icteric. Her vital signs were within normal limits. The abdomen was asymmetrically enlarged more in the right upper quadrant with a palpable mass lesion measuring 24cm x 20cm and extending below the umbilicus. The mass had limited horizontal mobility and was intra-abdominal in location. Palpation of the liver and balloting of the right kidney was limited by the mass. The left kidney and spleen were palpably normal. Percussion notes were very dull over the mass and bowel sounds were normoactive. Digital rectal examination was unremarkable.

Haemogram showed a haemoglobin of 12.1g/dl, white blood cells (WBC) 6.5x10<sup>3</sup>/ul (neutrophils

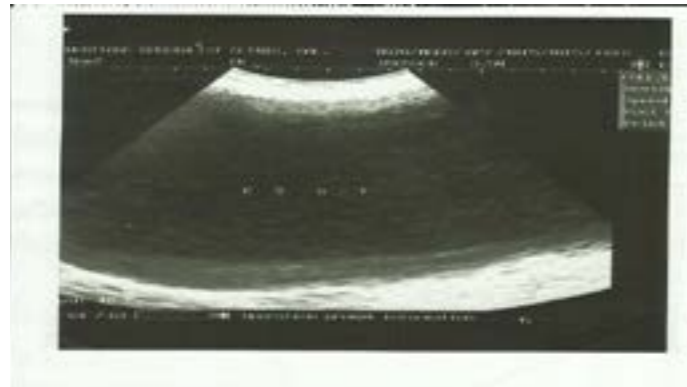### Corresponding author:

Maurice Asuquo  
University of Calabar Teaching Hospital,  
Calabar, Nigeria  
Email: [mauefas@yahoo.com](mailto:mauefas@yahoo.com)

81%, eosinophils 6%, lymphocytes 13%), and platelets 298x103/ul. Urea and electrolytes, liver function tests (Total bilirubin – 11.4umol/l, conjugated bilirubin– 4.2umol/l, AST – 30.1umol/l, ALT – 24.7umol/l, ALP – 89.9umol/l) were normal. She was hepatitis B virus (HBV) and hepatitis C virus (HCV) negative. Radiology

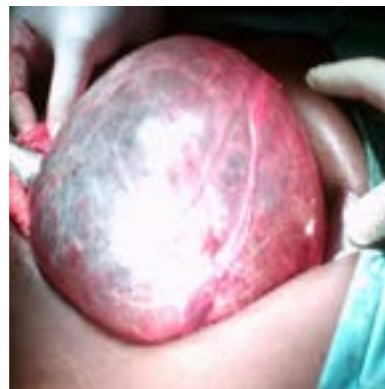showed a normal chest X-ray, abdominal ultrasonography (Figure 1), reported an extensive hypodense cystic mass that filled most of the abdomen probably omental cyst or mesenteric cyst. The liver was reported as normal. A preoperative diagnosis of an intra-abdominal cyst was made.

**Figure 1: Abdominal ultrasonography**



The patient was operated upon electively under general anaesthesia with endotracheal intubation and the operative findings were:

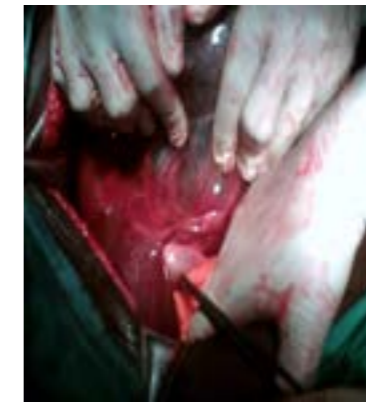
1. A giant thin walled solitary hepatic cyst (Figure 2)



**Figure 2: Giant hepatic cyst in situ.**

2. The cyst involved liver segment IV, extended extrahepatically into the abdomen and compressed liver segments II and III that appeared thinned out, Figure 3

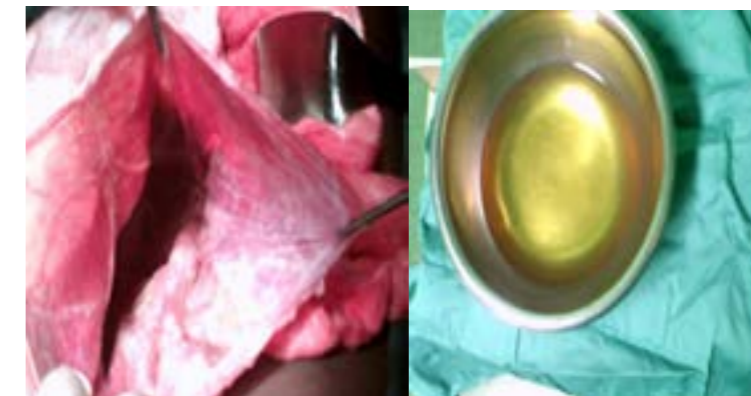
showed liver segments V, VI, VII, and VIII on the right side of the cyst, (Couinaud's line), it appeared normal with the gallbladder intact.



**Figure 3: Right functional lobe of the liver (with gallbladder) showing the cyst on the left side of Couinaud's line.**

3. The stomach and small intestine were normal but compressed by the cyst and the ileum displaced to the lower abdomen. Other viscera were intact.

The cyst was opened and about 4.6 litres of serous fluid drained (Figures 4a and 4b).



**Figure 4a: Cyst wall opened. Figure 4b: Content of the cyst.**

A wide excision of the cyst wall was done resulting in a wide opening of the cystic cavity. Haemostasis was secured by over running suture with 3/0 vicryl around the edges of the remnant of the cyst wall. Biochemical analysis of the serous fluid (Figure 4b), showed Na – 143mmol/l, K – 3.9mmol/l, Cl – 109mmol/l, HCO<sub>3</sub> – 10mmol, urea – 0mmol/l and total protein 19g/l. The histology of the sac (Figure 5) showed columnar epithelium resembling biliary duct epithelium and re-

ported as simple hepatic cyst. The postoperative period was uneventful, oral feeding commenced on the 2<sup>nd</sup> day post operation; sutures were removed on the 7<sup>th</sup> day after surgery and patient discharged for outpatient review after 10 days.

Postoperative visits in the outpatient on the 4<sup>th</sup>, 8<sup>th</sup> and 12<sup>th</sup> weeks revealed no recurrence of cyst or ascites clinically or by ultrasonography.

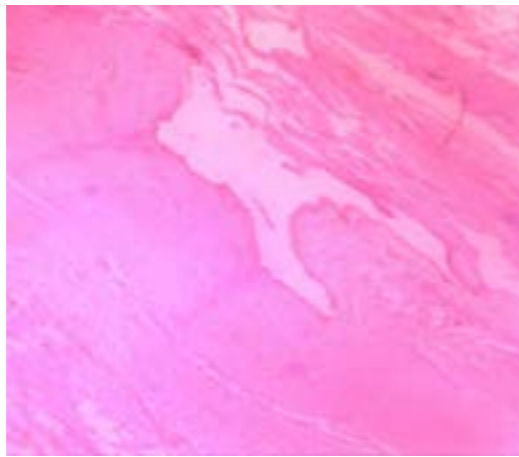


Figure 5: Photomicrograph of cyst wall  
H&E X 40.

### Discussion

The precise frequency of hepatic cysts is not known because most do not cause symptoms but estimated to occur in 5% of the population. No more than 10%-15% of these patients have symptoms that bring the cyst to clinical attention<sup>2</sup>. Presented is a 58-year-old female with a simple hepatic cyst that had clinical attention because of the enormous size. Ozbalci et al reported the prevalence of hepatic cyst as 0.1-0.5% based on autopsy studies and 2.5% based on ultrasonography<sup>3</sup>.

Simple cysts are more prevalent in women. The female:male (F: M) ratio is approximately 1.5:1 among those with asymptomatic simple cysts while it is 9:1 in those with symptomatic or complicated simple cyst. In another report, Cowles and Mulholland reported a F: M ratio of 3:1 for asymptomatic patients and when symptomatic a F: M ratio of 10:1<sup>7</sup>. Huge cysts are found almost exclusively in women over 50 years<sup>8</sup>, in keeping with our report.

Simple non-parasitic hepatic cysts are congenital and are supposedly triggered by chromosome 16. They arise as an aberration of bile duct development in utero and lined by cuboidal epithelium<sup>7</sup>. The development has a possible aetiological connection to the presence of oestrogens due to their increase among women especially between 40-60 year of age<sup>3,9</sup>, our patient a female was within this age group.

The hepatic cyst contained about 4.6 litres of serous fluid, Figure 4b. Simple hepatic cysts are cystic forma-

tions containing clear fluid that do not communicate with the intrahepatic biliary tree. The size ranges from a few millimetres to massive lesions occupying large volumes of the upper abdomen, the largest reported cyst contained 17 litres of fluid<sup>10</sup>. We report this case, as we did not find any report in our region with simple cyst as large as this and in addition, diagnosis was intraoperative in a resource-limited setting. The cyst is lined by uniform cuboidal or columnar epithelium resembling bile duct epithelium, Figure 5, and perhaps resulted from progressive dilatation of biliary microhamartomas that failed to develop normal connection with the biliary tree<sup>1</sup>. The contained fluid mimics plasma as depicted by the analysis of the aspirate of our patient and is continually secreted by the epithelium lining the cyst which may explain why needle aspirations are not curative<sup>11</sup>.

The location of the cyst and its size determine the symptoms. The index patient presented with abdominal mass with pain localised over the mass and easy satiety due to compression effect of the exophytic mass (Figure 2), arising from liver segment IV (anterior position). Generally, the hepatic cyst causes no symptoms and may be found incidentally at laparotomy or with abdominal imaging. However, large cysts may present as abdominal lump, palpable mass, right upper quadrant pain (from stretching of hepatic capsule). Compression of adjacent structures may result in the following clinical features: compression of the inferior vena cava resulting in lower extremity oedema, portal vein resulting in portal hypertension, and biliary tree resulting in

jaundice<sup>3,12</sup>. Our patient was spared these complications due to the location of the exophytic cyst in segment IV which facilitated wide excision of the cyst. Complications of the cyst may also result in acute abdomen from rupture, torsion and the cyst may become infected<sup>2,3,12</sup>.

Radiologic imaging techniques are useful in the detection and characterisation of hepatic lesions<sup>3,13</sup>. However, the ultrasonography report of the index patient was a hypodense cystic mass that filled most of the abdomen probably omental or mesenteric cyst, Figure 1, the liver was reported as normal and did not detail segments. Diagnosis of simple hepatic cyst was made at surgery. Sonography is known to be operator dependent. However, the cyst filled the upper abdomen at surgery and the liver segments V, VI, VII, and VIII at surgery appeared normal in keeping with the sonography and the liver segments II and III not detected as they were thinned out. Our patient did not have computerised tomography (CT) or magnetic resonance imaging (MRI) preoperative, as these were not available in our facility. Characterisation of liver pathology is better with CT and MRI. However, the role of USS in follow up of patients should be emphasized in order to detect ascites and recurrent cyst.

In recent years, many conventional open surgical procedures have been replaced by minimally invasive surgery<sup>3</sup>. Non-surgical methods, simple percutaneous aspiration alone is not adequate because of associated risk of infection and recurrence is invariable<sup>6</sup>. Follow up results were better with the use of percutaneous aspiration especially with sclerosis. Marcho Perez et al reported successful treatment with aspiration and injection of phenol alcohol<sup>14</sup>. This procedure may lead to irreversible sclerosing cholangitis in the presence of undetected communication with the biliary tree<sup>15</sup>. Symptomatic nonparasitic cysts, even cysts of the liver (15-25cm) have been treated by laparoscopic management<sup>3</sup>.

A definitive role for open surgery technique in selected patients is indicated especially in giant cysts that had taken up most of the abdomen, and displaced other organs. This is to prevent injury to adjacent organs when obtaining access to the abdomen during laparoscopy, more so in a facility without CT and MRI<sup>16</sup>. Our patient had open fenestration. Gall et al and Tocchi et al reported that laparoscopic approach did not offer better results compared with immediate and long-term results

of open deroofting<sup>13,15</sup>. However, postoperative morbidity associated with laparotomy and lengths of postoperative hospital stay have been reported as limitations of open surgery. Laparoscopic management has treated symptomatic nonparasitic cysts, even cysts of the liver (15-25cm)<sup>3</sup>.

The prognosis in our patient is expected to be good in view of the segment of the liver involved as this facilitated wide excision and the frequency of recurrence in this patient is expected to be low because of the same reason when compared with cyst in the difficult posterior location.

Intra-abdominal masses present diagnostic and therapeutic challenges especially in areas with limited radiographic imaging facilities. Giant simple hepatic cyst should be considered in the differential diagnosis of intra-abdominal masses.

### References

1. Ismaili KA, Mousa GI, El Khadrawy OH, Mohamed HA. Symptomatic non-parasitic benign hepatic cyst: Evaluation of management by deroofting in ten consecutive cases. *Ann Paed Surg* 2010; 6(2): 83-89.
2. Jackson HH, Mulvihill SJ. Hepatic cysts available at <http://emedicine.medscape.com/article/190818-overview>. Updated March 11 2010.
3. Ozbalci GS, Taurikulu Y, Erel S, Kismet K, Akkus MA. Giant simple hepatic cyst (A case report) and Review of Literature. *Eur J Surg Sci* 2010; 1(2): 53-57.
4. Yawai H, Tada N. A simple hepatic cyst with elevated serum and cyst fluid CA19-9 levels: a case report. *J Med Case Report* 2008; 2: 329.
5. Mazza OM, Fernandez DL, Pekoli J, Pfaffen G, Sanchez CR, Molmenti EP, de Santibanes E. Management of non-parasitic hepatic cysts. *J Am Coll Surg* 2009; 209(6): 733-739.
6. Tucker ON, Smith J, Fenlon HM, McEntee GP. Giant solitary non-parasitic cyst of the liver. *Ir J Med Sci* 2005; 174(2): 60-62.
7. Cowles RA, Mulholland MW: Solitary hepatic cysts. *J Am Coll Surg* 2000; 191: 311-321.
8. Benhamon JP, Menu Y. Non-parasitic cystic disease of the liver and intrahepatic biliary tree. In *Surgery of the liver and biliary tract*, 2nd edition, Blumgart, LH(Ed), Churchill Livingstone Inc, New York 1994. p. 1197.

9. Reger A, Reddy KR, Berho M, Seeman D, Levi JU, Livingstone AS, Levi D, Ali U, Molina EG, Schiff ER: Large cystic lesions of the liver in adults: a 15- year old experience in a tertiary center. *J Am Coll Surg* 2001; 193: 36-45.
10. Burch JC, Jones HE. Large nonparasitic cyst of the liver simulating an ovarian cyst. *Am J Obstet Gynecol* 1952; 63: 441.
11. Katkhouda N, Mavor E. Laparoscopic management of benign liver disease. *Surg Clin North Am* 2000; 80: 1203-1211.
12. Heap M, Seeger A, Hass CS. Giant solitary hepatic cyst. *Liver Int* 2008; 28: 840.
13. Gall TM, Onisai GC, Madhavan K, Parks RW, Gardin OJ. Surgical management and long term followup of non-parasitic hepatic cysts. *HPB (Oxford)* 2009, 11: 234-241.
14. Macho Perez O, Gomez Pavon J, Nunex Gonzalez A, Narvaiza Grau L, Albeniz Aguiriana L. Giant simple hepatic cyst as dyspnea symptoms in a 93- year-old patient. *An Med Interna* 2007; 24: 135-137.
15. Tocchi A, Mazzoni G, Costa G, Cassini D, Bettelli E, Agostini N et al. Symptomatic nonparasitic hepatic cysts: options for and results of surgical management. *Arch Surg* 2002; 137: 154-158.
16. Mekeel KL, Moss AA, Reddy KS, Mulligan DC, Harold KL. Laparoscopic fenestration of giant hepatic cyst. *Surg Laparos Endos Percutan Tech* 2008; 18: 511-513.