



Psoroptic Mange in a Weaner Pig

AKANDE, F.A.; OYEWUSI, I.K.; IDOWU, A.O. and AJAKAIYE, M.A.A

College of Veterinary Medicine, Funaab. Abeokuta¹. Faculty of Veterinary Medicine, University of Ibadan, Nigeria².

*Corresponding author: Email: dayoakande2006@gmail.com. Tel No: +2348035008607

SUMMARY

Mange is a contagious skin disease affecting various groups of animals. Psoroptic mange is a severe skin condition of farm animals; it is highly contagious and is responsible for huge economic losses in many farm animals. Infestation with *Psoroptes* has been reported all over the world in various farm animals, but none has ever been reported in swine. A male weaner large white breed pig of age 3 months weighing 10kg was presented with skin lesions and areas of alopecia during a routine farm visit by the handlers. The alopecia was found around the thorax, abdomen and ear regions with severe pruritus, emaciation, wrinkling and thickening of the skin with heavy crust formation on abdomen and the ears, along with curling of the tongue with attending vocal loss noticed on close observations. A tentative diagnosis of mange was made with the following differential diagnosis: Allergic dermatitis, Bacterial dermatitis, Fly bite dermatitis, Hypovitaminosis. Further confirmatory diagnosis was done by collection of deep skin scrapping from which *Psoroptes* mites were demonstrated and a case of psoroptic mange diagnosed. To the best of our knowledge this is the first demonstration of Psoroptic mange in pigs. The affected animal was treated using Ivermectin (1%) and Long acting Oxytetracycline (20%). This case may be the first case in which psoroptic mange was reported in pigs with effective ivermectin control. More work should be done on the prevalence and possible molecular characterization of Psoroptic mites on pigs across the globe to ascertain if there are other strains that can affect pigs.

Key words: *Psoroptes* mite, Mange, Ivermectin, and Pigs

INTRODUCTION

Mange is a contagious skin disease, characterized by crusty, pruritic dermatitis

and hair/feather loss, and caused by a variety of parasitic mites burrowing in or living on the skin of domestic animals (cats and dogs),

livestock (sheep, pigs and cattle), and in wild animals (coyotes, cougars, and bears) (Pangui, 1994).

Psoroptic mange is one of the most severe skin conditions of farm animals. This highly contagious disease is responsible for huge economic losses in many farm animals. It is also of significant welfare concern (Corke and Broom, 2002). Only a few countries, e.g. New-Zealand, the U.S.A. and Canada, were able to successfully eradicate ovine psoroptic mange (Kirwood, 1986; George *et al.*, 1992; O'Brien *et al.*, 1994; Ugbomioko *et al.*, 2018).

Psoroptes spp. are astigmatid, obligatory ectoparasites that cause various forms of *Psoroptic* mange in mammalian hosts including sheep, cattle, goats, horses and rabbits. *Psoroptic* mange has never been recorded in pigs (to the best of our knowledge).

Psoroptid mites are obligate parasites of mammals. They dwell and feed on the surface of the host's skin. Fifty species in about 30 genera of psoroptid mites are known from at least 11 mammalian orders, with the greatest number on primates (Bochkov, 2010). Survival time for some of these mites off the host may be two weeks or more.

One of the primary distinguishing features of the genus is the presence of relatively long, jointed pretarsi (Bochkov, 2010). The generally oval-shaped body is dorsoventrally flattened, has a striated cuticle with scattered setae but no spines, and bears longer legs and more prominent mouthparts than those of sarcoptid mites (Bochkov, 2010). *Psoroptes* spp. is a typical non-burrowing mite, up to 0.75mm in length, oval and with

all the legs projecting beyond the body margin. Its most important recognition features are the pointed mouthparts, the rounded abdominal tubercles of the male and the three jointed pedicles bearing funnel-shaped suckers on the legs (Bochkov, 2010). *Psoroptes* spp. are usually oval with all legs projecting beyond the body margin. The anus is posteroventral. Males usually have a pair of terminal posterior lobes bearing diagnostic septae and a pair of ventral suckers used in mating. The first pair of epimeres is not fused medially.

When infested, clinical signs include alopecia, itchy skin of which the pig will scratch furiously to try to relieve the irritation to the skin and, due to the prolonged scratching, the pig will likely begin to develop noticeable bald patches. Painful skin lesions can develop due to excessive scratching.

Diagnosis of mange in domestic animals is based on clinical manifestations and the demonstration of mites or their developmental stages in host skin scrapings. It is typified by hair loss, crusty or scaly skin lesions, dermatitis, thickened skin, scurf, and pruritus. Deep skin scrapings from the edges of the lesion (until blood starts oozing) using scalpel blade are collected into a new clean sample bottle (Kettle, 1995).

Proper treatment and control measures can only be implemented when accurate diagnosis is made. This is not always easy at certain stages of the disease, such as during incubation, at recovery when the disease has been suppressed while sometimes individual pigs are entirely refractive to the disease. This may be a genetic resistance worth

investigating. Important chemical agents used in management of mange are organo-phosphorus compounds, such as Propetamphos and diazinon, and pyrethroids, such as flumethrin and high cis-cypermethrin. More recently, injectable formulations of macrocyclic lactones, such as ivermectin, doramectin and moxidectin, were also approved as treatments and are now widely used (Plant and Lewis 2011). Although infestation with this parasite has been reported all over the world in sheep

and other farm animals (Falconi *et al.*, 2002), this is, to the best of our knowledge the first report of *Psoroptes* spp. mites in pigs.

On 22nd of May 2018, during an ambulatory service at the DUFARMS, Federal University of Agriculture, Abeokuta, (FUNAAB) a male weaner pig of age 3months weighing 10kg and of the large white breed was presented with skin lesions and area of alopecia on the skin.

The following were the clinical observations on presentation:

Parameters	Value	Normal range	Interpretation
Heart rate	76 bpm	60-120 bpm	Normal
Pulse rate	88 bpm	70-100 bpm	Normal
Respiratory rate	24 bpm	15-30 bpm	Normal
Temperature	37.6°c	37.2°c-39.2°c	Normal

The piglet was observed to have alopecia around the thorax, abdomen, and ear regions (Plate I)

There was severe pruritus, emaciation and the skin was wrinkled and thickened with

heavy crust formation on abdomen and the ears of the pig (Plates II & IV). On closer examination, it was observed that the pig’s tongue was curled, with loss of vocalization (Plate III).

The following are plates of some of the presenting signs observed on physical examination:

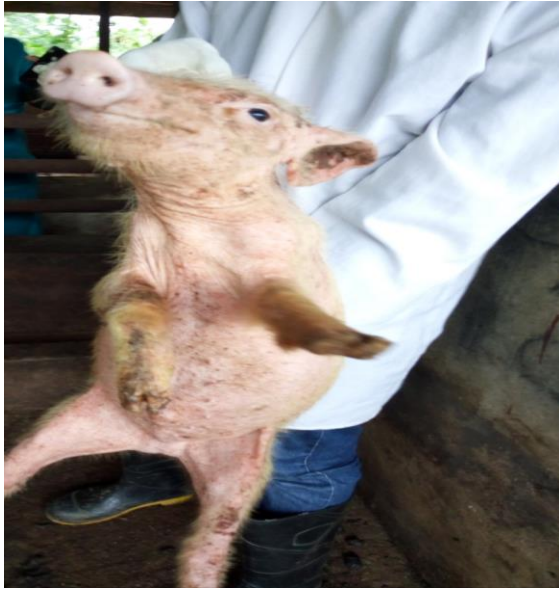

Plate 1: Showing area of alopecia at the ear and abdomen.

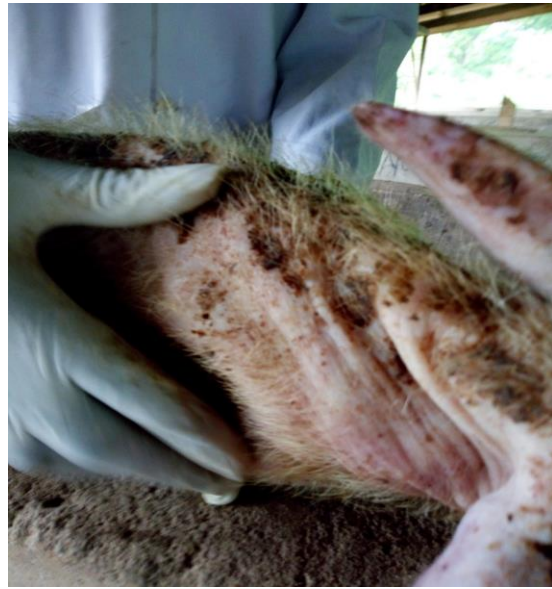

Plate 2: Showing wrinkling of the skin

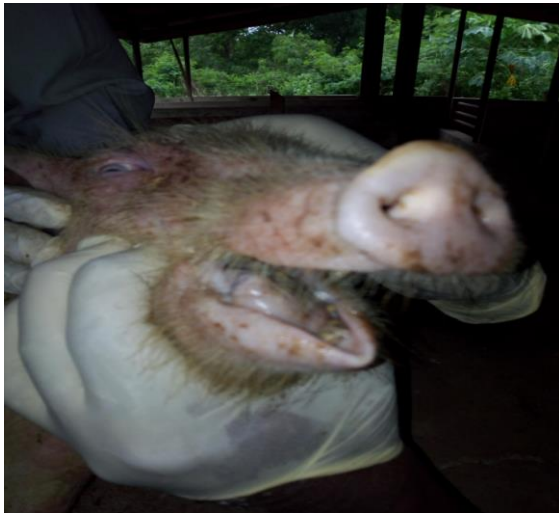

Plate 3: Showing curling of the tongue. thorax

DIAGNOSIS

A tentative diagnosis of mange was made with the following differentials: Allergic dermatitis, Bacterial dermatitis, Fly bite dermatitis, Hypovitaminosis. To further confirm the diagnosis, a deep scraping of the skin was done (until capillary blood was oozing out). The scrapings were collected

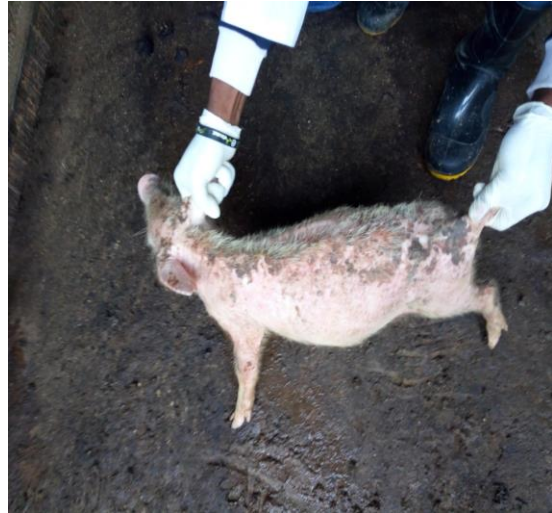

Plate 4: Showing area of thickening around the

into a universal tube and sent to the Parasitology Laboratory, Department of Veterinary Microbiology and Parasitology of the College of Veterinary Medicine, Federal University of Agriculture, Abeokuta for a thorough laboratory analysis. The skin scrapping was digested using 10% Potassium hydroxide (10% KOH) after digestion the mixture was examined under

the microscope to check for the presence of mite. Mites that have oval shape body with the legs protruding out of the body margin were seen under the Microscope. The legs are long and the pretarsi have long, three

segmented pedicels (Plate V). The haematological results of the pig is as presented in Table 1.

Table 1: Hematological results of the Psoroptes infested pig

Parameters	Value	Normal value	Remarks
Packed Cell Volume	32%	32-50%	Normal
Neutrophil	72%	28-50%	Neutrophilia
Lymphocyte	23%	40-60%	Lymphopenia
Eosinophil	2%	0-10%	Normal
Monocyte	3%	2-10%	Normal
Basophil	0%	0-2%	Normal

Confirmatory Diagnosis: with the demonstration of *Psoroptes* mite under the microscope a confirmatory diagnosis of Psoroptic mange (+) was made. The infestation was a mild one but considering the ability of the mite to cut through skin of affected host, the infestation could be serious in the affected animal more so when its not a known host of the mite and the hair available on the skin of pig is very scanty.

Treatment for the pig: The clinician gave the following as Ivermectin (300mcg/kg) subcutaneously, as a starter dose, this was repeated after 7days, making a two-dose treatment regime. Ivermectin injection (1%) – was given to the pigs and other members of the litter first because of its proven efficacy against Psoroptic mange, an evaluation of which has been carried out at

different laboratory (Marimuthu *et al.*, 2015). The results have shown it to have full therapeutic and prophylactic efficacy against Psoroptic mange. Although a single treatment will ensure that the herd is disease free and it remain so if all pigs introduced to the herds are isolated and treated, if given to the sow before farrowing, then the piglets will have a scab and worm free start; but the ivermectin was given twice at 7 days apart for all the members of the group in this study to ensure permanent clearance of the mange and a worm free start off for the litter group.

Oxytetracycline (20mg/kg) Long acting was also given to the pig intramuscularly. Oxytetracycline was administered because of the neutrophilia seen which is an indication of the possibility of a secondary

bacterial infection superimpose with the mange. The oxytetracycline was repeated 48 hours after it was initially given to the animal. The Oxytetracycline being a long

acting drug will also help in preventing further bacteria invasion of the exposed skin where the serum are oozing out from.

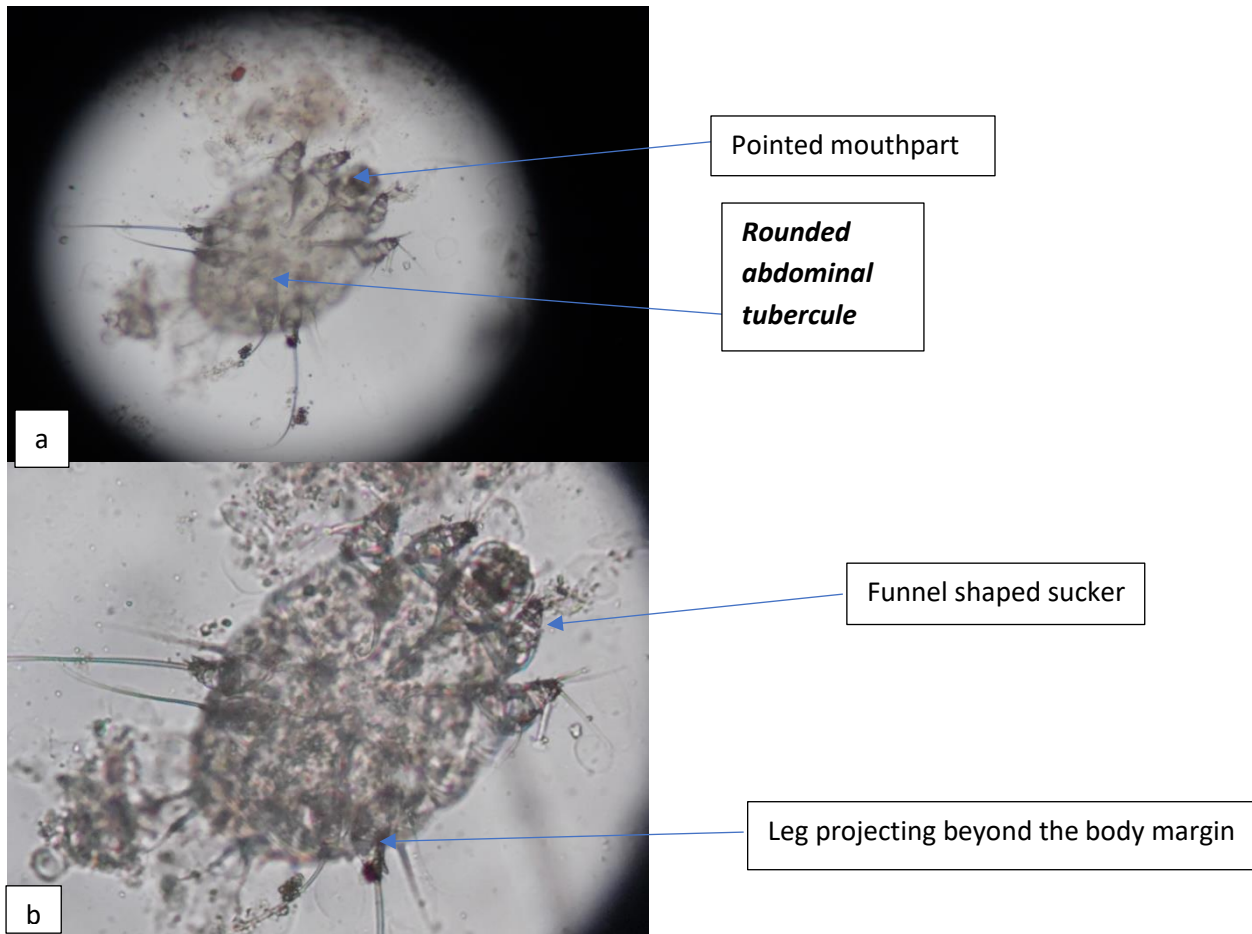


Plate V a Psoroptes mite(X100) and Plate V b Psoroptes mite(X400)

Plate Va and b: *Psoroptes* spp. mite found in skin lesions of the weaner pig (pointed mouth part and legs projecting beyond the body margin; suckers shaped like a funnel and rounded abdominal tubercules)

Psoroptes spp. mites feed superficially on the lipid emulsion of lymph, skin cells, secretions and bacteria on the surface of the host skin (Grice et al., 2008). The presence of actively feeding mites lead to inflammation and the exudation of lymph, which then coagulates to form crusts that may be excoriated leading to self-trauma

(Soulsby, 1982). The disease is highly infectious, and is transmitted via fenceposts and other structures that livestock use when scratching themselves (Mullen and O'Connor 2009) thus, the possibility of this infestation could be nearness to sheep paddock or where sheep do graze as is the case in DUFARMS where sheep are grazed

round the piggery in a semi-intensive method of rearing. Antigenic materials in the mite's faeces are thought to be the cause of a hypersensitivity reaction in the host, which leading to clinical manifestations *Psoroptic* mange according to (Sinclair and Kirkwood, 1983; Mathieson and Lehane, 1996).

The tentative diagnosis of mange was dependent on the clinical signs noticed on the weaner pig which were itching, alopecia, wrinkling of the skin etc. The curling of the tongue (probably a congenital defect or anatomical modification) may have caused the loss of vocalization. which the weaner pig was trying to forcefully attempt. The itching was caused by activity of mites in the skin lesions, resulting in intense irritation, making the weaner pig rub and damage its skin against the wall and leading to alopecia. The mites can also get into the hair follicles and sebaceous glands and build nodules that can become infected with secondary bacteria. The affected weaner pig was isolated from the others in to prevent contamination because *Psoroptic* mange is transmissible through direct contact (Mullen and O'Connor 2009).

CONCLUSION

Psoroptes spp. mite infestation has been reported in sheep, goats, cattle, rabbits and horse but has never been reported in pigs. This case may be the first case in which *psoroptic* mange is reported in pigs in Nigeria. There is need for further work to be done first on the prevalence of *Psoroptes* mite in pig population in Nigeria and further on the molecular Characterization of mites

of pigs to know the available species and possible characterization.

REFERENCES

- BLAKE, B.H., BAY, D.E., MEOLA, S.M. AND PRICE, M.A. (1978). Morphology of the mouthparts of the sheep scab mite, *psoroptes ovis*. *Annals of the Entomo Soc of Am.*, **71**:289-294.
- BOCHKOV A.V. (2010). A review of mammal-associated *Psoroptidia* (Acariformes: Astigmata). *Acarina.*, **18**: 99–260.
- BOCHKOV A.V. and MIRONOV S.V. (2011). Phylogeny and systematics of mammal-associated *psorptidian* mites (Acariformes: Astigmata: *Psoroptidia*) derived from external morphology. *Invert. Syst.*, **25**: 22–59.
- CORKE, M.J. and BROOM, D.M. (2002). The behaviour of sheep with sheep scab *psoroptes ovis* infestation. *Vet. Parasitol.*, **83**: 291–300.
- GARY MULLEN and BARRY M. O'Connor (2009). "Mites (Acari)". In Gary Mullen & Lance Durden (eds.). *Medical and Veterinary Entomology* (2nd ed.). Academic Press. pp. 423–482. ISBN 978-0-12-372500-4.
- GEORGE, J. B. D., OTOBO, S., OGUNLEYE, J., & ADEDIMINIYI, B. (1992). Louse and mite infestation in domestic animals in northern Nigeria. *Tropical animal health and production*, **24**(2), 121-124.

- GRICE, E. A., KONG, H. H., RENAUD, G., YOUNG, A. C., PROGRAM, N. C. S. and BOUFFARD, G. G. (2008). A diversity profile of the skin microbiota. *Gen Res.*, **18**: 1043-1050.
- KETTLE, D.S. (1995). Medical and Veterinary Entomology, Second Edition. CAB International, Wallingford, UK.
- KIRWOOD, A.C. (1986). History, biology and control of sheep scab. *Parasitology Today* 2, 302–307.
- KRANTZ, G.W. and WALTER D.E. (2009). A Manual of Acarology, Third Edition. *Texas Tech University Press*, Lubbock, Texas, USA.
- MARIMUTHU, M., ABDULLAH, F. F. J., MOHAMMED, K., ADAMU, L., TIJJANI, A., ABBA, Y., & HARON, A. W. (2015). Comparative treatment approach for Sarcoptes and Psoroptes mite infestation in a Boer cross. *Journal of Advanced Veterinary and Animal Research*, **2(1)**, 84-88.
- MATHIESON, B.R.F. and LEHANE, M.J. (1996). Isolation of Gram-negative bacterium *Serratia marcescens*, from the sheep scab mite, *Psoroptes ovis*. *Vet. Rec.*, **138**:210-211.
- O'BRIEN, D.J., GRAY, J. and O'REILLY, P.F. (1993). Control of sheep scab by subcutaneous injection of ivermectin. *Vet. Jour.*, **46**: 99–101.
- PANGUI, L.J. (1994). Gales des animaux domestiques et méthodes de lutte. *Rev. Sci. Tech. Off. Int. Epiz.*, **13**: 1227–1247.
- PLANT, W.J. and LEWIS, C. J. (2011). Treatment and control of ectoparasites in sheep. *Vet. Clin. North Am. Food Anim. Pract.*, **27**: 203–212.
- RAFFERTY, D.E. and GRAY, J.S. (1987). The feeding behavior of *Psoroptes* sp. mites on rabbits and sheep. *Journ of parasitol.*, **73**: 901-906.
- SALMON, D. E. and STILES, C.H. (1903) Scab in sheep. US Department of Agriculture. *Farm. Bul.*, **159**: 7-47.
- SINCLAIR, A.N. and KIRKWOOD, A.G. (1983). Feeding behavior of *Psoroptes ovis*. *Vet. rec.*, **15**: 41-65.
- SOULSBY, E.J.L. (1982). Helminths Arthropods and Protozoa of Domestic Animals. 7th edn. Balliere Tindall, London.
- UGBOMOIKO, UADE SAMUEL, SAMUEL ADEOLA OYEDEJI, OLAREWAJU ABDULKAREEM BABAMALE, and JORG HEUKELBACH (2018): Scabies in resource-poor communities in Nasarawa State, Nigeria: Epidemiology, clinical features and factors associated with infestation." *Tropical medicine and Infectious disease* 3, no. 2:59

