



The Pathology of Vaccination of Chickens with Varying Doses of Lentogenic LaSota Strain of Newcastle Disease Virus

Igwe, A.O.^{1*}, Sanda, M.E.², Nnsewo, U.E.I.¹, Okonkwo, C.J.², Onyebgula, O.³

¹Department of Veterinary Pathology, ²Department of Veterinary Medicine Department of Veterinary ³Public Health, Michael Okpara University of Agriculture, Umudike, Abia State, Nigeria.

*Corresponding author: Email: docoleji@yahoo.com, Tel. No. : +2348034509991

SUMMARY

Recently, it was demonstrated under laboratory conditions that increased doses of LaSota vaccine increased ND antibody response significantly in chickens. In this study, we have used the same model to investigate whether vaccination with increased doses of lentogenic LaSota strain of Newcastle disease virus are associated with pathological changes in chickens. Four-week-old broiler chickens (n=100) were randomly assigned into four groups of 25 each: ZD, each drenched with phosphate-buffered saline, SD, DD and TD broilers were each drenched with single, double and triple dose of LaSota vaccine, respectively. The chickens were observed for clinical signs and lesions. Serum samples were collected from the chickens in all the groups at weekly intervals post inoculation (PV) and assayed for haemagglutination inhibition (HI) antibodies. The vaccinated broilers showed no morbidity and mortality. Only the bursa of all the vaccinated groups appeared slightly reduced in size on day 10 PV. The histopathological changes were lymphoid hyperplasia and formation of germinal centres in the spleen and caecal tonsils from days 3 to 6 PV and mild depletion of bursal lymphocytes on day 10 PV. Generally, the integrity of the lymphoid organs was intact. Groups DD and TD antibody titres were significantly ($P < 0.05$) higher than that of the SD on day 21 PV. This suggests that increased doses of LaSota vaccine does not cause pathologic impairment and may be considered in improving the performance of the vaccine in the control of velogenic ND.

Key words: Newcastle disease, LaSota vaccine, pathology, broiler chickens

INTRODUCTION

Newcastle disease (ND), caused by virulent strains of avian orthoavulavirus-1 (formerly designated as Avian avulavirus-1, commonly

known as avian paramyxovirus-1, or Newcastle disease virus, NDV, used in this paper). The virus was recently classified to the genus *Orthoavulavirus*, subfamily *Avulavirinae*, family

Paramyxoviridae and order *Mononegavirales* (Amarasinghe *et al.*, 2019). ND is one of the most important poultry diseases around the globe, and often the cause of severe economic losses from morbidity, mortality, reduction in growth and egg production, and condemnation of carcasses in the poultry industry (Alexander *et al.*, 2012; Amarasinghe *et al.*, 2019). According to the World Organisation for Animal Health (OIE), ND is defined as an infection of birds by vNDV that are characterized by an intracerebral pathogenicity index (ICPI) in day-old chickens of 0.7 or greater; or demonstration of multiple basic amino acids (either directly or by deduction) at the C-terminus of the F2 protein (at least three arginine or lysine residues between positions 113 and 116) and phenylalanine at the N-terminus (position 117) of the F1 protein (OIE, 2012). Because of the highly contagious nature of NDV causing serious economic consequences to the poultry industry, as well as impacting the international trade of poultry and poultry products (and trade restrictions), the disease is reportable to the World Organization for Animal Health (OIE, 2012).

Although there are different strains of the virus, pathotypes of ND defined by clinical signs in chickens after experimental inoculations were created to describe the virulence of ND strains and are classified into velogenic, mesogenic, lentogenic and asymptomatic (Alexander and Senne, 2008; Miller and Koch, 2013). These have varying virulence in the type and severity of the disease produced. Although all NDV strains belong to a single serotype (serotype 1), there is large genetic variability among NDV isolates. Strains are divided into 2 classes (I and II) based on molecular characterization, with class I composed of only 1 genotype (class I, genotype I) and with class II divided into 18 genotypes (class II, genotypes I–XVIII) (Diel *et al.*, 2012a; Snoeck *et al.*, 2013). While class I are mostly low pathogenic NDV strains (except for 1, APMV-1/chicken/Ireland48/90) (Alexander *et al.*, 1992), found mainly in waterfowl, class II

includes both virulent and avirulent strains (Miller *et al.*, 2010; Afonso and Miller, 2013). The virulent ND is enzootic in Africa, a recurring concern to poultry industries (Bello *et al.*, 2018), and causes disease in birds which manifests in respiratory and gastrointestinal and or nervous system symptoms (Miller and Koch, 2013; Igwe *et al.*, 2018a). The lesions of ND have been reported to be dependent on the strain and dose or amount of virus received (Miller and Koch, 2013). The velogenic pathotype causes systemic lesions, with necrosis and lymphocytic depletion (Igwe *et al.*, 2018b). The mesogenic pathotype includes the moderately pathogenic which are also used in producing vaccines such as Komarov and Mukteswar, depending on the disease situation and national requirements (OIE, 2012). They cause mainly the respiratory form of ND. The lentogenic and asymptomatic pathotypes referred to as low virulence are used as live vaccines (Miller and Koch, 2013).

The primary strategy available to the poultry industry to control virulent NDV, the causative agent of ND, along with good biosecurity practises, is vaccination. Vaccines and vaccine programs have proven to be very beneficial for controlling diseases in domestic animals, as their widespread use has dramatically reduced the incidence of severe and fatal diseases (Roth, 1999). Although many high-quality vaccines are commercially available for the control ND, the commonly used ND vaccines worldwide are live vaccine viruses of low virulence (lentogenic) that belong to genotype II (B1 and LaSota vaccines) (Kapczynski *et al.*, 2013). LaSota vaccine has been used for years to provide protection from disease caused by virulent forms of the virus, referred to as mesogenic and velogenic NDV, and always used in countries where virulent NDV is endemic (Diel *et al.*, 2012b; Dimitrov *et al.*, 2017). Despite extensive vaccination with prophylactic vaccines and vaccination practises, outbreaks have been reported in vaccinated chickens in many parts of the world (Dimitrov *et al.*, 2017; Bello *et al.*, 2018), indicating that there

is room for improvement in biosecurity measures and the current vaccine programs. However, creating an effective vaccine strategy poses many challenges.

There is considerable controversy regarding the issue of vaccine failure on NDV control. It has been suggested that a better understanding of genetic variability of all strains of NDV and characteristics, is crucial for developing new vaccines and vaccination strategies (Dimitrov *et al.*, 2017). Some suggest that vaccine failure is mainly caused by poor flock immunity due to inadequate vaccination and strict biosecurity practices and not antigenic variation between the vaccine strains and circulating field strains (Dortmans *et al.*, 2012; Miller and Koch, 2013; Dimitrov *et al.*, 2017). However, others have suggested that the use of higher doses of classical vaccines, which should induce higher antibody levels, would be enough to prevent ND caused by vNDV from genotypes more distant from vaccine strains (Cornax *et al.*, 2012). Cornax *et al.* (2012) and Igwe *et al.* (2019) reported that to double the normal dose of LaSota vaccine will increase the level of antibody response in broilers; however, this cannot be easily recommended without finding out the likely adverse effect on the organs of chickens. This is because, a vaccine or vaccination protocol that lacks adverse reactions is very much needed by the poultry industry. The present study investigated the pathological changes from previously published studies (Igwe *et al.*, 2019) in the organs of experimental commercial broiler chickens inoculated with varying doses of lentogenic strain (LaSota) of NDV.

MATERIALS AND METHODS

Broiler Chickens

One hundred commercial Cobb broiler chicks (*Gallus gallus domesticus*) were purchased at one-day old from a reputable local commercial hatchery and randomly assigned into four groups of 25 broilers each. The parent stocks of the

broilers were vaccinated against ND while the broilers were not vaccinated against any disease. They were kept in high security isolation in the departmental facility. Brooding was on deep litter. Feed and water were supplied *ad libitum*. General care of the birds was provided in accordance with the Institutional Animal Care and Use Committee, as outlined in the Guide for the Care and Use of Agricultural Animals in Research and Teaching (https://www.aaalac.org/about/Ag_Guide_3rd_ed.pdf).

LaSota Vaccine

Live, freeze-dried lentogenic NDV (strain LaSota) vaccine manufactured and obtained from the National Veterinary Research Institute, Vom, Plateau State, Nigeria was used. It had a medium embryo infective dose (EID₅₀) of 10^{6.2} per ml.

Vaccination

At the age of four weeks, the randomly assigned four groups were named ZD (Zero dose) group, SD (Single dose) group, DD (Double dose) group and TD (Triple dose) group. Each broiler in the ZD group received 0.5 ml of the phosphate-buffered saline (PBS) used in dissolving the vaccine orally as placebo. The SD broilers each was drenched with single dose of the vaccine in 0.5 ml. Each of the broilers in groups DD and TD received double and triple doses of the vaccine in 0.5 ml by drenching, respectively.

Clinical and Pathology Examinations

The chickens were observed twice daily for clinical signs from 0-day post-vaccination (PV) to 21 days PV. Three chickens in each group were randomly selected and sacrificed by cervical dislocation. The sacrificed chickens were necropsied and examined for gross lesions on days 3, 6 and 10 PV. Samples of the bursa of Fabricius, spleen, thymus, lungs, kidney, liver and caecal tonsils, were fixed in 10% formal saline for minimum of 24 hours. The fixed tissues were trimmed and routinely processed before being embedded in paraffin wax. Sections (5 µm) were stained with haematoxylin and eosin (H&E) staining using the method of Suvarna *et*

al. (2018). The slides were studied under the light microscope.

Serology

Blood samples (One ml of blood) were collected from 10 chickens in each group on days 0, 7, 14 and 21 PV. Each time different chickens were randomly selected. Sera were harvested and the humoral immune response was measured by the haemagglutination inhibition (HI) test using a suspension of LaSota vaccine in PBS as antigen at four haemagglutinating units according to the method of OIE (2012). Titres were calculated as the reciprocal of the last HI-positive serum dilution, and samples with HI titres of 3 (\log_2) and below were considered negative.

Statistical Analysis

The HI data were analysed using the one-way analysis of variance (ANOVA). Variant means were separated post hoc using the least significant difference method (Okafor, 1992). Statistical significance was defined as 5% level of significance ($P < 0.05$) for all tests.

RESULTS

Clinical Signs

No clinical sign was observed in all the groups of chickens throughout the experimental period (days 0 to 21 PV).

Pathology

Gross Pathology

There were no abnormal gross findings in the organs of the chickens in all the vaccinated groups on days 3 and 6 PV (Plate 1 (A, B, C)), and throughout the experimental period for the spleen, thymus, caecal tonsils, kidney, liver and lungs. But there was only mild reduction in size of the bursa of Fabricius in all the vaccinated groups on day 10 PV (Plate 2 (A, B, C)). There were no abnormal gross findings in the control birds.

Histopathology

Histopathological sections of the bursa of Fabricius, spleen, thymus, lungs, kidney, liver

and caecal tonsils showed normal architecture throughout the experimental period in all the groups. Histopathological sections of the bursa of Fabricius showed mild inflammatory cellular infiltration with normal lymphocytic population on day 3 PV in all the vaccinated groups (Plate 3). Lymphoid hyperplasia and formation of germinal centres were common in the spleen and caecal tonsils from days 3 to 6 PV (Plates 4 and 5) and increased markedly on day 10 PV in all the vaccinated groups. Mild depletion of lymphocytes which did not alter the normal architecture of the bursa was observed on day 10 PV in the SD, DD and TD groups. There were no histopathological findings in the control birds.

Serology

The pre-vaccination mean HI antibody titres to NDV of all the broilers was negative at 4-weeks old (day 0 post-vaccination). During the following weeks after vaccination, the HI titers increased progressively, reaching a moderately high level by day 14 post-vaccination. However, the HI antibody titres were significantly ($P < 0.05$) higher in the DD and TD groups than the SD on day 21 PV (Table 1). Throughout the experiment, titres of the control group, ZD, remained negative.

DISCUSSION

The continuous threat of ND outbreaks in commercial poultry flocks in Nigeria necessitates vaccines and vaccination practises which will induce better flock immunity with minimal and negligible tissue damage along with strict biosecurity. Good biosecurity practise is a critical component of preventing the virus away from the flock before they achieve a protective level of immunity. Assessment of the protection attained in earlier study was based on antibody response only, as it was found that the development of satisfactory antibody levels or that increasing the dose of the LaSota vaccine will increase the level of antibody response in




Plate 1: (A, B, C). Bursa of Fabricius, spleen and thymus of broilers on day 3 post-vaccination showing no difference in sizes. Plate 2: (A, B, C). Bursa of Fabricius, spleen and thymus of broilers on day10 PV. Note: only the bursa of Fabricius in all the vaccinated groups showed mild reduction in size than the ZD group.

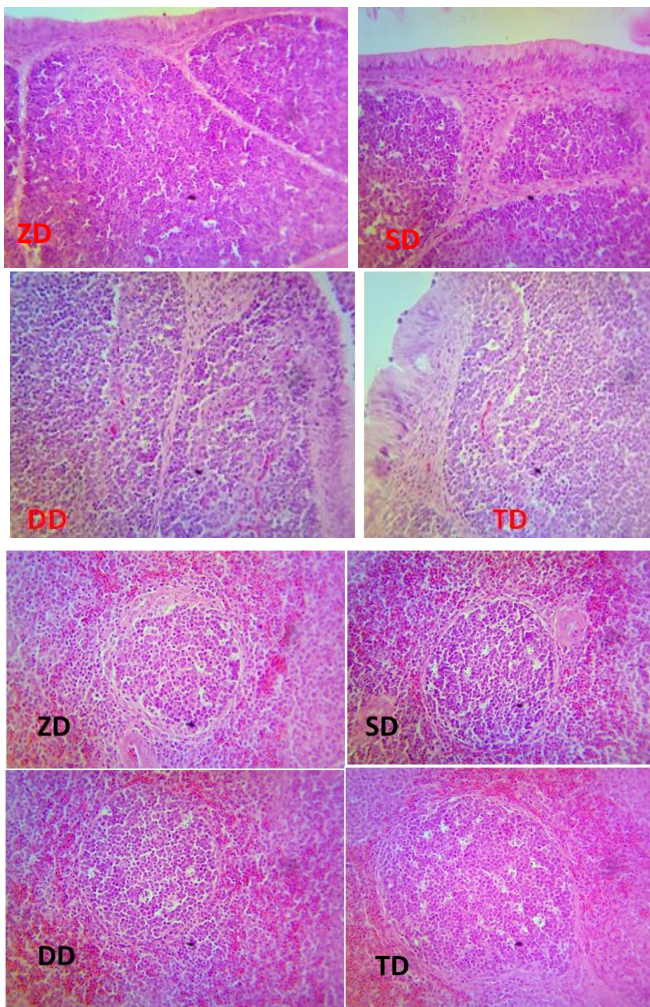


PLATE 2: Bursa of Fabricius of all groups showing a normal architecture, normal lymphocytic population, with mild inflammatory cells in vaccinated groups compared with ZD group on day 3 PV. H&E, X400

Plate 3: Spleen showing nodular hyperplasia of lymphoid cells and formation of germinal centres without evidence of necrosis in vaccinated groups compared with ZD group on day 3 PV. H&E, X400.

broilers significantly (Igwe *et al.*, 2019). In the present study, we aimed to investigate if there

would be pathological changes on the organs of commercial chickens experimentally vaccinated with varying doses of live lentogenic strain (LaSota) of NDV.

Clinically, our results showed that all the chickens vaccinated with higher doses of LaSota exhibited no signs of disease. This finding is consistent with previous observations using lentogenic strains (Ulster, B1, QV4 and LaSota) (Gough and Allan 1976; Brown *et al.*, 1999; Kapczynski and King, 2005; Cornax *et al.*, 2012; Igwe *et al.*, 2019). Our observation showed that the LaSota vaccine induced much better clinical

vaccination as the seed viruses for vaccine production (van Boven *et al.*, 2008).

The only gross finding in chickens in all the vaccinated groups with LaSota was moderate reduction in size of the bursa at day 10 PV. Results of various investigators with LaSota or other commercial vaccine strains using single dose, while consistent, do vary somewhat, particularly in the occurrence of organ vaccinal reactions. Winterfield *et al.* (1980) did not observe any gross lesions in chickens inoculated with LaSota via the eye drop. Hamid *et al.*

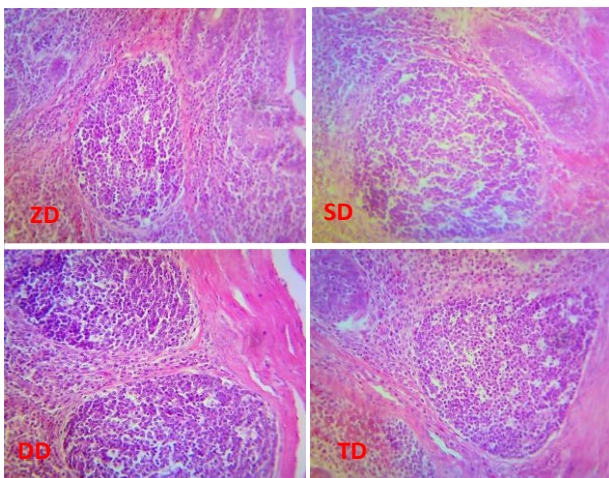


Plate 4: Caecal tonsils showing nodular hyperplasia of lymphoid cells without evidence of necrosis in vaccinated groups compared with ZD group on day 6 PV. H&E, X400.

(1990) observed only moderate enlargement of

TABLE 1: Newcastle disease haemagglutination inhibition antibody titres in the broilers ± standard error of the mean

Days post-vaccination	Zero dose group	Single dose group	Double dose group	Triple dose group
0	3.2 ± 0.33 ^a	3.6 ± 0.78 ^a	3.6 ± 0.78 ^a	3.2 ± 0.33 ^a
7	0 ± 0.00 ^a	137.6 ± 32.37 ^a	300.8 ± 123.22 ^a	275.2 ± 125.14 ^a
14	0 ± 0.00 ^a	435.2 ± 129.70 ^b	678.4 ± 101.06 ^b	537.6 ± 133.30 ^b
21	0 ± 0.00 ^a	665.6 ± 78.21 ^b	1536 ± 170.67 ^c	1433.6 ± 167.22 ^c

Note: ^{a, b, c} Different superscripts in a row indicate significant differences between the groups (P < 0.05)

protection from vaccine reactions regardless of the varying doses administered. The absence of clinical reactions to LaSota vaccination in this study is in agreement with the strategy to use less virulent strains that reduce disease rates after

the spleen and slight swelling of the bursa on day 4 after oro-nasal infection with the lentogenic V4 strain of NDV in seven-week-old commercial White Leghorn chickens. Brown *et al.*, 1999 reported only moderate reddening of the thymus

on day 5 post infection in chickens inoculated with lentogenic isolates (B1 and QV4) via the conjunctival sac. Other investigators have determined that poultry infected with lentogenic NDV are more susceptible to secondary respiratory infections that cause disease considering that viral replication and subsequent compromise of air sac epithelium could be a mechanism allowing for entry for secondary agents (Ficken *et al.*, 1987; Nakamura *et al.*, 1994). While it is not possible to explain all the differences, it is known that different breeds/strains of birds vary in their responses to vaccination (Abdul-Aziz and Arp, 1983; Seal *et al.*, 2000; Dalgaard *et al.*, 2010). In addition, genetic background of a host determines how the immune response to a given microorganism will evolve (Sharma, 2013). Grossly, our results supported and correlate with the absence of clinical signs and results of the HI tests and from previous findings suggesting that where the LaSota vaccine is used for either primary or secondary vaccination, even at increased doses, excellent organs and respiratory tract protection will be apparent and can minimize susceptibility to secondary respiratory infections that cause disease.

The histopathological findings of normal architecture throughout the experimental period in all the groups clearly show that the broiler chickens responded well to a primary inoculation of LaSota vaccine administered in varying doses. Mild inflammatory cellular infiltration of the bursa was seen on day 3 PV in all the vaccinated groups. The immune system of birds is functionally divided into an early responding, innate and a slow-reacting adaptive immune system, which are essential and cooperate for antimicrobial, primary and vaccination-induced immunity. Due to their ability to replicate in the host, live vaccines induce a variety of innate and adaptive immune responses (Schijns *et al.*, 2008). It has been suggested that innate immunity can play an important role against NDV infection (Rohollahzadeh *et al.*, 2018).

Studies also confirmed that innate defence system is necessary for vaccination-induced immunity (Schijns *et al.*, 2008). Innate immune cells include epithelial cell, macrophages, dendritic cells, various granulocytes and natural killer cells. They are able to respond within minutes, until adaptive responses (B and T cell mediated) become mobilized, and are also likely to play an important role in the early onset of immunity associated with live vaccines that not only prevent disease of the individual bird but also limit virus transmission (Jeurissen *et al.*, 2000; Schijns *et al.*, 2008). Our results indicated that mild local and systemic reactions to vaccines are to be expected as a natural consequence of stimulating the immune system (Hammer, 1974; Schijns *et al.*, 2008). Evidence of lymphoid hyperplasia was observed in the spleen and caecal tonsils of birds in all the vaccinated groups regardless of the doses administered, suggesting that LaSota vaccine is immunogenic and protective. Live NDV vaccines based on the LaSota strain have been studied for many years. Early trials suggested that such vaccines were immunogenic and protective (Westbury, 1981). This finding of the present study shows that increased doses of LaSota vaccine exerts a significant boosting effect and correlates with the HI titers of broiler chickens observed in earlier studies (Cornax *et al.*, 2012; Igwe *et al.*, 2019). It is also in agreement with the report of Hamid *et al.* (1990), who reported that the chief histological changes observed in the lymphoreticular system were the formation of new germinal centres with a peak on the third week after infection in spleen and the cortex and medulla of the bursa probably indicate the presence and processing of antigen. However, in the present study, lymphoid hyperplasia was observed in the spleen and caecal tonsils as we only relied on necropsies at days 3, 6 and 10 with daily clinical and weekly serological observations at the terminations of the study at 21 days PV. Mild depletion of lymphocytes which did not alter the normal architecture of the

bursa was observed on day 10 PV in the SD, DD and TD groups suggesting that mild lymphocytic depletion of the bursa may occur following vaccination of chickens with lentogenic NDV pathotypes. Vaccination for NDV is primarily by mass application of live-virus vaccines among commercial poultry. Although protection is measured by presence of antibodies to NDV, vaccinated B-cell depleted chickens are resistant to disease. Consequently, immune protection involves responses that are presently incompletely defined (Seal *et al.*, 2000). Interestingly, we found that increased doses of LaSota vaccine in chickens was associated with lymphoid hyperplasia and no decrease in HI titres in bursa mildly depleted vaccinated groups, compared with unvaccinated group. These results revealed that although antibody responses induced by live vaccines are the key modulators of protection, adaptive immune response is also an important mediator of protection against intracellular pathogens (Sharma, 2013).

CONCLUSION

In conclusion, increased doses of lentogenic LaSota strain of Newcastle disease virus inoculation in broilers caused moderate reduction in size of the bursa. Histopathological changes included lymphoid hyperplasia and formation of germinal centres in the spleen and caecal tonsils. Clinically our results suggest that increased doses of LaSota has met the goal of current vaccination procedures, which is, to induce protective immunity while producing a minimal antagonistic response in the bird. For the poultry producer, this decreases economic losses at harvest. The presented study supported and extended previous findings regarding the safety of increased doses of LaSota vaccine in chickens. This suggests that doubling the dose of LaSota vaccine does not cause pathologic impairment and may be considered in improving the performance of the vaccine in the control of velogenic ND.

REFERENCES

- ABDUL-AZIZ, T.A. and ARP, L.H. (1983): Progression of tracheal lesions in turkeys exposed by aerosol to LaSota strain of Newcastle disease virus. *Avian Diseases*, 27(4): 1131–1141.
- AFONSO, C.L. and MILLER, P.J. (2013): Newcastle disease: progress and gaps in the development of vaccines and diagnostic tools. In: *Vaccines and Diagnostics for Transboundary Animal Diseases*. J. Roth, J.A. Ritch and V. Morozov, Basel, Karger, Ames, IA: 95–106.
- ALEXANDER, D.J., CAMPBELL, G., MANVELL, R.J., COLLINS, M.S., PARSONS, G. and McNULTY, M.S. (1992): Characterisation of an antigenically unusual virus responsible for two outbreaks of Newcastle disease in the Republic of Ireland in 1990. *Veterinary Record*: 130(4): 65–68.
- ALEXANDER, D.J. and SENNE, D.A. (2008): Newcastle Disease and Other Avian Paramyxoviruses. In: *A Laboratory Manual for the Isolation, Identification and Characterization of Avian Pathogens*, 4th Ed. L. Dufour-Zavala, D.E. Swayne, J.R. Glisson, M.W. Jackwood, J.E. Pearson, W.M Reed and P.R. Woolcock, American Association of Avian Pathologists, Athens, GA: 135–141.
- ALEXANDER, D.J., ALDOUS, E.W. AND FULLER, C.M. (2012): The long view: a selective review of 40 years of Newcastle disease research. *Avian Pathology*, 41(4): 329–335.
- AMARASINGHE, G.K., AYLLÓN, M.A., BÀO, Y., BASLER, C.F., BAVARI, S., BLASDELL, K.R., BRIESE, T., BROWN, P.A., BUKREYEV, A., BALKEMA- BUSCHMANN, A., BUCHHOLZ, U.J., CHABI-JESUS, C.,

- CHANDRAN K., CHIAPPONI, C., CROZIER, I., de SWART, R.L., DIETZGEN, R.G., DOLNIK, O., DREXLER, J.F., DÜRRWALD, R., DUNDON, W.G., DUPREX, W.P., DYE, J.M., EASTON, A.J., FOOKS, A.R., FORMENTY, P.B.H., FOUCHIER, R.A.M., FREITAS-ASTÚA, J., GRIFFITHS, A., HEWSON, R., HORIE, M., HYNDMAN, T.H., JIANG, D., KITAJIMA, E.W., KOBINGER, G.P., KONDŌ, H., KURATH, G., KUZMIN, I.V., LAMB, R.A., LAVAZZA, A., LEE, B., LELLI, D., LEROY, E.M., LI, J., MAES, P., MARZANO, S.L., MORENO, A., MÜHLBERGER, E., NETESOV, S.V., NOWOTNY, N., NYLUND, A., ØKLAND, A.L., PALACIOS, G., PÁLYI, B., PAWĘSKA, J.T., PAYNE, S.L., PROSPERI, A., RAMOS-GONZÁLEZ, P.L., RIMA, B.K., ROTA, P., RUBBENSTROTH, D., SHĪ, M., SIMMONDS, P., SMITHER, S.J., SOZZI, E., SPANN, K., STENGLEIN, M.D., STONE, D.M., TAKADA, A., TESH, R.B., TOMONAGA, K., TORDO, N., TOWNER, J.S., van den HOOGEN, B., VASILAKIS, N., WAHL, V., WALKER, P.J., WANG, L.F., WHITFIELD, A.E., WILLIAMS, J.V., ZERBINI, F.M., ZHANG, T., ZHANG, Y.Z. and KUHN, J.H. (2019): Taxonomy of the order *Mononegavirales*: update 2019. *Archives of Virology*, 164(7): 1967–1980.
- BELLO, M.B., YUSOFF, K.M., IDERIS, A., HAIR-BEJO, M., PEETERS, B.P.H., JIBRIL, A.H., TAMBUNWAL, F.M. and OMAR, A.R. (2018): Genotype diversity of Newcastle disease virus in Nigeria: disease control challenges and future outlook. *Advances in Virology*, 15(1): 1–17.
- BROWN, C., KING, D.J., and SEAL, B.S. (1999): Pathogenesis of Newcastle disease in chickens experimentally infected with viruses of different virulence. *Veterinary Pathology*, 36(2): 125–132.
- CORNAX, I., MILLER, P.J. and AFONSO, C.L. (2012): Characterization of live LaSota vaccine strain-induced protection in chickens upon early challenge with a virulent Newcastle disease virus of heterologous genotype. *Avian Disease*, 56(3): 464–470.
- DALGAARD, T.S., NORUP, L.R., PEDERSEN, A.R., HANDBERG, K.J., JØRGENSEN, P.H. and JUUL-MADSEN, H.R. (2010): Flow cytometric assessment of chicken T cell-mediated immune responses after Newcastle disease virus vaccination and challenge. *Vaccine*, 28(28): 4506–4514.
- DIEL, D.G., da SILVA, L.H.A., LIU, H., WANG, Z., MILLER, P.J. and AFONSO, C.L. (2012a): Genetic diversity of avian paramyxovirus type 1: proposal for a unified nomenclature and classification system of Newcastle disease virus genotypes. *Infection, Genetics and Evolution*, 12(8): 1770–1779.
- DIEL, D.G., SUSTA, L., CARDENAS GARCIA, S., KILLIAN, M.L., BROWN, C.C., MILLER, P.J. and AFONSO, C.L. (2012b): Complete genome and clinicopathological characterization of a virulent Newcastle disease virus isolate from South America. *Journal of Clinical Microbiology*, 50(2): 378–387.
- DIMITROV, K.M., AFONSO, C.L., YU, Q. and MILLER, P.J. (2017): Newcastle disease vaccines—A solved problem or a continuous challenge? *Veterinary Microbiology*, 206(9): 126–136.

- DORTMANS, J.C., PEETERS, B.P. and KOCH, G. (2012): Newcastle disease virus outbreaks: Vaccine mismatch or inadequate application? *Veterinary Microbiology*, 160(1–2): 17–22.
- FICKEN, M.D., EDWARDS, J.F., LAY, J.C. and TVETER, D.E. (1987): Tracheal mucus transport rate and bacterial clearance in turkeys exposed by aerosol to La Sota strain of Newcastle disease virus. *Avian Diseases*, 31(2): 241–248.
- GOUGH, R.E. and ALLAN, W.H. (1976): Aerosol vaccination against Newcastle disease using the Ulster strain. *Avian Pathology*, 5(2): 81–95.
- HAMID, H., CAMPBELL, R.S.F. and LAMICHHANE, C. (1990): The pathology of infection of chickens with the lentogenic V4 strain of Newcastle disease virus, *Avian Pathology*, 19(4): 687–696.
- HAMMER, D.K. (1974): The immune system in chickens. *Avian Pathology*, 3(2): 65–78.
- IGWE, A.O., AFONSO, C.L., EZEMA, W.S., BROWN, C.C. and OKOYE, J.O.A. (2018a): Pathology and distribution of velogenic viscerotropic Newcastle disease virus in the reproductive system of vaccinated and unvaccinated laying hens (*Gallus gallus domesticus*) by immunohistochemical labelling. *Journal of Comparative Pathology*, 159(2): 36–48.
- IGWE, A.O., SHITTU, I. and Okoye, J.O.A. (2018b): Response of cyclophosphamide treated broiler chickens to challenge with velogenic Newcastle disease virus. *Journal of Applied Animal Research*, 46(1): 938–946.
- IGWE, A.O., NNSEWO, U.E., EZE, D.C., ABBA, Y. and OKOYE, J.O.A. (2019): Increased doses of La Sota vaccine increased Newcastle disease antibody response significantly in broiler chickens (*Gallus gallus domesticus*). *Journal of Applied Animal Research*, 47(1): 423–428.
- JEURISSEN, S.H.M., BOONSTRA-BLOM, A.G., AL-GARIB, S.O., HARTOG, L. and KOCH, G. (2000): Defence mechanisms against viral infection in poultry: A review. *Veterinary Quarterly*, 22(4): 204–208.
- KAPCZYNSKI, D.R. and KING, D.J. (2005): Protection of chickens against overt clinical disease and determination of viral shedding following vaccination with commercially available Newcastle disease virus vaccines upon challenge with highly virulent virus from the California 2002 exotic Newcastle disease outbreak. *Vaccine*, 23(26): 3424–3433.
- KAPCZYNSKI, D.R., AFONSO, C.L. and MILLER, P.J. (2013): Immune responses of poultry to Newcastle disease virus. *Developmental and Comparative Immunology*, 41(3): 447–453.
- MILLER, P.J., DECANINI, E.L. and AFONSO, C.L. (2010): Newcastle disease: Evolution of genotypes and the related diagnostic challenges. *Infection, Genetics and Evolution*, 10(1):26–35
- MILLER, P. J. and KOCH, G. (2013): Newcastle Disease, Other Avian Paramyxoviruses, And Avian Metapneumovirus Infections. *In: Diseases of Poultry*, 13th Ed. D.E. Swayne, J.R. Glisson, L.R. McDougald, L. K. Nolan, D. L. Suarez and V. Nair. John Wiley & Sons Inc.: New Jersey, USA: 87–138.
- NAKAMURA, K., UEDA, H., TANIMURA, T. and NOGUCHI, K. (1994): Effect of mixed live vaccine (Newcastle disease and infectious bronchitis) and *Mycoplasma gallisepticum* on the chicken respiratory tract and on

- Escherichia coli infection. *Journal of Comparative Pathology*, 111(1): 33–42.
- OFFICE INTERNATIONAL DES EPIZOOTICS (OIE). (2012): Manual of Diagnostic Tests and Vaccines for Terrestrial Animals. Newcastle disease. Retrieved from <https://www.oie.int/standard-setting/terrestrial-manual/access-online/>
- OKAFOR, L.C. (1992): Biometry – basic principles and approaches. Onitsha. Nigeria: Geelink. 141–172.
- ROHOLLAHZADEH, H., NILI, H., ASASI, K., MOKHAYERI, S. and ASL NAJJARI, A.H. (2018): Respiratory and GIT tract immune responses of broiler chickens following experimental infection with Newcastle disease's virus. *Comparative Clinical Pathology*, 27(5): 1241–1255.
- ROTH, J.A. (1999): Mechanistic bases for adverse vaccine reactions and vaccine failures. In: ADVANCES IN VETERINARY MEDICINE, Volume 41, Veterinary Vaccines and Diagnostics, W. Dodds, R.D. Schultz, Academic Press, San Diego, California, USA: 681–700.
- SCHIJNS, V.E.J.C., SHARMA, J. and TARPEY, I. (2008): Practical aspects of poultry vaccination. In: *Avian Immunology*, 1st Ed. F. Davison, B. Kaspers and K. A. Schat, Academic Press, San Diego, CA 92101-4495, USA: 373–393.
- SEAL, B.S., KING, D.J. and SELLERS, H.S. (2000): The avian response to Newcastle disease virus. *Developmental and Comparative Immunology*, 24(2-3): 257–268.
- SHARMA, J.M. (2013): Host factors for disease resistance. In: *Diseases of Poultry*, 13th Ed. D.E. Swayne, J.R. Glisson, L.R. McDougald, L. K. Nolan, D. L. Suarez and V. Nair, John Wiley & Sons Inc.: New Jersey, USA: 61–86.
- SNOECK, C.J., OWOADE, A.A. AND COUACY-HYMAN, E., ALKALI, B.R., OKWEN, M.P., ADEYANJU, A.T., KOMOYO, G.F., NAKOUNÉ, E., FAOU, A.L and MULLER, C.P. (2013): High genetic diversity of Newcastle disease virus in poultry in West and Central Africa: Cocirculation of genotype XIV and newly defined genotypes XVII and XVIII. *Journal of Clinical Microbiology*, 51(7): 2250–2260.
- van BOVEN, M., BOUMA, A., FABRI, T.H.F., KATSMA, E., HARTOG, L. and KOCH, G. (2008): Herd immunity to Newcastle disease virus in poultry by vaccination. *Avian Pathology*, 37(1): 1–5.
- WESTBURY, H.A. (1981): Newcastle disease virus in Australia. *Australian Veterinary Journal*, 57: 292–298.
- WINTERFIELD, R.W., DHILLON, A.S. and ALBY, L.J. (1980): Vaccination of chickens against Newcastle disease with live and inactivated Newcastle disease virus. *Poultry Science*, 59(2): 240–246.