



Management of Epitheliogenesis Imperfecta in a Piglet (*Sus Scrofa domestica*) in Ibadan, Nigeria

Ogunro, B. N.¹; Otuh, P. I.¹; Olatunji-Akioye, A.²; Emikpe, B. O.³; Oyebanji, V.³; Adejumobi O.⁴ and Morenikeji, O.⁵

¹ Veterinary Teaching Hospital, University of Ibadan, Ibadan, Nigeria; ²Department of Veterinary Surgery, Faculty of Veterinary medicine, University of Ibadan, Ibadan, Nigeria; ³Department of Veterinary Pathology, Faculty of Veterinary medicine, University of Ibadan, Ibadan, Nigeria; ⁴Department of Veterinary Medicine, Faculty of Veterinary medicine, University of Ibadan, Ibadan, Nigeria; ⁵The Zoological Garden, University of Ibadan, Ibadan, Nigeria. *Corresponding author: Email: ogunrob@gmail.com; Tel No: +2348036051866.

INTRODUCTION

Epitheliogenesis imperfecta (EI), also known as aplasia cutis congenita, is a congenital discontinuity of squamous epithelium (Benoit-Biancamano *et al.*, 2006; Moriello, 2010). It affects various species of animals and a hereditary predisposition have been reported in cattle (Awasum *et al.*, 2006; Radostits *et al.*, 2000; Gholap *et al.*, 2014) in which the caudal abdominal skin around the groin was absent and in some cases the buccal mucus membranes are also affected (Ingwersen, 2010). The pathogenesis of the condition has been described to be due to a recessively inherited mutation in the integrin beta 4 (ITGB4) gene or one of the genes encoding the three subunits of the extracellular adhesion ligand (laminin 5) associated with the hemidesmosome-anchoring filament complexes. (Milenkovic *et al.*, 2003; Peters *et al.*, 2015)

Affected animals usually die of ulceration and opportunistic infection especially when the condition is extensive (Moriello, 2010) and this condition has been described to be

incompatible to life as reported by Awasum *et al.* (2006). Surgical correction is usually recommended to save the life of affected animals which are otherwise culled (Awasum *et al.*, 2006). Diagnosis of EI is done by clinical and histological demonstration of congenital absence of epidermis or mucosal epithelium in an animal (Benoit-Biancamano *et al.*, 2006).

Domestic pig population in Nigeria was estimated to be 3,500,000 heads (Bourn *et al.*, 1994). Despite the relatively common occurrence of EI in pigs globally (Benoit-Biancamano *et al.*, 2006; Moriello, 2010), this appears to be the first case report of the occurrence in pigs in Nigeria based on the available records. This case report presents the clinical (gross) and histological description of a case of EI in a piglet in Nigeria, which was successfully managed conservatively. This is a first report of a case of EI in pigs and a novel successful treatment method by conservative medical management. This may provide an alternative management method other than

surgery and culling the diseased animals.

CASE HISTORY

A two-year-old, multiparous, 83kg large white sow raised at the University of Ibadan Zoological garden, for public view, farrowed on April 21, 2015. The litter comprises four females and three males. A glistening red, skinless patch was observed at the caudal part of the dorsum on the male piglets shown in Figure 1. The lesion was observed shortly after birth as explained by the animal handler who monitored the parturition process. The sow had previously farrowed to six piglets a litter of six, eight months ago and none of the piglets in the previous litters had any apparent congenital abnormality.

The day old piglet with skin defect was the only runt in the litter and weighed 1.4kg with a rectal temperature of 37.9°C, 3hours after birth. The dimension of the affected area was 60cm² as measured using Motic images plus 2.0ML software; Motic China Group Co., Ltd. It was raw, well demarcated, glistening red, asymmetrical, skinless patch and approximately oval. The margin appeared to inverted (Figure 1). The

long axis extended 8cm from the lateral aspect of the left thigh to 2cm of the dorsal aspect of the right flank. The shorter axis had a diameter of 6cm along the dorsal third of caudal aspect of the left flank, extending to the rump.

A tentative diagnosis was reached based on the observation of the congenital skinless patch on the neonate.

Cutaneous biopsy samples (approximately 4mm²) were obtained from the cranial and caudal margins of the lesion. Local analgesia was achieved by infiltration with 1% Lidocaine (Alpha Pharmacy, Nigeria) around the sites of biopsy sampling. The specimens were fixed in 10% neutral-buffered formalin, processed routinely, stained with haematoxylin and eosin (H&E). The lesion was cleaned with mild antiseptic (0.05% Chlorhexidine) and daily application of natural honey (obtained from the Veterinary Surgery unit, University of Ibadan) and Penicillin ointment 100,000 IU, (NIM Pharma Ltd., Nigeria) was done for two weeks. 20mg ascorbic acid, 10mg Augmentin® (GlaxoSmithkline, UK), and a drop of pediatric multivitamin (abidec®, Belco Pharma, India) were given orally for

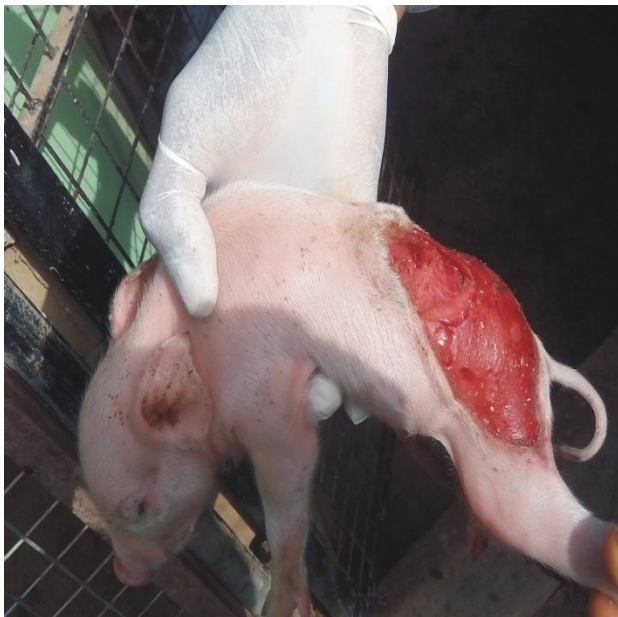

Figure 1: Affected piglet showing the area of de-epithelialization (60 sqcm)

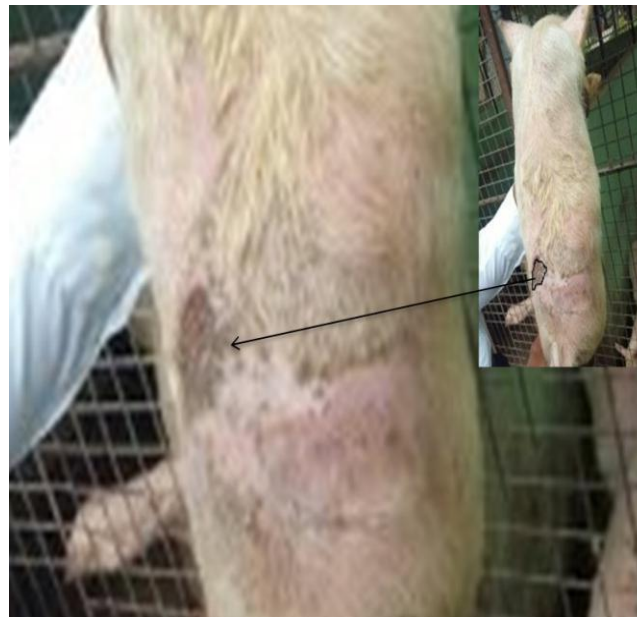

Figure 2: Healing progress after 21 days of treatment

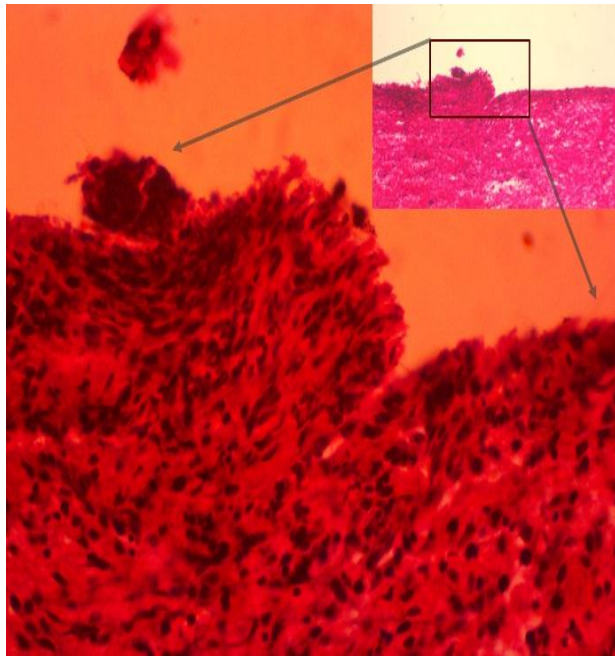


Figure 3: Histopathological section of the skin defect showing discontinuation of stratum spinosum x400

14 days. Daily application of fly repellent (0.1% cyfluthrin) on the dorsum of the piglet was done. In order not to encourage possible cannibalism from the sow or litter mates, no wound dressing was applied as the affected area was left for *per secundam*. The piglet was kept along with its litter mates to suckle.

RESULTS AND DISCUSSION

The histopathological findings presented as clear absence of strata of the epidermal layer from the stratum spinosum to the stratum corneum (Figure 2). Picture presented with a cornified or partially cornified cells with round to oval shaped nucleus typical of stratum basale layer of the epidermis. This section of the epidermis also appears thickened with multilayered cells described above which gave a morphological diagnosis of parakeratotic hyperkeratosis. However, there was conspicuous absence of inflammatory cells which suggested absence of an inflammatory response and rules out trauma as a possible etiology (Figure 3 a & b). Diagnosis of Epitheliogenesis imperfecta

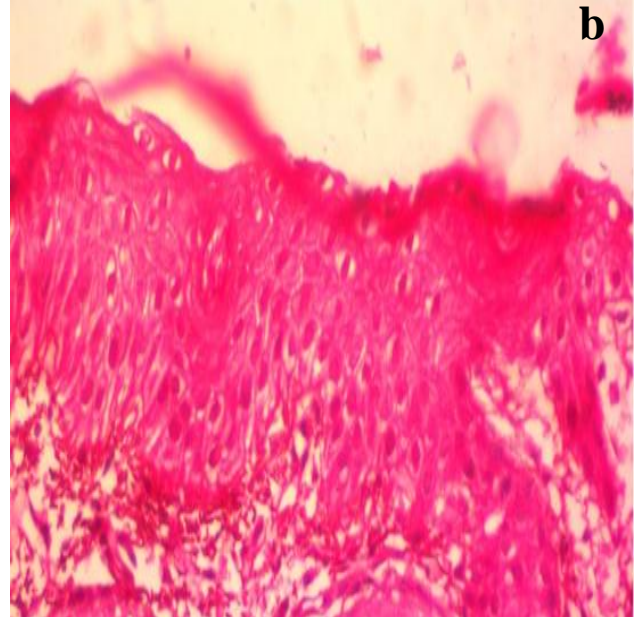
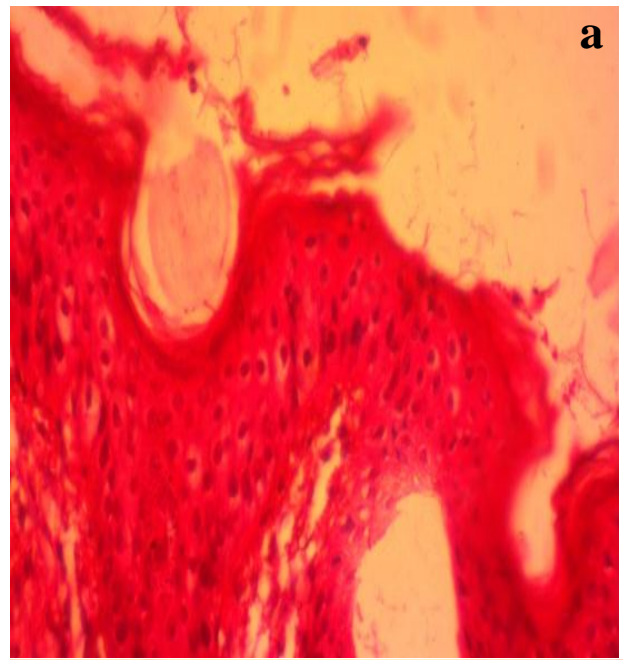


Figure 4 (a & b): Histological details of skin sections

was based on the clinical observation of congenital skin discontinuity and histopathological findings. The major differential diagnosis for an animal presenting with congenital discontinuity of squamous epithelium include epidermolysis bullosa which is characterized by cutaneous blisters in response to trauma (Scott, 1988) and this was absent in this case.

By the 3rd day post treatment, evidence of granulation tissue was seen topically, at the

center of the lesion. The subcutaneous bulla located at the cranial margin of the lesion gradually shrunk and by the 10th day had completely disappeared. The healing was faster at the caudal margin than at the cranial margin. By the 3rd week the lesion had almost completely healed (Figure 4) and the piglet did not show any other obvious signs of ill-health.

Epitheliogenesis imperfecta (EI) is a congenital discontinuity in cutaneous covering which has been reported in several species of animals, especially in the domestic pig (*Sus scrofa domesticus*) (Benoit-Biancamano *et al.*, 2006; Moriello, 2010). The dearth of published reports of EI in piglets in Nigeria may be as a result of consideration to cull rather than treat affected piglets or failure to document cases of EI in commercial piggeries within the country. The decision to treat rather than cull the piglet affected here was borne out of the fact that the pigs were kept in the zoological garden for display and education rather than for commercial purposes. Moreover, effective ways of treating EI would reduce the rate of culls and losses in large pig herds (Benoit-Biancamano *et al.*, 2006).

A non-surgical approach to managing this case was chosen since the cutaneous aplasia was too wide for the margins to be surgically apposed. The importance of ascorbic acid, honey, broad spectrum antibiotics, as well as other vitamins in wound healing have been previously described (Galley, 1995; Winkler, 2010; Eyarefe *et al.*, 2014). The administration of a broad spectrum antibiotic (Augmentin®) in the course of the treatment was to prevent opportunistic infection which is a common cause of death from EI as reported by Stannard, (2000). The case described here was similar to that reported by Benoit-Biancamano *et al.* (2006) where male predisposition, caudal location of the lesion and the involvement of only one piglet in the litter were observed.

This case report showed that the conservative treatment approach reported here was successful in the management of EI hence should be recommended in other animals with similar presentations.

REFERENCES

- AWASUM, C.A., SACEY, A.K.B., SALAMI, S.O., SAMBO, S.J, IBRAHIM, N.D.G., DIDEL, M., OBJIAKU, I.N, MAIRABO, R.R., ESIEVO, K.A.N. AND HASSAN, A.Z. (2006). Surgical correction of an atresic ectopic urinary bladder and Epitheliogenesis Imperfecta in a Friesian-Zebu crossbred bull calf. Proceedings of 43rd NVMA Congress, Gidan Matasa, Minna, Niger State, Nigeria.
- BENOIT-BIANCAMANO M.O., DROLET R. AND D'ALLAIRE S. (2006). Aplasia cutis congenita (epitheliogenesis imperfecta) in swine: observations from a large breeding herd. J Vet Diagn Invest., 18(6):573-579.
- BOURN D., WINT W., BLENCH R. AND WOOLEY E. (1994). Nigerian Livestock Resources Survey. World Animal Review., 78:49-58.
- EYAREFE, O.D., OLOGUNAGBA, F.M. AND EMIKPE, B.O. Wound Healing Potentials of Natural Honey in Diabetic and Non-Diabetic Wister rats. (2014). African Journal of Biomedical Research, 17, (1): 15-21
- GALLEY, H.F. Vitamin C and pressure sore. (1995). Journal of Dermatological Treatment, 6, 195-198.
- GHOLAP, P.N., KALE, D.S. AND SIROTHIA, A. R. (2014). Genetic Diseases in Cattle. A review. Res. J. Animal, Veterinary and Fishery Sci., 2(2), 24-33.
- INGWERSEN, W. Congenital and inherited anomalies of the Digestive System. (2010). The Merk veterinary Manual

- 10th Ed. Merck & Co., INC. Whitehouse station, N.J., USA. 145
- MILENKOVIC D., CHAFFAUX S., TAOURIT S., GU'ERIN G. (2003). A mutation in the LAMC2 gene causes the Herlitz junctional epidermolysis bullosa (H-JEB) in two French draft horse breeds. *Genetics Selection Evolution, BioMed Central*, 35 (2), pp.249-256.
- MORIELLO, K.A. Congenital anomalies of the skin. (2010) *The Merck veterinary Manual 10th Ed. Merck & Co., INC. Whitehouse station, N.J., USA: 770.*
- PETERS M., REBER I., JAGANNATHAN V., RADDATZ B., WOHLSEIN P., and DRÖGEMÜLLER C. (2015). DNA-based diagnosis of rare diseases in veterinary medicine: a 4.4 kb deletion of ITGB4 is associated with epidermolysis bullosa in Charolais cattle. *BMC Veterinary Research*, 11:48. doi: 10.1186/s12917-015-0366-0.
- RADOSTITS, O. M., GAY, C. C., BLOOD, D. C. AND HINCHCLIFF, K. W. (2000). Inherited defects of the skin. In: *Veterinary Medicine, W.B. Saunders, Philadelphia, PA: 1755–1759.*
- STANNARD, A.A. (2000). Congenital diseases. *Veterinary Dermatology*. 11(3): 211-215
- WINKLER, K.P. (2010). Wound management. In: *The Merck veterinary Manual 10th Ed. Merck & Co., INC. Whitehouse station, N.J., USA: 1565.*