



## Cranio-facial and Ocular Morphometrics of the Male Greater Cane Rat (*Thryonomys swinderianus*)

Igado, O. O.<sup>1\*</sup>; Adebayo, A. O.<sup>2</sup>; Oriji, C. C.<sup>1</sup> and Oke, B. O.<sup>1</sup>

<sup>1</sup>Department of Veterinary Anatomy, Faculty of Veterinary Medicine, University of Ibadan, Nigeria..

<sup>2</sup>Department of Veterinary Anatomy, College of Veterinary Medicine, Federal University of Abeokuta, Ogun State, Nigeria. \*Corresponding Authors: Email: mayowaigado@yahoo.com; Tel No:+2348035790102.

### SUMMARY

Cranio-facial indices still remain a useful means of early detection of the characteristic facial appearance of some syndromes. The cranio-facial and gross ocular morphometry of the male Greater cane rat (*Thryonomys swinderianus*) was studied using 9 adults. A total of twenty seven parameters were determined for each head. Linear measurements were determined on each eyeball using digital vernier calliper, measuring rule and a piece of twine. Cranio-facial parameters assessed included distance between medial canthi, height of the incisor, extent of oral commissures, width and length of the pinnae. All measured parameters were correlated with the body weight. The highest positive correlation was observed between the body weight and the width of the head, while the heights of the two upper incisors showed the lowest negative correlation with the body weight. The weights of the animals, heads and both eyeballs were  $1.97 \pm 0.37$  kg,  $252.00 \pm 36.89$  g, and  $1.00 \pm 0.12$  g respectively. With increase in the use of wildlife as experimental animals, results from this study may find application in the field of comparative anatomy and pathological studies as well as in wildlife clinical applications.

**Key words:** Greater cane rat, craniofacial index, anthropometric indices, ocular measurements.

### INTRODUCTION

The greater cane rat - GCR (*Thryonomys swinderianus*), which is also known as grasscutter, is a wild, herbivorous, hystricomorphic rodent, reputed for its tasty and high quality meat. In the West African sub-region, it is a potential food source providing high quality protein for both urban and rural populations (Addo *et al.*, 2007). Consequently, grasscutters are now being

domesticated and captive-reared in parts of West Africa where they are sometimes referred to as micro livestock (Karikari and Nyameasem, 2009).

The GCR lives by reed-beds and riverbanks in Sub-Saharan Africa and can grow to nearly 2 ft (0.61 m) in length weighing as much as 8.6 kg (van der Merwe, 2000; Adebayo *et al.*, 2009). It has rounded ears, a

short nose, and coarse bristle hair. The forefeet are smaller than the hind feet. Cane rats have a tendency to adopt plantations as habitat, feeding on agricultural crops such as maize, wheat, sugarcane and cassava, thereby earning the label 'agricultural pest'. The cane rat is said to be sexually matured at 7 months of age and at the weights of 1.6 kg and 2.1kg for male and female respectively (Adu and Yeboah, 2003; Adebayo *et al.*, 2009)

Regional anatomy of the head is an important aspect of gross anatomy showing the spatial relationship of the organs in this region and is a tool that has been extensively used in forensic archaeology. Craniofacial indices in humans have been useful in the early detection, diagnosis and study of the development of the characteristic facial appearance of some syndromes like the Williams syndrome (Hovis and Butler, 1997). Craniofacial indices have been reported in several animals such as the Sahel goat (Shawulu and Kwari, 2010), dog (Igado, 2014), pig (Olopade *et al.*, 2011) and fruit bat (Igado *et al.*, 2012).

Previous research on the anatomy of the GCR includes neuro-morphometry (Byanet *et al.*, 2009), reproductive studies (Adebayo *et al.*, 2009; Olukole *et al.*, 2010; Adebayo *et al.*, 2014), tooth eruption and dentition (van der Merwe, 2000) and the alimentary canal (van Zyl *et al.*, 2005).

In spite of the availability of some literature on the craniofacial and ocular indices of domestic animals and wildlife in literature, electronic search did not reveal any documentation on the craniofacial indices in the greater cane rat. This study therefore aims to document the craniofacial indices and gross ocular morphometry that can serve as baseline data for comparative, pathological and forensic/archaeological studies as well as in wildlife clinical manipulations.

## MATERIALS AND METHODS

Ethical approval for this research was obtained from the Faculty of Veterinary Medicine, University of Ibadan, Nigeria, ethical code no: ethics 03/14/04. All procedures and handling of the rats followed the guide for the care and use of experimental animals (National Institute of Health (NIH), USA and the Faculty of Veterinary Medicine, University of Ibadan, Nigeria. A total of nine adult male greater cane rats were obtained from the rat colony housed in the Experimental Giant Rat Unit, College of Veterinary Medicine, Federal University of Agriculture, Abeokuta, Nigeria. The rats were raised from birth in the University and their ages ranged from 18 to 24 months.

Each animal was weighed with a weighing scale (Electronic Kitchen Scale, Camry® EK5350) and euthanized with chloroform, using a chloroform chamber (0.1 ppm, Analar®). The heads were severed with quick cervical decapitation at the atlanto-occipital joint, the eyeballs removed by enucleation according to the method previously described by Igado (2011); and weighed immediately with a digital weighing scale having a sensitivity of  $1 \times 10^{-3}$  grams (Microwa swiss balance®, Mettler-Toledo, Switzerland). Measurements on the eyeballs were obtained with the aid of digital Vernier callipers (Neiko®, sensitivity of 0.01mm), a length of string and a centimetre rule. All weights obtained were recorded in grams (g), while all linear measurements were recorded in centimetres (cm). All specimens were photographed with a digital camera (Sony® Cyber-shot, 7.2 megapixels) and named according to Nomina Anatomica Veterinaria (NAV), 2005. A total of twenty seven (27) parameters were measured on each specimen.

**Weight of animal (WOA)**

This was determined using a standard digital scale (Electronic Kitchen Scale, Camry® EK5350). Measurements were recorded in kilograms and converted to grams.

**Weight of head (WOH)**

Also determined using a standard digital scale. Measurements were recorded in kilograms and converted to grams.

**Weights of left and right eyeballs (WOE/l & WOE/r respectively)**

Determined with a digital weighing scale (Microwa® Swiss balance, Mettler-Toledo, Switzerland) and recorded in grams.

**Width of head (WiOH)**

This was the maximum width of the head, measured as the distance between the right lateral and the left lateral sides, across the zygomatic bones, with the aid of Vernier calipers.

**Widths of the pinnae, left and right (WiPil & WiPir respectively)**

This was measured as the widest distance between the lateral edges of each pinna.

**Distance between Medial Canthi (DMC)**

Distance between the two medial canthi of the left and right eyes.

**Length of the head (LOH)**

Distance from the most rostral part of nasal region to the caudal portion of the occipital bone.

**Extent of oral commissures (ROL)**

This was determined using a string, as the distance between the two lateral commissures of the closed lips. The length of the string was thereafter determined with a meter rule.

**Lengths of pinnae, left and right (LPil & LPir respectively)**

This was measured from the base of the pinna to its tip.

**Palpebral Fissure Lengths, Left and Right (PFLl & PFLr)**

Measured as the distance between the medial and lateral canthi of each eye.

**Philtrum Height (PH)**

Measured from the most dorsal aspect of the philtrum to the lowest aspect of the philtrum.

**Height of the External Nares, Left and Right (HeENl & HeENr respectively)**

Maximum vertical distance between the dorsal and ventral borders of each of the nares.

**Height of Upper and Lower Incisor Both Left and Right (HeUil, HeUIr, HeLil and HeLlr)**

Height of the externally visible incisors, measured from the gumline to the tip of the teeth; recorded in centimetres.

**Antero-posterior circumference of the eyeball Left and Right (AP/l & AP/r respectively)**

The circumference of the eyeball, around the median plane from the anterior to the posterior pole, determined with the aid of a string, which was then measured with Vernier calliper.

**Medio-lateral circumference of the eyeball Left and right (ML/l & ML/r respectively)**

The circumference of the eyeball along the mediolateral plane (equator), determined with the aid of a string, which was then measured with Vernier calliper.

### Peri-orbital circumference of the eyeball Left and Right (PO/l & PO/r respectively)

The circumference of the eyeball, measured immediately caudal to the cornea, along the mediolateral and antero-posterior planes. This was determined with the aid of a string, which was then measured with Vernier calliper.

The craniofacial and ocular parameters measured are illustrated in Plates 1-4.

The relative weights of the head and eyeballs were obtained by using this formula  $\left(\frac{\text{organ weight}}{\text{body weight}}\right) * 100$

**Statistical Analysis:** All data obtained were analysed with Student's 't' test (Graph pad prism version 4), and level of significance was calculated at  $P < 0.05$ .

**Table I:** Values for craniofacial indices and ocular parameters in the male adult greater cane rat (*Thryonomys swinderianus*)

Parameters measured	Mean $\pm$ S.D. (n = 9)
Weight of Animal	1.969 $\pm$ 0.374 kg
Weight of Head	252 $\pm$ 36.89 g
Weight of the eyeball (left)	0.514 $\pm$ 0.069 g
Weight of the eyeball (right)	0.486 $\pm$ 0.090 g
Total eyeball weight	1 $\pm$ 0.115 g
Width of Head	9.45 $\pm$ 1.702 cm
Width of the pinna (left)	5.175 $\pm$ 1.335 cm
Width of the pinna (right)	5.05 $\pm$ 1.674 cm
Distance between the two Medial Canthi	3.722 $\pm$ 0.471 cm
Length of Head	11.25 $\pm$ 0.592 cm
Extent of oral commissure	4.144 $\pm$ 0.997 cm
Length of Palpebral Fissure (left)	1.20 $\pm$ 0.141 cm
Length of Palpebral Fissure (right)	1.178 $\pm$ 0.130 cm
Height of External Nares (left)	0.26 $\pm$ 0.055 cm
Height of External Nares (right)	0.20 $\pm$ 0.071 cm
Philtrum Height	1.956 $\pm$ 0.557 cm
Pinna Length (left)	3.233 $\pm$ 0.332 cm
Pinna Length (right)	3.056 $\pm$ 0.332 cm
Length of Upper Incisor (left)	1.075 $\pm$ 0.171 cm
Length of Upper Incisor (right)	1.025 $\pm$ 0.171 cm
Length of Lower Incisor (left)	1.1 $\pm$ 0.408 cm
Length of Lower Incisor (right)	1.1 $\pm$ 0.408 cm
Antero-Posterior circumference of the eyeball (left)	3.486 $\pm$ 0.212 cm
Antero-Posterior circumference of the eyeball (right)	3.433 $\pm$ 0.197 cm
Medio-lateral circumference of the eyeball (left)	3.514 $\pm$ 0.261 cm
Medio-Lateral circumference of the eyeball (right)	3.4 $\pm$ 0.277 cm
Peri-Orbital circumference of the eyeball (left)	3.086 $\pm$ 0.204 cm
Peri-Orbital circumference of the eyeball (right)	3.10 $\pm$ 0.265 cm

**RESULTS**

The body weights of the greater cane rat (GCR), expressed as Mean ± Standard Deviation was 1969.0 ± 373.7 g, the weight of the head left, right and both eyeballs were 252 ± 36.89 g, 0.514 ± 0.069 g, 0.486 ± 0.090 g and 1 ± 0.115 g respectively (Table 1). The relative head and eyeball (both eyeballs) weights were calculated to be 13.341 ± 3.712% and 0.052 ± 0.009% respectively. Comparing the distance between medial canthi to the width of the head in percentage gave a value of 40.8 ± 8.478%.

Values for parameters measured on the eyeballs were higher in the left eyeball than the right, except for the periorbital circumference where the right was slightly higher than the left (left - 3.086 ± 0.204 cm, right - 3.10 ± 0.265 cm). These differences in values were negligible. For all measurements comparing the left values to the right, there were no statistical significance (P>0.05).

Pearson’s correlation coefficient values (r) of the body weight against other parameters revealed the highest positive correlation to

the width of the head (r = 0.803), and the lowest to the left pinna length (r = 0.159). Lowest negative correlation was observed with the height of the upper incisors (r = -0.917), and the highest to the length of the head (r = -0.128) (Table 2).

Following a significant correlation between the body weight and the width of the head, a regression formula was calculated thus:

$$Y = 0.004X + 1.65$$

Where Y is the width of the head (HW in centimetres), and X is the body weight (WOA in grams).


**DISCUSSION**

The head is the most important part of the body, due to the location of some vital organs such as the brain, eyeball and some other sense organs (Shawulu and Kwari, 2010). The appearance of some of these vital organs has served as important clinical indices in different animal species. For instance, the teeth has been used for ageing, the mucous membrane of the eye has been used to evaluate anemic state, the wetness of

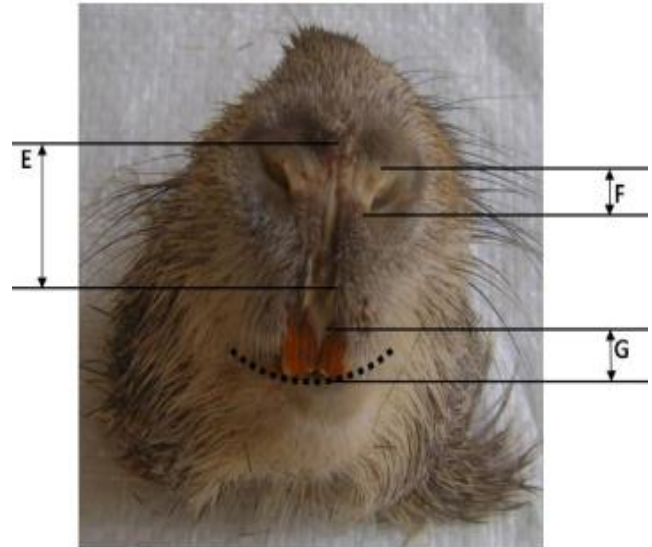
**Table II:** Pearson’s correlation coefficient (r) of body weight against other craniofacial and ocular parameters of the greater cane rat (*Thryonomys swinderianus*)

	WOH	LOH	ROL	DMC	WiOH	WiPil	WiPir	LPil	LPir
WOA	-0.291	-0.128	-0.253	-0.133	0.803	0.217	0.272	0.159	0.223
	PFLl	PFLr	PH	HeENl	HeENr	HeUll	HeUlr	HeLll	HeLlr
WOA	0.343	0.228	-0.215	0.188	0.166	-0.917	-0.917	0.163	0.163
	WOE/l	WOE/r	AP/l	AP/r	ML/l &	ML/r	PO/l	PO/r	
WOA	-0.152	-0.276	-0.323	-0.375	-0.261	-0.381	-0.333	-0.287	

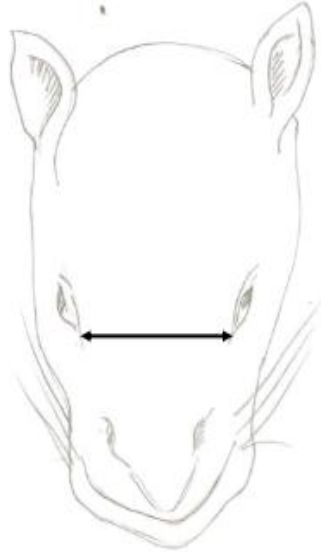
Key: Weight of animal (WOA), Weight of head (WOH), Weights of left and right eyeballs (WOE/l & WOE/r respectively), Width of head (WiOH), Widths of the pinnae, left and right (WiPil & WiPir respectively), Distance between Medial Canthi (DMC), Length of the head (LOH), Rima Oris Length (ROL), Lengths of pinnae, left and right (LPil & LPir respectively), Palpebral Fissure Lengths, left and right (PFLl & PFLr respectively), Philtrum Height (PH), Height of the External Nares, left and right (HeENl & HeENr respectively), Height of Upper and Lower Incisor, left and right (HeUll, HeUlr, HeLll and HeLlr respectively), Antero-posterior circumference of the eyeball, left and right (AP/l & AP/r respectively), Medio-lateral circumference of the eyeball, left and right (ML/l & ML/r respectively), Peri-orbital circumference of the eyeball, left and right (PO/l & PO/r respectively)



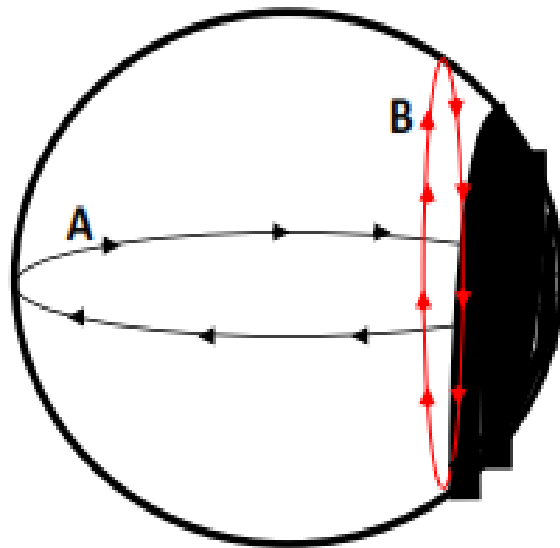
**Plate 1:** Lateral view of the head of the greater cane rat (GCR), showing the length of the pinna (A), width of the pinna (B), length of palpebral fissure (C) and the length of the head (D). Magnification x0.7



**Plate 2:** Rostral view of the head of a GCR, showing the philtrum height (E), the height of the external nares (F) and the length of the upper incisors (G). Dotted line represents extent of oral commissure. Magnification x0.8



**Plate 3:** Schematic drawing of the dorsal view of the head of the GCR. Arrow shows the distance between the two medial canthi of the eyes



**Plate 4:** Schematic of the dorso-lateral view of the eyeball of the GCR, showing the Antero-posterior circumference (A), and the Peri-orbital circumference (B)

the muzzle and saliva secretions has been used as a clinical index for fever, dehydration from sunken eyeballs and

starvation from periorbital depressions (Peacock, 1996). The head has also served as bases for taxonomic classification within

and between species and breeds (Gall, 1996). The craniofacial and gross ocular indices characterized in this study can be useful in the clinical manipulation of the greater cane rat which is currently undergoing domestication and captive rearing. The average body weights of the rats used in this study were similar to that reported in a previous study by Olukole and Obayemi (2010).

The GCR appeared to show a higher relative eyeball weight ( $0.052 \pm 0.009\%$ ), compared to 0.022% in the African giant rat (Olude *et al.*, 2011), considerably lower than the 0.769% reported in the Australian hopping mouse (*Notomys alexis*) (Smith, 1976), but similar to the 0.086% in the albino rat (*Sprague-Dawley*) and 0.077% in the albino mouse (CLS-MON) (Smith, 1976). The relative eyeball weight obtained from this study is however similar to that obtained in some other mammals like the pig (Olopade *et al.*, 2011), dog (Igado, 2011), but considerably lower than that obtained in some birds like the Japanese quail (Igado and Aina, 2010).

Apart from the eyes being an organ of vision, a number of other parameters or indices have been derived from the weight, or the weight of one or more of its components, e.g. age estimation in the coypus and the wild house mouse using the weight of the lens (Gosling *et al.*, 1980; Rowe *et al.*, 1985), body weight estimation using the weight of the eyeballs in the guinea pig (Latimer, 1951), the Japanese quail (Igado and Aina, 2010), dog (Igado, 2011) and the pig (Olopade *et al.*, 2011).

In the current study, the left eyeball had higher values for weight, unlike a previous report in human males, where the right eyes had absolute higher values (Todd *et al.*, 1940). These differences might be due to an insignificant difference in the weight of the components, especially since the difference was negligible and no statistically significant differences were observed

( $P > 0.05$ ); or according to Todd *et al.* (1940), could also be due to an error in determination. It is worth mentioning however, that similar asymmetries between the left and right parts have been mentioned in other vertebrates (Getty, 1975; Mercola and Levin, 2001; Igado, 2011). In this study, this asymmetry was observed in all parameters measured, except the length of the lower incisors.

The GCR has characteristically relatively small pinnae, when compared to that of the bat (Igado *et al.*, 2012), which has smaller size relative to the cane rat. The reason for this could possibly be due to the fact that prior to domestication, the GCR are known to live in nests from grasses, burrow underground and run close to water when threatened. Having small ears may be an adaptive feature to aid hiding, and enhance burrowing. Also, as rodents, they are known to depend more on their sense of smell for survival.

Unexpectedly, the weight of the head, length of the head and the length between oral commissures all showed negative correlation to the weight of the animal ( $r = -0.291, -0.128, -0.253$  respectively), although with very small values. This should not be taken to mean that the relationship between these values is inversely proportional, but may imply that these values may not necessarily increase at the same rate at which the weight increases, especially since the GCR is known to have a small head and a stocky body.

The incisors of the GCR were reported to be deciduous teeth and persistent throughout life (van der Merwe, 2000). They are curved in appearance and insert deep into the maxillae (upper incisor) and mandible (lower incisor) (van der Merwe, 2000). Photographic images by van der Merwe (2000) show the lower incisors to be longer than the upper. This difference in length is consistent with findings from the current study. The high negative correlation

observed between the body weight and the height of the upper incisors does not necessarily mean that the value of one will increase while the other decreases, but may mean that the length of the incisors are not weight dependent, as they are present in GCR at birth (van der Merwe, 2000), and because there were younger animals with higher body weights as observed in this study. However the left and right lower incisors correlated positively, while the left and right upper incisors correlated negatively with the body weight.

The value obtained when comparing the distance between medial canthi to the width of the head shows that the eyes are quite laterally placed. This lateral placement in hunted animals is a means of survival, to enable them have a wider visual range (Dyce *et al.*, 2002).

Craniofacial indices are an important anthropometric tool, in the field of orthodontic research and reconstructive surgery. It has been found to be a more reliable tool than radiographs when performing soft tissue surgery (Ngeow *et al.*, 2009). Craniofacial index has also been used to study the facial morphology of 26 ethnic groups/races in the world, highlighting the features peculiar to each race (Farkas *et al.*, 2005). As a tool, among other uses, craniofacial indices in animals can be used to highlight species or breed peculiarity. In spite of the abundance of data in human subjects of different races, there is a relative paucity of information in animals.

## CONCLUSION

The use of craniofacial indices to detect, diagnose and study the development of the characteristic facial appearance in animals, especially wildlife still remains an untapped and novel area of research, in spite of the increased use of wildlife in experimental research. The information provided in this work will serve as basis for further work on the development of the characteristic facial

appearance of the greater cane rat as well as aid in the early detection and diagnosis of disease in this animal.

## ACKNOWLEDGEMENTS

This work was supported by the University of Ibadan Senate Research Grant (SRG/FVM/2010/1b) awarded to BOO. The authors gratefully acknowledge the technical assistance of the laboratory technologists in the Departments of Veterinary Anatomy of the University of Ibadan, Nigeria and the Federal University of Agriculture, Abeokuta, Nigeria. Also, Dr. B.O. Olugasa, of the Department of Veterinary Public Health and Preventive Medicine, University of Ibadan, Nigeria, for his invaluable help with the regression analysis

## REFERENCES

- ADDO, P.G., AWUMBILA, B., AWOTWI, E. and ANKRAH, N.A. (2007). Reproductive characteristics of the female grasscutter (*Thryonomys swinderianus*) and formulation of colony breeding strategies. *Livest. Res. Rur. Dev.*, 19 (4), Article 59.
- ADEBAYO, A.O., OKE, B.O. and AKINLOYE, A.K. (2009). The Gross Morphometry and Histology of the Male Accessory Sex Glands in the Greater Cane Rat (*Thryonomys swinderianus*, Temminck). *J.Vet. Anat.* 2(2), 41 – 51.
- ADEBAYO, A.O., AKINLOYE, A.K., OLUKOLE, S.G., OYEYEMI, M.O., TAIWO, V.O., IHUNWO, A.O. and OKE, B.O. (2014). Gross, Histological and Ultrastructural Features of the Bulbourethral Gland in the Greater Cane Rat (*Thryonomys swinderianus*). *Anat. Histol. Embryol.* (In press).
- ADU, E.K. and YEBOAH, S. (2003). On the use of perineal stain as an index of sexual maturity and breeding



- condition in the male greater cane rat (*Thryonomys swinderianus*, Temminck). *Trop. Anim. Health Prod.* 35, 433–439.
- BYANET, O., ONYEANUSI, B.I. and IBRAHIM, N.D.G. (2009). Sexual Dimorphism with Respect to the Macro-Morphometric Investigations of the Forebrain and Cerebellum of the Grasscutter (*Thryonomys swinderianus*). *Int. J. Morphol.* 27(2), 361-365.
- DYCE, K.M., SACK, W.O., WENSING, C.J.G. (2002). Textbook of Veterinary Anatomy. Third edition, Saunders. ISBN 0-7216-8966-3.
- FARKAS, L.G., KATIC, M.J., FORREST, C.R., ALT, K.W., BAGIC, I., BALTADJIEV, G., et al. (2005). International anthropometric study of facial morphology in various ethnic groups/races. *J. Craniofacial Surg.* 16, 615-46.
- GALL, C. (1996). Goat breeds of the world, Centre for Tropical Agriculture, Weikersheim: Margraf, 47-69.
- GETTY, R. (1975) Sisson and Grossman's The Anatomy of the Domestic Animals. 5th edn. W.B. Saunders Company, Philadelphia
- GOSLING, L.M., HUSON, L.W. and ADDISON, G.C. (1980). Age Estimation of Coypus (*Myocastor coypus*) from Eye Lens Weight. *J. Appl. Ecol.* 17(3), 641-647.
- HOVIS, C.L. and BUTLER, M.G. (1997). Photoanthropometric study of craniofacial traits in individuals with Williams syndrome. *Clin. Gen.* 51(6), 379 – 387.
- IGADO, O.O. and AINA, O.O. (2010). Some Aspects of the Neurometrics and Oculometrics of the Japanese Quail (*Coturnix coturnix japonica*) in Nigeria. *J. Morphol. Sci.* 27(3-4), 133-135.
- IGADO, O.O. (2011). Gross Morphometric Study of the Eyeball and Tongue of the Nigerian Local Dog. *IJAE*, 116(1), 104-110.
- IGADO, O.O., OMOBOWALE, T.O., AJADI, R.A. and NOTTIDGE, H.O. (2012). Craniofacial morphometrics and macro-neurometrics of the fruit bat (*Eidolon helvum*). *Eur. J. Anat.*, 16 (3), 172-176.
- IGADO, O.O. (2014). A study of the craniofacial morphometry of the Nigerian local dog. *J. Sci. Res.* 13:1-4.
- KARIKARI, P.K. and NYAMEASEM, J.K. (2009). Productive Performance and Carcass Characteristics of Captive Grasscutters. *World Applied Sciences Journal* 6 (4): 557-563.
- LATIMER, H.B. (1951). The weight of the eyeballs in the guinea pig. *The Anat. Rec.*, 110(3), 349-357.
- MERCOLA, M. and LEVIN, M. (2001). Left-right asymmetry determination in vertebrates. *Annual Rev. Cell Develop. Biol.* 17, 779-805.
- NGEOW, W.C. and ALJUNID, S.T. (2009). Craniofacial anthropometric norms of Malaysian Indians. *Indian J. Dental Res*, 20, 313-319.
- OLOPADE, J.O., IGADO, O.O., NWAFOR, C.I., ALAMU, A.O. and ONWUKA, S.K. (2011). Some aspects of the craniofacial indices and macro neurometrics of the Nigerian local pig (*Sus Scrofa*). *IJAE*, 116(1), 38-44.
- OLUDE, M.A., OLOPADE, J.O., IGADO, O.O., MUSTAPHA, O.A., and AKINLOYE, A.K. (2011). Some aspects of the orbital and ocular morphometry of the African giant rat (*Cricetomys gambianus*, Waterhouse). *J. Vet. Anat.*, 4(1): 11 – 18.

- OLUKOLE, S.G., OYEYEMI, M.O. and OKE, B.O. (2010). Gonadal and extragonadal sperm reserves of the domesticated adult African greater cane rat (*Thryonomys swinderianus*). *Reprod. Biol.* 10(2), 155-158.
- OLUKOLE, S.G. and OBAYEMI, T.E. (2010). Histomorphometry of the Testes and Epididymis in the Domesticated Adult African Great Cane Rat (*Thryonomys swinderianus*). *Int. J. Morphol.* 28(4), 1251-1254.
- PEACOCK, C. (1996). Improving goat production in the tropics. A manual for development workers, Farm-Africa (editor) 5<sup>th</sup> Edition, WB. Saunders Company, Philadelphia.
- ROWE, F.P., BRADFIELD, A., QUY, R.J. and SWINNEY, T. (1985). Relationship between Eye Lens Weight and Age in the Wild House Mouse (*Mus musculus*). *J. Appl. Ecol.* 22(1), 55-61.
- SHAWULU, J. C. and KWARI, H. D. (2010). Craniofacial Indices of the Different Ecotypes of the Sahel Goat in Nigeria. *Nig. Vet. J.*, 31(4), 287 – 290.
- SMITH, C. J. D. (1976). Gross anatomical and microscopic observations on the orbit and its content in *Notomys alexis*. *Aust. J. Zool.*, 24: 479-89.
- TODD, T.W., BEECHER, H., WILLIAMS, G.H. and TODD, A.W. (1940). The weight and growth of the human eyeball. *Human Biol.* 12(1), 1-20.
- VAN der MERWE, M. (2000). Tooth succession in the greater cane rat *Thryonomys swinderianus* (Temminck, 1827). *J. Zool.* 251, 541-545.
- VAN ZYL, A., RAMBAU, R.V., VAN der MERWE, M. (2005). Aspects of the anatomy and histology alimentary canal of the greater cane rat, *Thryonomys swinderianus*, with reference to feeding physiology. *Afr. Zool.* 40(1), 25-36.