



Preliminary Assessment of Vertebral Heart Score of the Nigerian Mongrel Dog

Olatunji-Akioye, A. and Alabi, B.

Department of Veterinary Surgery and Reproduction, Faculty of Veterinary Medicine, University of Ibadan.
*Corresponding author: Email: bonik2001@yahoo.com; Tel No:+2348034091407.

SUMMARY

Vertebral Heart Score is a reliable method of determining cardiac size changes because it is able to assess cardiac enlargement. The canine heart has considerable breed variation than any other organ. It is assessed by a measurement of the cardiac silhouette by involving its long axis taken from the left main stem bronchus ventral border to the cardiac apex and short axis taken from central third region of the heart perpendicular to the longitudinal axis with a measuring scale on a lateral radiograph against the length of the vertebral column beginning from the fourth thoracic vertebra. Six Nigerian Mongrel Dogs (NMD) comprising 2 males and 4 females of about a year old weighing 14 ± 2.3 kg were used for this study. Right lateral radiographs were taken and the measurements of long and short axes were taken and compared with thoracic vertebrae to calculate the VHS. A mean VHS value of 9.6 ± 0.8 was determined. The mean VHS value of the male which represented 33.3% was 10.35 while that of female which represented 66.7% was 9.2. The VHS value for clinically healthy NMD was found to be 9.6 ± 0.8 which is slightly below the VHS average for dogs in the same medium weight class such as the Poodle, Cocker Spaniel and Bull dog and this may be due to differences in weight within the medium range weight among breeds or a sedentary existence of most of these dogs. This VHS value will be useful for determining cardiac enlargement specifically within this breed of dogs.

Key words: Vertebral Heart Score, Radiography, Right Lateral view, Mongrel dogs.

INTRODUCTION

Vertebral heart score (VHS), first described by Buchanan and Bucheler (1995), employs measuring the cardiac silhouette by involving its long axis (taken from left main stem bronchus ventral border to the cardiac apex with a measuring scale) and short axis (taken from central third region of heart perpendicular to the longitudinal axis with a measuring scale) on a lateral radiograph (Gugjoo *et al.*, 2013) and compared with the thoracic vertebra beginning at the fourth thoracic vertebra.

Radiographic diagnosis in canine cardiovascular medicine is used to identify generalized cardiac enlargement, specific cardiac chamber or great vessel enlargement, pulmonary parenchyma and vascular abnormalities, as well as determination of effusions in the body cavities (pleural effusion and ascites) (Kittleson, 1998; Dark *et al.*, 1996).

Thoracic radiography is one of the most commonly performed diagnostic tests in small animal practice (Gugjoo *et al.*, 2013). Radiographic interpretation can be done by subjective assessment or by using different measurement methods like cardiothoracic ratio (Gugjoo *et al.*, 2013), relationship with intercostal spaces (Kealy, 1989), and VHS. The VHS may be useful in assessing change in heart size over time as there is good correlation between the growth of visceral organs, including the heart, and vertebral body length (Church, 2011).

It is reported that electrocardiographic and echocardiographic parameters provide findings comparable to VHS for evaluation of heart size (Nakayama *et al.*, 2001; Gugjoo *et al.*, 2013). Accuracy of the VHS in the diagnosis of cardiac disease was first evaluated by Lamb *et al.* (2001). VHS has been reported to be fairly accurate for exclusion of coughs of cardiac origin in dogs with mitral valve disease (MVD) (Guglielmini *et al.*, 2009). In another report on congestive heart failure (CHF) due to

mitral valve regurgitation, VHS was found to be useful for detecting onset of CHF in Cavalier King Charles Spaniels with mitral regurgitation (Lord *et al.*, 2011; Gugjoo *et al.*, 2013). VHS has been found as the most accurate radiographic index for identifying dogs with pericardial effusion (PE) and also to differentiate it from other cardiac diseases (Guglielmini *et al.*, 2012; Gugjoo *et al.*, 2013). Authors have applied VHS along with the other cardiac diagnostic modalities *viz.*, ECG and echocardiography in diagnosing dilatation cardiomyopathy (DCM). It was observed that VHS increases significantly in DCM (Gugjoo *et al.*, 2012) and inference drawn was that VHS can be used to diagnose such conditions very effectively.

The establishment of VHS scores for every breed of animal and the knowledge of inter-breed variation in the thoracic conformation and selection of proper reference value may further enhance the value of VHS technique in diagnosis of cardiac enlargement in dogs. This is due to considerable breed variation with regards to normal heart size and shape and variations in the normal canine heart are more than in any organ (Gugjoo *et al.*, 2013; Root and Bahr, 2002). Gugjoo *et al.*, 2013 ascertained the VHS of several breeds of dog and NMD values were absent. There remains a paucity of information concerning the heart size of the Nigerian Mongrel dog. There may be under-diagnosis of cardiac conditions because although there is an increase in dog ownership for reasons like security, the incidence of cardiac disease in these dogs is static. The economics of diagnosing cardiac diseases may be a factor. Thus there is a need for an improved diagnostic method which employs simple tools inexpensively because of client inability or unwillingness to pay for specialized diagnostic tests like echocardiograms which may be necessary to fully diagnose the coughing dog which can

thus be diagnosed using the VHS. The huge diagnostic challenge in Nigerian Veterinary clinical practice is due in part to its fledgling status and a slowly increasing awareness of the population to the specialized diagnostic methods available with economics being the chief limiting factor. The VHS can be used to diagnose cardiac problems with accuracy and has even been found to be comparable to electrocardiographic and echocardiographic parameters (Nakayama *et al.*, 2001). It is very cheap and may be a very good alternate means of evaluating cardiac size. This study is a preliminary assessment of VHS of the Nigerian mongrel dog.

MATERIALS AND METHODS

Six Nigerian local dogs (2males and 4 females) of about 1 year with an average weight of 14 ± 2.3kg without clinical symptoms of cardiovascular or respiratory disease were included in this study. All dogs were evaluated by clinical examination including the physical examination, complete blood count and serum chemistry, thoracic radiography, electrocardiography and echocardiography. All examinations

were performed with manual restraint of the animals, without the use of sedation.

Radiographic scanning was performed using an Allengers x-ray machine: with focal film distance (FFD) 120cm, 14 x 17inches film in screen cassette was used. Right lateral view of all dogs was taken at full inspiration with the thoracic inlet as cranial landmark and centering on the caudal border of the scapula and the 10th rib as the caudal landmark. They were then analyzed by subjective assessment and the VHS measurements were taken using a rule.

The measurements of long axis and short axis were taken as described by Church (2011) and VHS determined by comparing with thoracic vertebra. The mean and standard deviation of the values were calculated and results are shown in Table I.

RESULTS AND DISCUSSION

Despite the availability of other diagnostic techniques like echocardiography (Root and Bahr, 2002), thoracic radiography is one of the most commonly performed diagnostic tests in small animal practice (Gugjoo *et al.*, 2013). Radiographs of thoracic cavity are useful as a diagnostic modality to detect

TABLE I: VHS of NMD

S/N	LA	SA	VHS
Dog 1	6.0	4.0	10.0
Dog 2	4.5	3.8	8.3
Dog 3	5.1	3.9	9.0
Dog 4	5.0	4.5	9.5
Dog 5	6.0	4.5	10.5
Dog 6	6.0	4.2	10.2

Mean vertebral heart score is;

$$\frac{10.0 + 8.3 + 9.0 + 9.5 + 10.5 + 10.2}{6} = 9.6v$$

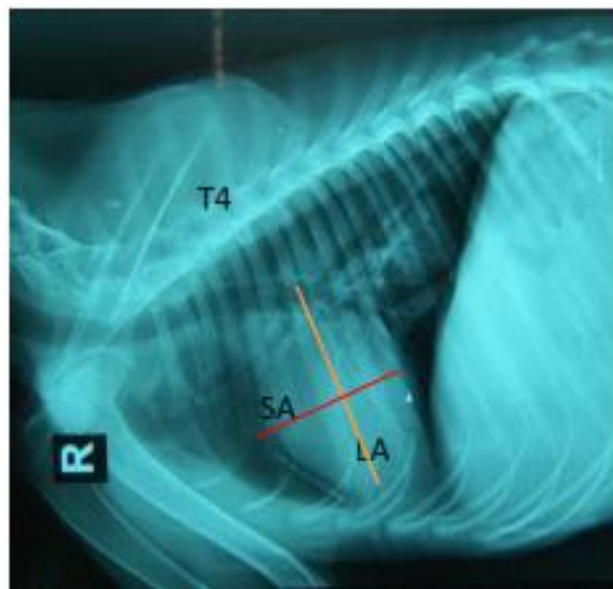


Figure. 1: Lateral radiograph showing how VHS was measured

heart diseases and have a potential to provide information equivalent to other cardiac diagnostic modalities (Gugjoo *et al.*, 2013). The VHS may be useful in assessing change in heart size over time as there is good correlation between the growth of visceral organs, including the heart, and vertebral body length (Church, 2011). The VHS of 9.6 ± 0.8 determined in this study for the Nigerian mongrel dog is slightly lower than the VHS determined for exotic breeds of dogs classified in similar weight and body size as medium (Gugjoo *et al.*, 2013). It is less than the VHS for dogs like the Poodle (Fonsecapinto and Iwasaki, 2004), Cocker Spaniel (Pinto, 2002) and Bulldog (Jepsen-Grant *et al.*, 2013). Although, there is good correlation between the growth of different visceral organs and vertebral body length, this value (i.e., NMD's VHS value) suggests a less than average growth for the Nigerian mongrel dog as its VHS falls within that for small sized dogs like Shih Tzu, Lhasa Apso and the Dachshund (Jepsen-Grant *et al.*, 2013). This could be due to the feeding and management regimen of Nigerian dogs in general. Cardoso *et al.*, 2011 reported VHS of 10.9 in American pit bull terrier and suggested a need for increased cardiac output to meet the demands of increased muscle mass in this specie. The sedentary lifestyle of Nigerian Mongrel dogs may be responsible for the low VHS value compared to dogs in its weight range. The VHS for some large breed dogs however also does not follow this correlation as seen with the VHS score for dogs like the German Shepherd (Lamb *et al.*, 2001) and the Rottweiler (Marin *et al.*, 2007). There may be some other reason for this discrepancy other than feeding which may be adduced for the Nigerian mongrel dog. In conclusion, the VHS score of the clinically healthy Nigerian mongrel dog was found to be 9.6 ± 0.8 and this value may be used in evaluating changes in cardiac size specifically for this breed of dogs in addition to clinical signs, physical examination and

other specialized cardiac examinations where affordable, in the diagnosis of cardiac disease.

REFERENCES

- BUCHANAN, J.W. and BUCHELER, J. (1995). Vertebral scale system to measure canine heart size in radiographs. *J Am Vet Med Assoc* **206**(2):194-199.
- CARDOSO, M.J.L., CLAUDINO, J.L. and MELUSSI, M. (2011). Measurement of cardiac size by the VHS method in healthy American pit bull terrier. *Int J of Morph* **41**: **1**; 127-131
- CHURCH, W. (2011). Evaluating Heart Size on Radiographs. Cardiac Education Group. http://www.cardiaceducationgroup.org/common/cms/documents/TB_WChurch%208.11.pdf
- DARK, P., BONAGURA, J.D. and KELLY, D.F. (1996). Cardiac radiography. In: *Color Atlas of Veterinary Cardiology*, Mosby, St Louis: 32-37.
- FONSECAPINTO, B.C. and IWASAKI, M. (2004). Radiographic evaluation of the cardiac silhouette in clinically normal Poodles through the vertebral heart size (VHS) method. *Braz J Res Anim Sci* **41**: 261-267.
- GUGJOO, M.B., HOQUE, M., SAXENA, A.C. and ZAMA, M.M.S. (2012). Dilatation cardiomyopathy in dogs. *36th Annual Congress of ISVS and International Symposium held in Kolkata, India, 1st - 3rd November*.
- GUGJOO, M.B., HOQUE, M., SAXENA, A.C., ZAMA, M.M.S. and AMARPAL. (2013). Vertebral Heart system to measure heart size in dogs in thoracic radiographs. *Adv Anim Vet Sci* **1** (1): 1-4.
- GUGLIELMINI, C., DIANA, A., PIETRA, M., TOMMASO, M.D. and CIPONE, M. (2009). Use of the vertebral heart score in coughing

- dogs with chronic degenerative mitral valve disease. *J. Vet. Med. Sci.* **71** (1): 9-13.
- GUGLIELMINI, C., DIANA, A., SANTARELLI, G., TORBIDONE, A., TOMMASO, M.D., TOALDO, M.B. and CIPONE, M. (2012). Accuracy of radiographic vertebral heart score and sphericity index in the detection of pericardial effusion in dogs. *J Am Vet Med Assoc* **15** (8): 1048-1055.
- JEPSEN-GRANT, K., POLLARD, R.E. and JOHNSON, L.R. (2013). Vertebral heart scores in eight dog breeds. *Vet Radiol Ultrasound*, **54** (1): 3-8.
- KEALY, J.K. (1989). *Diagnostic radiology of the dog and cat. 2nd edition.* Saunders WB, Philadelphia: 258.
- KITTLESON, M.D. (1998). Radiography of the cardiovascular system, In: Kittleson MD, Kienle RD, editors, *Small Animal Cardiovascular Medicine*, Mosby: St Louis, 47-72.
- LAMB, C.R., WIKLEY, H., BOSWOOD, A. and PFEIFFER, D.U. (2001). Use of breed-specific ranges for the vertebral heart scale as an aid to the radiographic diagnosis of cardiac disease in dogs. *Vet. Rec.* **148**: 707-711.
- LORD, P. F., HANSSON, K., CARNABUCI, C., KVART, C. and HAGGSTROM, J. (2011). Radiographic heart size and its rate of increase as tests for onset of congestive heart failure in Cavalier King Charles Spaniels with mitral valve regurgitation. *J. Vet. Int. Med.* **25** (6): 1312-1319.
- MARIN, L.M., BROWN, J., McBRIEN, C., BAUMWART, R., SAMII, V.F. and COUTO, G. (2007). Vertebral heart size in retired racing Greyhounds. *Vet. Radiol. Ultrasound*, **48**: 332-334.
- NAKAYAMA, H., NAKAYAMA, T. and HAMLIN, R.L. (2001). Correlation of cardiac enlargement as assessed by vertebral heart size and echocardiographic and electrocardiographic findings in dogs with evolving cardiomegaly due to rapid ventricular pacing. *J. Vet. Int. Med.* **15**: 217-221.
- PINTO, A.C. (2002). Radiographic methods in the cardiac evaluation in dogs. *Veterinaria Noticias Univ Fed Uberlândia Brazil* **8**:67-75.
- ROOT, C.R. and BAHR, R.J. (2002). The heart and great vessels. In Thrall DE (ed) *Textbook of Veterinary Diagnostic Radiology.* 4th edition. Saunders WB Co: Philadelphia. 402-419.