



CASE REPORT

Urine Burn Dermatitis in a Two Year-Old Sudanese Ewe

*ABUBAKAR¹, A. A., GARBA², S., MSHELIA², P. C., JIBRIN², M. S. RAMBO², U. G., ³YAKUBU, Y. and YAKUBU¹, A. S.

¹Department of Veterinary Surgery and Radiology, ²Veterinary Teaching Hospital ³Department of Veterinary Public Health and Preventive Medicine Faculty of Veterinary Medicine, Usmanu Danfodiyo University, Sokoto

*Correspondence: babaji32002@yahoo.com; +234 8036659884,

INTRODUCTION

Burns have been classified according to severity. First degree burns involve the superficial epidermis and characterized by erythema, edema, and generally heal without complication. Second degree burns affect the entire epidermis, and characterized by erythema, edema, pain, and vesicles, and usually there is re-epithelization with proper wound care. Third degree burns involves the entire epidermis, dermis, and appendages and are characterized by necrosis, ulceration, and scarring. Diligent therapy and possibly skin grafting are indicated. Fourth degree burns involves the entire skin subcutis, and underlying fascia, muscles and tendon (Pascoe, 1981). Because of the difference between human and animals, burns in animals are appropriately classified as partial thickness or full thickness burns. And partial burns can be further divided as superficial and deep (John, 1993). Contact irritant dermatitis or urine burn dermatitis is an inflammatory skin reaction caused by direct contact with an offending substance. The disease is divided into two types, viz, primary contact dermatitis, and contact hypersensitivity (Muller et al., 1998). Primary irritant contact dermatitis is common in large animals and has numerous causes. Primary irritants have one thing in common; they invariably produced dermatitis if they come into direct contact with the skin in sufficient concentration for a long enough periods (Ihrke, 1983). Moisture is an important predisposing factor of this condition, as it decreases the effectiveness of normal skin barrier and increases the intimacy of contact between the agent and the skin surface (Scott, 1988). Commonly incriminated causes of primary irritant contact dermatitis includes body excretions (feces and urine), wound secretion, caustic substance (acids and alkalis), crude oil, diesel fuel, turpentine, leather preservatives, mercurial, various blisters, leg sweats, improperly utilized topical acaricide, bedding, and filthy environments (Stannard, 1972). To the best of our knowledge no such case has been reported in Nigeria.

KEY WORDS: Urine burns, Dermatitis, Sudanese ewe, Trichophytosis

CASE REPORT

On 16th February, 2009, a two year-old Sudanese ewe weighing about 25 kg was presented to the Ambulatory Unit of the Veterinary Teaching Hospital, Usmanu Danfodiyo University, Sokoto. The client's main complaint was presence of wound at perineal region due to accumulation of urine around the affected area for the past three months. The ewe was among a flock of forty seven sheep kept under intensive system of management. They are fed on wheat bran, beans husk, and hay.

CLINICAL EXAMINATION

On physical examination, there were dried necrotic lesions (urine burn dermatitis) on caudal part of the udder (plate II).

The hooves were overgrown, the ewe was alert but grinding its teeth. The rectal temperature, pulse and respiratory rates were 38.6°C, 86beats/minute, and 28 cycles/minute respectively. Sterile swab was taken from the moist portion of the lesion for bacterial culture and antibiotic sensitivity test, blood samples were taken for hematological analysis, and hemo-parasitological examination. Skin scrapings were taken for parasitological and mycotic examinations, and fecal sample for parasitology.

MANAGEMENT

Pre-laboratory results management, the ewe was placed on the right lateral recumbency with the left hind limb elevated to expose the lesion. The perineum was shaved, irrigated with normal saline and scrubbed using 0.5% chlorhexidine gluconate. The necrotic lesions around were debrided using scalpel blade. (Plate III)

The site was cleaned with 3% hydrogen peroxide and 0.5% chlorhexidine gluconate. Oxyteracycline spray was applied topically.

Procaine penicillin G (200mg) and Dihydrostreptomycine (250mg) injection at dose rate of 200,000 I.U/kg and 10 mg/kg were administered intramuscularly respectively for five day against possible secondary bacterial infections.

RESULTS

The bacteriology results yielded no bacterial growth. However, mycology results yielded *Trichophyton verrucosum* after 10 days of incubation at 37°C using Sabroud dextrose agar medium (SDA). Skin scraping for parasitology yielded no parasite, fecal sample also yielded no parasite. Hemo-parasitology sample yielded *Anaplasma ovis* (+). The results of the hematological analysis were within normal range. Based on the history, clinical signs as well as the laboratory findings, a clinical diagnosis of concurrent urine burns dermatitis and trichophytosis was made. 20% oxytetracycline long acting injection at dose rate 20 mg/kg intramuscularly once was administered to take care of the Anaplasmosis and 2% keteconazole cream was topically applied once a day for two weeks. The ewe was hospitalized throughout the period of treatment, and discharged after two weeks.

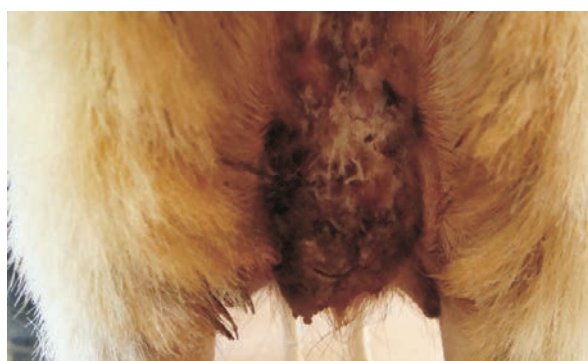

Plate 1

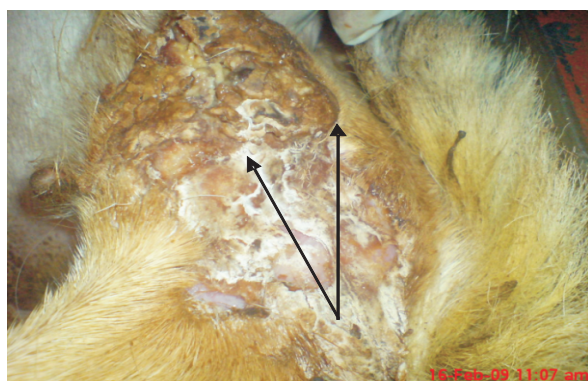


Plate 2

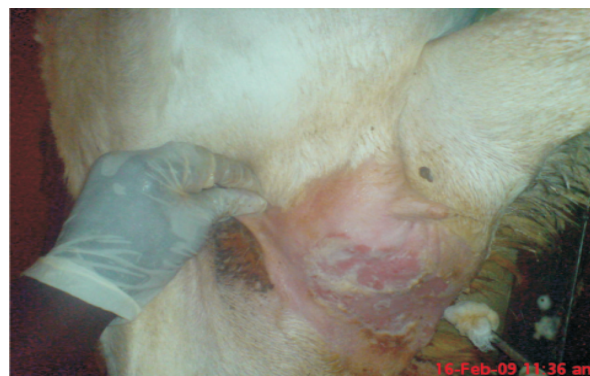

Plate 3

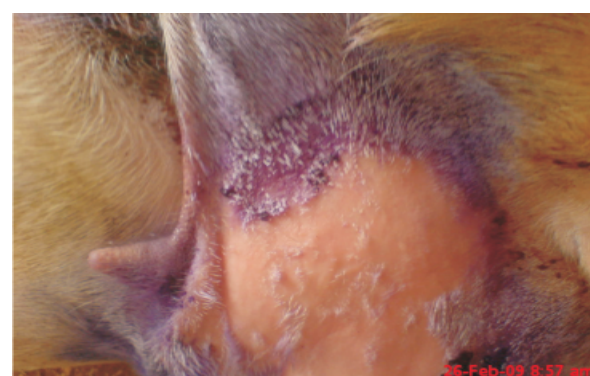


Plate 4

- Plate I: Perineal region of the ewe with arrow showing the necrotic lesion caudal to the udder
- Plate II: arrow showing the lesion around the udder region with the ewe on lateral recumbency
- Plate III: Arrow showing the necrotic lesions after surgical debridement
- Plate IV: The healed lesion with arrow showing hairs started re-growing

DISCUSSION AND RECOMMENDATION

Urine burn dermatitis also known as contact irritant dermatitis is an inflammatory skin reaction caused by direct contact with an offending substance usually chemical. There are two types of contact irritant dermatitis; primary irritant contact dermatitis and contact hypersensitivity (Muller, *et al.*, 1998). The case at hand is a primary irritant contact dermatitis because of the manifestation of the lesion, and the laboratory findings. Contact hypersensitivity was ruled out because of the laboratory results obtained. Hypersensitivity and allergic reaction usually lead to eosinophilia (Benjamin, 1979), but our hematology result indicated value of eosinophils within the normal range.

A number of substances such as soaps, detergents, weeds, insecticidal sprays, fertilizers, strong acids, and alkalis are potential

causative agents (Muller, *et al.*, 1998). Contact irritant dermatitis of urine has scarcely been reported in Nigeria. Most skin burns dermatitis especially of thermal and other chemicals (non urine) have been seen in both large and small animals in Nigeria but are often not diagnosed beyond clinical presentation. In this report however, the diagnosis of urine burns dermatitis was based on history, presented clinical signs, hematology, and mycology results.

On this basis we therefore recommend further investigations on the chemical constituents, and possible toxic effects of the urine of Sudanese breed of sheep. We also recommend regular trimming of hairs around the perineum and tail of the Sudanese breed sheep to avoid trapping and accumulation of urine.

ACKNOWLEDGEMENT

The authors acknowledged the contributions of laboratory technicians for processing the samples. The effort of Dr. Abdullahi Ja'afar and

Mallam AbdulSalam Habibullah of Department of Veterinary Physiology, Pharmacology and Biochemistry for preparing the manuscript is highly appreciated.

REFERENCES

- BENJAMIN, M. M. (1979): Outline of veterinary clinical pathology, 3rd Ed. The Iowa State University Press, Ames Iowa U.S.A. 87-88.
- IHRKE, P. J. (1983): Contact dermatitis. In: ROBINSON, N. E.: *Current Therapy in Equine Medicine*. Philadelphia, W. B. Saunders Company, 547.
- JOHN, T. P. (1993): Pathogenesis and treatment of thermal burns. In: HARARI, J.: *Surgical Complication of Wound Healing in the Small Animal Practice*. W. B. Saunders Company 143-146.
- MULLER, G. H., KIRK, R. W. and SCOTT, D. W. (1998): *Small animal dermatology*, 4th Ed. W. B. Saunders Company, Philadelphia. 771-775.
- PASCOE, R. R. (1981): Equine dermatoses. Sydney, University, Sydney Post-Graduate Foundation in Veterinary Science. *Veterinary Revision* No. 22.
- SCOTT, D. W. (1988): Large animal dermatology, W. B. Saunders Company, Philadelphia. 67-68.
- STANNARD, A. A. (1972): Some important dermatoses in the horse, *Medical Veterinary Practice*. **53**:31.