

---

# An aesthetic approach towards the temporary restoration of missing upper lateral incisors during orthodontic treatment

Katie Xu\* and Seong-Seng Tan\*†

Private practice, East Bentleigh\* and Florey Neuroscience Institute, University of Melbourne,† Melbourne, Australia

This clinical hint demonstrates an aesthetic method for masking spaces due to missing lateral incisors during orthodontic treatment. (Aust Orthod J 2015; 31: 236-238)

Received for publication: August 2015

Accepted: September 2015

Seong-Seng Tan: sst@unimelb.edu.au; Katie Xu: hi.katie.xu@gmail.com

Maxillary lateral incisors make up approximately 20% of all congenitally missing adult teeth.<sup>1</sup> It is the third most commonly missing tooth, the first being third molars and the second being mandibular premolars.<sup>2</sup> There is little gender variation, with females slightly more affected than males.<sup>3-6</sup> Interestingly, agenesis of both maxillary lateral incisors is more common than agenesis of only one.<sup>1</sup> Missing lateral incisors are also a common finding in cleft palate patients.<sup>7</sup> The prevalence among different ethnic groups is similar, affecting 1–2% of Northwest Europeans<sup>8-10</sup> and 1.3% of Japanese children.<sup>11</sup>

Congenitally missing maxillary lateral incisors present many challenges for the orthodontist when treatment planning and during active orthodontic treatment. Treatment often begins during the mixed dentition when agenesis is diagnosed at eight to nine years of age, most frequently by the family dentist.<sup>1,12,13</sup> The key reasons for seeking orthodontic treatment are centreline discrepancies, large residual spaces, arch asymmetry and incorrect tooth inclinations.<sup>14</sup>

The two main treatment options for agenesis cases are orthodontic space closure and resultant maxillary canine substitution, or orthodontic space opening to allow for prosthetic replacement. Neither option is ideal, as both carry significant biological and financial costs. Therefore, treatment decisions should only

be made after careful consideration of the patient's individual circumstances.<sup>15,16</sup>

Orthodontic space opening is often more suited for the older patient who presents with generalised spacing or with more than 6.5 mm of mesiodistal width per lateral incisor. Other factors include a low lip line, a Class III skeletal relationship or otherwise adverse skeletal base growth.<sup>15</sup> Orthodontic space opening can also restore lip contour, re-establish a normal buccal occlusion, redistribute the available space, and retract any protruded maxillary incisors while creating parallel roots if implants are to be placed.<sup>16</sup>

A common dilemma faced during active treatment is the need to maintain but also aesthetically mask the lateral incisor space. Often this is achieved with an acrylic denture tooth, bonded to an orthodontic bracket which allows it to be attached to a rectangular archwire. Ideally, the denture tooth should mirror the shade of the natural teeth and, following engagement to the wire, should sit comfortably within the edentulous space with snug mesial and distal contacts. The denture tooth should also be out of occlusion to avoid mobility or dislodgement during speech and function.

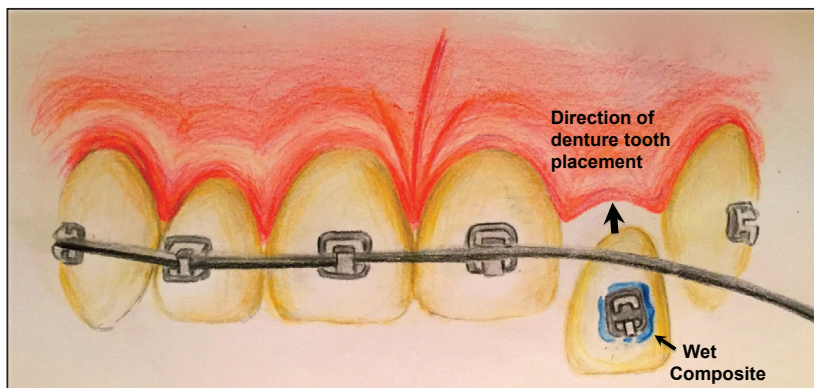
Clinically, an appropriate denture tooth is selected based on size, shape and shade. The base of the denture tooth is adjusted to conform to the maxillary lateral

edentulous ridge and generate even tissue pressure when engaged. The usual clinical practice is to light-cure a bracket onto the denture tooth outside of the mouth, followed by the attachment of the bracket (and tooth) to the rectangular wire using elastic modules, or for self-ligating brackets by full engagement of the wire in the bracket. This procedure, while convenient, too frequently results in a poorly adapted tooth, as there is no accurate way of determining beforehand the optimal position of the bracket. The outcome is often an unaesthetic and loose denture tooth with gaps gingivally and interproximally, resulting in significant tooth mobility and failure.

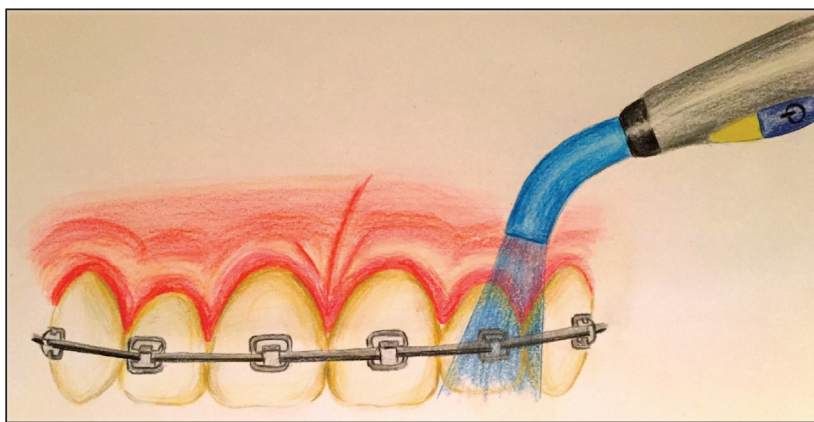
This clinical hint demonstrates a predictable and aesthetic method of positioning a denture tooth into the edentulous space. The appropriate denture tooth is selected for size, shape and colour to match surrounding soft and hard tissues before its undersurface is trimmed with an acrylic bur to fit the contour of the soft tissue ridge. The labial surface should be lightly sanded to accept the bracket. The bracket should then be loaded

with composite resin and placed on the denture tooth but not cured at this stage (Figure 1). This permits the tooth (with the uncured bracket) to be seated with light finger pressure into the most aesthetic and stable position on the alveolar ridge. The bracket (but not the tooth) carrying the wet composite can then be slowly slid across the tooth surface until it is fully engaged into the rectangular wire, at which time the resin may be light cured to secure the denture tooth into its optimal position (Figure 2). The denture tooth is then recontoured on the palatal and incisal aspects to remove any functional protrusive and lateral interferences. It needs to be emphasised that for bracket stability, this procedure will only work with rectangular archwires.

The above clinical sequence emphasises priority on denture tooth position over the bracket position. For added stability, a light ligature wire (0.012 inch) can be used to tie the bracket with the denture tooth to the adjacent teeth (Figure 3). In the accompanying example, an adult female patient presented with a



**Figure 1.** The denture tooth carrying the unset bracket is carefully manoeuvred behind the loosely ligated archwire. The emphasis is on aesthetic placement of the denture tooth in the edentulous space, without worrying about the bracket position.



**Figure 2.** Using finger pressure to hold the denture tooth in position, the archwire is engaged into the bracket slot before curing. The bracket is then secured to the archwire using elastic or steel ligatures.

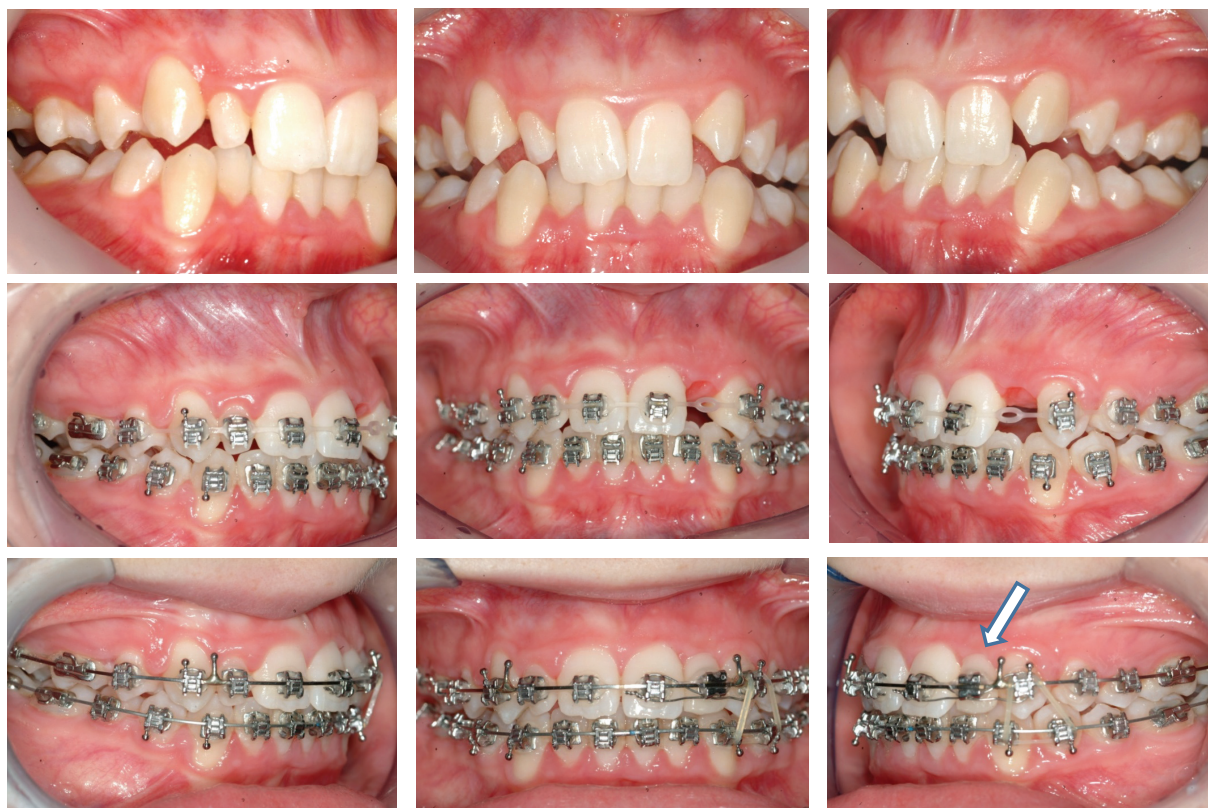

Figure 3. Clinical application of wet denture tooth technique to restore space from missing upper left lateral incisor (arrow).

congenitally missing upper left lateral incisor and a peg-shaped right lateral incisor. Treatment was provided to regain the upper left lateral incisor space by distalisation of the upper left quadrant. Following successful distalisation, the edentulous space was temporarily restored using a denture tooth (Figure 3). After treatment, the regained maxillary left lateral space was restored with a resin bonded bridge.

### Corresponding author

Professor Seong-Seng Tan  
 Florey Neuroscience Institute  
 University of Melbourne  
 Parkville, 3010  
 Victoria  
 Australia

Email: sst@unimelb.edu.au

### References

1. Stamatou J, Symons AL. Agenesis of the permanent lateral incisor: distribution, number and sites. *J Clin Pediatr Dent* 1991;15:244-6.
2. Sumiya Y. Statistic Study on Dental Anomalies in the Japanese. *J Anthropol Sci* 1959;67:215-33.
3. Bergström K. An orthopantomographic study of hypodontia, supernumeraries and other anomalies in school children between the ages of 8-9 years. An epidemiological study. *Swed Dent J* 1977;1:145-57.
4. Rølling S. Hypodontia of permanent teeth in Danish schoolchildren. *Scan J Dent Res* 1980;88:365-9.
5. Brook AH. A unifying aetiological explanation for anomalies of human tooth number and size. *Arch Oral Bio* 1984;29:373-8.
6. Aasheim B, Ogaard B. Hypodontia in 9-year-old Norwegians related to need of orthodontic treatment. *Scand J Dent Res* 1993;101:257-60.
7. Al Jamal GA, Hazza'a AM, Rawashdeh MA. Prevalence of dental anomalies in a population of cleft lip and palate patients. *Cleft Palate Craniofac J* 2010;47:413-20.
8. Grahnén H. Hypodontia in the permanent dentition: a clinical and genetic investigation. *Odont Revy* 1956;7:1-100.
9. Haavikko K. Hypodontia of permanent teeth. An orthopantomographic study. *Suom Hammaslaak Toim* 1971;67:219-25.
10. Hunstadbraten K. Hypodontia in the permanent dentition. *ASDC J Dent Child* 1973;40:115-7.
11. Yamasaki Y, Iwasaki T, Hayasaki H, Saitoh I, Tokutomi J, Yawaka Y et al. Frequency of congenitally missing permanent teeth in Japanese children. *Jpn J Ped Dent* 2010;48:29-39.
12. Alvesalo L, Portin P. The inheritance pattern of missing, peg-shaped, and strongly mesio-distally reduced upper lateral incisors. *Acta Odontol Scand* 1969;27:563-75.
13. Magnússon TE. Prevalence of hypodontia and malformations of permanent teeth in Iceland. *Community Dent Oral Epidemiol* 1977;5:173-8.
14. Robertsson S, Mohlin B. The congenitally missing upper lateral incisor. A retrospective study of orthodontic space closure versus restorative treatment. *Eur J Orthod* 2000;22:697-710.
15. Wexler G. Missing upper lateral incisors: orthodontic considerations in young patients. *Ann R Australas Coll Dent Surg* 2000;15:136-40.