
The efficacy of Hybrid Hyrax-Mentoplate combination in early Class III treatment: a novel approach and pilot study

Vandana Katyal,* Benedict Wilmes,* Manuel Nienkemper,* M. Ali Darendeliler,† Wayne Sampson⁺ and Dieter Drescher*

Department of Orthodontics, The University of Düsseldorf, Düsseldorf, Germany,* Department of Orthodontics, The University of Sydney, Sydney, Australia[†] and Discipline of Orthodontics, The University of Adelaide, Adelaide, Australia⁺

Introduction: The aim of the present study was to assess the skeletal, dental and soft tissue effects of a specific treatment protocol in consecutively treated patients who presented with a Class III malocclusion. Treatment involved the use of a Hybrid Hyrax (HH) in the maxilla, a Mentoplate in the mandible and the application of continuous intra-oral Class III elastics.

Method: The treated group was comprised of seven males and seven females (mean pretreatment age 10.4 ± 1.7 yr, range 7.8 – 12.9 yr). Treatment changes were analysed on lateral cephalograms taken 6–12 months prior to commencing treatment (T1) and at the finish of the orthopaedic phase (T2). Where a normality assumption was met, a parametric paired-sample *t*-test was used to assess the change differences at T1 and T2. For non-normal data, a non-parametric Wilcoxon sign rank test for related samples was used to assess T1 and T2 differences. The level of statistical significance was set at $p < 0.05$ (2-tailed).

Results: The average sagittal changes showed an improved SNA angle of $2.1 \pm 2^\circ$ ($p = 0.002$), an ANB angle of $1.9 \pm 1.8^\circ$ ($p = 0.002$), a Wits improvement of 3.4 ± 2.7 mm ($p < 0.001$) and an overjet reduction of 2.0 ± 2.2 mm ($p = 0.005$). There were no statistically significant correlations found between the age at T1, age at treatment start and age at T2 and the changes identified in the cephalometric variables (T2-T1).

Conclusion: The HH-Mentoplate Class III treatment protocol induced a mean Wits improvement of 3.4 mm in the maxillary and mandibular sagittal base relationship at the functional occlusal level. This was primarily achieved by sagittal maxillary skeletal protraction with negligible effects on the mandible, facial vertical dimension and the incisor angulations. A controlled clinical study with larger sample sizes and longer follow-up times is needed.

(Aust Orthod J 2016; 32: 88–96)

Received for publication: August 2015

Accepted: February 2016

Vandana Katyal: vandykatyal@gmail.com; Benedict Wilmes: wilmes@med.uni-duesseldorf.de; Manuel Nienkemper: nienkemm@web.de; M. Ali Darendeliler: ali.darendeliler@sydney.edu.au; Wayne Sampson: wayne.sampson@adelaide.edu.au; Dieter Drescher: d.drescher@uni-duesseldorf.de

Introduction

A skeletal Class III malocclusion is characterised by either mandibular prognathism, a maxillary deficiency or a combination of the two features.¹ Approximately half of all skeletal Class III malocclusions are reported to result from maxillary retrognathia² and hence orthopaedic maxillary protraction is considered a viable treatment option for growing patients with a midface deficiency. However, early correction

of maxillary retrognathia and the maintenance of the Class III skeletal correction still remains an orthopaedic challenge.^{3,4}

Maxillary advancement in a growing child has been widely described and a protracting force may be applied via an extra-oral facemask or by intra-oral appliances anchored to either dentition,^{4,5} ankylosed primary canines⁶ or skeletal anchorage systems inserted in the zygomatic, palatal or mental areas.^{7–11} To increase

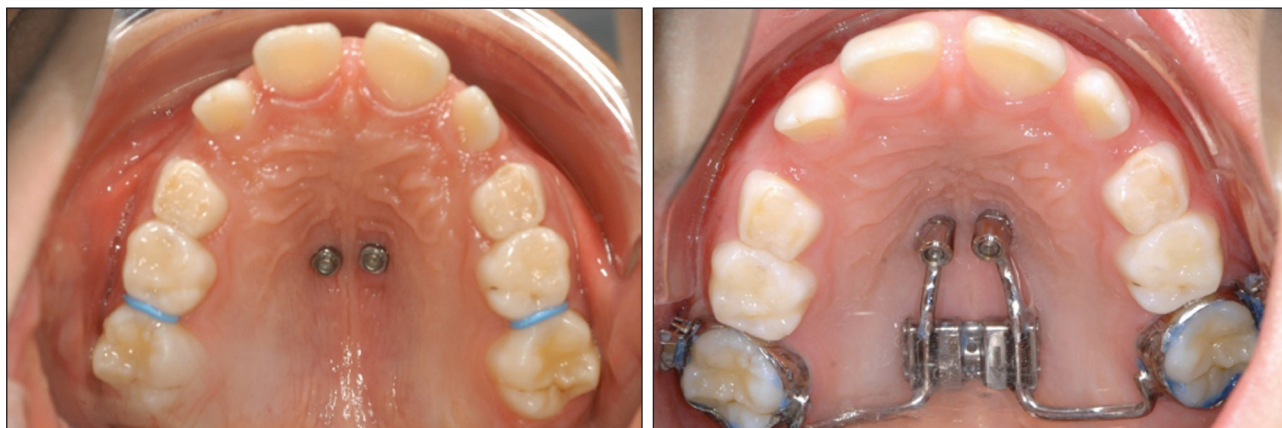

Figure 1. The Hybrid Hyrax (HH) anchored to two mini-implants in the anterior palate and upper molars (Source: University of Düsseldorf, Germany).

skeletal maxillary advancement and to avoid the possible dental side-effect of mesial movement of the dentition resulting in dental crowding,⁵ protraction therapy in growing children using skeletal anchorage has recently been advocated.⁷⁻¹¹ However, most studies have employed at least two or more surgical mini-plates or osseointegrated implants, which involve invasive placement and removal procedures.

Maxillary protraction is often started following a rapid palatal expansion procedure (RPE) because a proportion of Class III cases present with a narrowed maxilla.¹² Mobilisation of the midfacial sutures by RPE may be beneficial and induce a greater maxillary effect.¹³ Even though there is controversy regarding the effectiveness of RPE for improved maxillary protraction,¹⁴ its use is recommended in Class III treatment to enhance maxillary advancement.^{10,15-17}

Wilmes and colleagues introduced a novel RPE device called a Hybrid Hyrax appliance (HH, Figure 1), which uses two mini-implants in the anterior palate to provide sagittal skeletal anchorage for maxillary protraction during simultaneous palatal expansion.^{10,15-18} The mini-implants serve as an anterior skeletal anchorage unit, whilst deciduous or permanent molars are used as posterior dental anchorage (hybrid anchorage). In addition, Wilmes et al. described Class III management utilising a single Mentoplate (Figure 2) in the anterior mandible in combination with the HH.¹⁰ Since the Mentoplate is inserted subapical to the lower incisors, it may be used in patients as young as eight years of age with developing lower canines.

It may be hypothesised that the use of a HH in the upper arch and a Mentoplate in the lower arch transfers an orthopaedic force primarily to the skeletal struc-

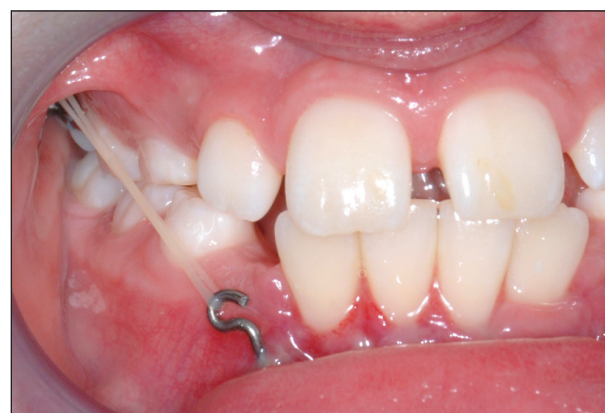

Figure 2. Class III intra-oral elastic forces as applied between the Hybrid Hyrax and Mentoplate arms bilaterally (Source: University of Düsseldorf, Germany).

tures. Therefore, the aim of the present study was to assess the skeletal, dental and soft tissue effects in consecutively treated Class III patients, as a result of a treatment protocol that involved the placement of a Hybrid Hyrax in the maxilla, a Mentoplate in the mandible and the use of continuous intra-oral Class III elastics.

Methods

The treatment group was comprised of 14 children, including seven males and seven females (mean pretreatment age 10.4 ± 1.7 yr, range 7.8 – 12.9 yr), who were consecutively treated for a skeletal Class III malocclusion (mean pretreatment Wits of -5.1 ± 2.1 mm, range -9.8 to -2.4 mm) requiring maxillary expansion and maxillary protraction. Standardised orthodontic pretreatment history, photographs and radiographs (lateral cephalogram and dental panoramic radiograph) were taken for all subjects at the University clinic, Düsseldorf, Germany.

Although patients were managed by different operators, the same protocol was followed for all of the treated group. At the commencement of treatment, two mini-implants (Benefit system, PSM Medical Solutions, Tuttlingen, Germany) for the HH and four bone screws for the Mentoplate (Promedia Medizintechnik, Siegen, Germany) were inserted under local anaesthesia. The HH device with a hyrax screw was subsequently fabricated in the laboratory and placed a week later. All patients were instructed to commence activating the hyrax screw (0.8 mm/day) until an upper midline diastema appeared. In addition, the application of Class III intra-oral elastics (3.5 oz., $\frac{3}{16}$ ") was commenced from hooks projecting intra-orally from the Mentoplate to hooks on the buccal arms bilaterally attached to the HH. The maxillary expansion and maxillary protraction occurred simultaneously. After the appearance of an upper midline diastema, the maxillary expansion rate was reduced to 0.4 mm/day. The clinical and surgical protocol for the placement and insertion of the HH-Mentoplate combination has been described previously by Wilmes and colleagues¹⁰ and was followed for all children in the treatment group.

Pretreatment (T1) lateral cephalograms were taken 6–12 months prior to commencement. Post-treatment (T2) lateral cephalograms were taken at the completion of the orthopaedic phase and/or at the removal of the HH-Mentoplate combination. The two lateral cephalometric images for each subject were adjusted for magnification differences and digitised using the Image Collector software (copyrights owner and creator – author DD). Nine skeletal, five dental and two soft tissue variables were measured on each lateral cephalogram, as shown in Figure 3. The digitising and subsequent measurements were performed by one author (VK) and randomly repeated at least a week later on 10 radiographs to determine the error of the method.

Data were analysed using statistical software SPSS (version 22, IBM Corp, NY, USA) and are presented as the mean and the standard deviation (SD) for continuous variables and as frequency or percentages for categorical variables. A normal distribution for all continuous variables was tested using the Shapiro-Wilk's test ($p > 0.05$). Where a normality assumption was met, parametric paired-sample *t*-test was used to assess the difference between the cephalometric measurements between T1 and T2. For non-normal data, a non-parametric Wilcoxon sign rank test for related

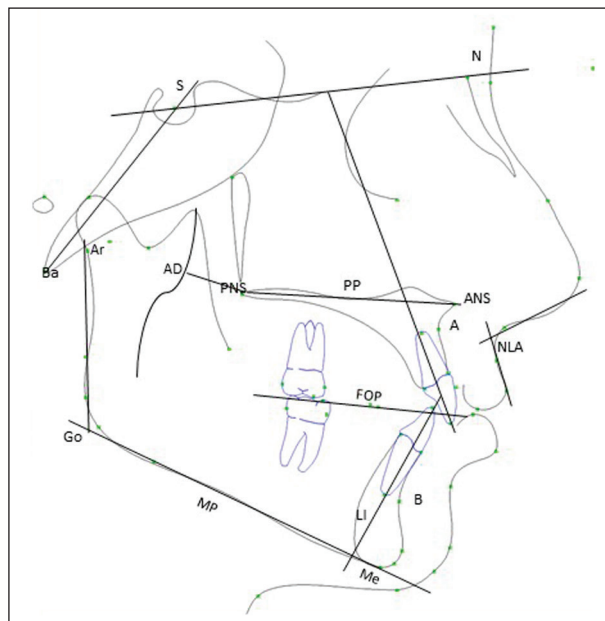


Figure 3. Lateral cephalometric reference landmarks, planes and angles analysed at pretreatment (T1) and post-treatment (T2).

Key: **SNA** (angle Sella-Nasion-A point), **SNB** (angle Sella-Nasion-B point), **ANB** (difference between angle SNB and SNA), **WITS** (sagittal discrepancy between A-point and B-point as measured on the functional occlusal plane FOP in mm), **NSBa** (cranial base flexure, angle Nasion-Sella-Basion), **SN-PP** (angle between Sella-Nasion line and the Palatal Plane), **SN-MP** (angle between Sella-Nasion line and Mandibular Plane), **PP-MP** (angle between Palatal Plane and Mandibular Plane), **ArGoMe** (gonial angle, angle Articulare-Gonion-Menton), **UI-PP** (angle between long axis of Upper Incisor and palatal plane), **LI-MP** (angle between long axis of Lower Incisor to Mandibular Plane), **UI-LI** (angle between long axes of Upper Incisor and Lower Incisor), **OJ** (overjet in mm), **OB** (overbite in mm), **AD-PNS** (distance most prominent anterior point on Adenoidal mass and Posterior Nasal Spine in mm) and **NLA** (nasolabial angle measured between the Nasal tip, Subnasale and the Upper Lip).

sample was used to assess the difference between cephalometric measurements at T1 and T2. The level of statistical significance was set at $p < 0.05$ (2-tailed). Pearson's bi-variate correlation test ($p < 0.05$, 2-tailed) was used to assess associations between the patient's age at T1, at treatment commencement and age at T2 and the change in cephalometric variables (T2-T1).

Intra-class correlation coefficients (ICC) were calculated to assess the error of the method using a two-way mixed model and absolute agreement type for all angular and linear cephalometric variables.

Results

The majority of the treated group were Caucasian and the average treatment duration was 0.88 ± 0.6 year. All mini-implants and Mentoplates showed high primary stability and remained stable throughout treatment.

The ICC varied from 0.873 to 0.911 for angular cephalometric measurements and from 0.872 to 0.901 for linear measurements. A satisfactory level of intra-observer reliability was established.

Descriptive statistics for the age of all subjects at T1, at treatment start and T2 are presented in Table I. All of the variables were normally distributed at T1 (Shapiro Wilk's test $p > 0.05$) except for ArGoMe ($p = 0.026$), OB ($p = 0.044$) and AD-PNS ($p = 0.005$). The statistical significance of differences between T2 and T1 variables analysed by non-parametric testing are presented in Table II. The average sagittal changes between T1 and T2 showed an improvement in SNA angle by $2.1 \pm 2^\circ$ ($p = 0.002$), ANB angle by $1.9 \pm 1.8^\circ$ ($p = 0.002$), Wits by 3.4 ± 2.7 mm ($p < 0.001$)

and overjet by 2.0 ± 2.2 mm ($p = 0.005$). There were no statistically significant correlations found between the age at T1, age at treatment start and age at T2 and the changes identified in the cephalometric variables (T2-T1).

Discussion

Summary of key findings with clinical interpretation

The present study of Class III treatment in growing children managed by skeletal anchorage using a HH-Mentoplate combination provides evidence that the method is effective in maximising skeletal change while minimising unwanted dental effects.

Table I. Descriptive statistics for the treated group at pretreatment (T1) and posttreatment (T2).

Characteristics of treated group N = 14 (7 males, 7 females)	Mean \pm SD	Median (50 th percentile)	Range
Age at pretreatment (T1) lateral cephalometric radiograph (yr)	10.4 \pm 1.7	10.5	7.8 – 12.9
Age at treatment commencement (yr)	11.2 \pm 1.5	11.1	9.0 – 13.5
Age at treatment finish and post-treatment (T2) lateral cephalometric radiograph (yr)	12.1 \pm 1.6	12.1	9.6 – 15.7

Table II. Statistical significance of differences between post-treatment (T2) and pretreatment (T1) cephalometric variables analysed.

Cephalometric variables (N = 14)	Mean (\pm SD) at pretreatment (T1)	Mean (\pm SD) at post-treatment (T2)	Mean (\pm SD) of the difference T2-T1	95% confidence intervals (lower, upper) of the difference T2-T1	Statistical significance of difference T2-T1 (p value)
SNA ($^\circ$)	78.1 \pm 4.0	80.2 \pm 3.2	2.1 \pm 2.0	0.9, 3.2	$p = 0.002$ ††
SNB ($^\circ$)	78.9 \pm 3.4	79.1 \pm 3.2	0.2 \pm 1.6	-0.8, 1.1	$p = 0.670$
ANB ($^\circ$)	-0.8 \pm 2.5	1.1 \pm 2.1	1.9 \pm 1.8	0.8, 2.9	$p = 0.002$ ††
WITS (mm)	-5.1 \pm 2.1	-1.7 \pm 1.6	3.4 \pm 2.7	1.8, 4.9	$p < 0.001$ ††
NSBa ($^\circ$)	128.8 \pm 3.4	129.1 \pm 3.2	0.4 \pm 1.7	-0.6, 1.4	$p = 0.420$
SN-PP ($^\circ$)	7.7 \pm 3.9	6.9 \pm 3.8	-0.8 \pm 0.9	-1.4, -0.3	$p = 0.004$ ††
SN-MP ($^\circ$)	36.6 \pm 5.1	36.7 \pm 4.3	0.1 \pm 2.2	-1.9, 1.4	$p = 0.853$
PP-MP ($^\circ$)	28.9 \pm 5.1	29.8 \pm 4.7	1.0 \pm 2.3	-0.4, 2.3	$p = 0.145$
ArGoMe ($^\circ$)	126.9 \pm 6.1	127.3 \pm 7.5	0.4 \pm 3.8	-1.8, 2.7	$p = 0.681$
UI-PP ($^\circ$)	112.6 \pm 7.5	113.5 \pm 6.0	0.9 \pm 8.5	-4.0, 5.8	$p = 0.702$
LI-MP ($^\circ$)	88.3 \pm 5.2	88.1 \pm 8.0	-0.2 \pm 5.9	-3.6, 3.2	$p = 0.893$
UHL ($^\circ$)	130.2 \pm 9.5	128.6 \pm 9.8	-1.6 \pm 10.7	-7.8, 4.5	$p = 0.578$
OJ (mm)	-0.7 \pm 2.2	1.4 \pm 1.4	2.0 \pm 2.2	0.7, 3.3	$p = 0.005$ ††
OB (mm)	0.2 \pm 2.2	0.2 \pm 1.0	0 \pm 2.1	-1.2, 1.2	$p = 0.955$
AD-PNS (mm)	15.2 \pm 4.2	16.1 \pm 4.4	0.9 \pm 3.3	-1.0, 2.8	$p = 0.319$
NLA ($^\circ$)	119.4 \pm 7.2	118.2 \pm 7.9	-1.2 \pm 4.5	-3.8, 1.4	$p = 0.321$

Key: †† Statistically significant at $p < 0.01$

There was a sagittal improvement of 2° ($SNA - 2.1^\circ \pm 2^\circ$, $ANB - 1.9^\circ \pm 1.8^\circ$). Since this was accompanied by negligible change in sagittal mandibular dentoalveolar base position (B-point) relative to the anterior cranial base, it suggested that the improvement was primarily produced by maxillary protraction at the dentoalveolar base (A-point). At the level of the occlusal plane, there was a mean improvement of 3.4 ± 2.7 mm in the Wits appraisal and 2.0 ± 2.2 mm improvement in overjet as a result of treatment. There were no significant changes seen in the upper and lower incisor angulations, which suggested anchorage preservation, the prevention of unwanted mesial movement of the upper dentition and resultant anterior crowding. Hence, it is likely that overjet correction was primarily due to an enhanced maxillary sagittal projection. In the vertical plane, the palatal plane rotated counter-clockwise (upwards and forwards) relative to the cranial base by approximately 0.8° but no other vertical side-effects were seen. A change of 0.8° , although statistically significant, was relatively small and might not be clinically significant. Figure 4 depicts the cephalometric changes produced by the HH-Mentoplate protocol seen between T1 and T2.

Comparison to previous work

A meta-analysis published by Jäger et al.¹⁹ described the mean skeletal and dental changes produced in Class III malocclusions treated with conventional maxillary protraction facemask or headgear. The composite effects showed mean improvements of SNA by 1.1° and ANB by 1.7° , which were lower than those reported in the present study.¹⁹ Additionally, maxillary protraction using a conventional facemask can result in unwanted proclination of upper incisors, retroclination of the lower incisors, as well as an increase in the vertical facial dimension.¹⁹ Interestingly, the effects reported in the present study, following the HH-Mentoplate protocol, did not show significant changes in incisor angulation or skeletal vertical dimension. Hence, the HH-Mentoplate protocol could benefit growing Class III patients who present with excessive proclination of the upper incisors, retroclination of the lower incisors and an increased vertical facial dimension.

The HH-facemask combination used by Nienkemper et al.²⁰ for Class III maxillary protraction improved mean SNA by 2.0° , ANB by 1.9° and Wits by 4.1 mm

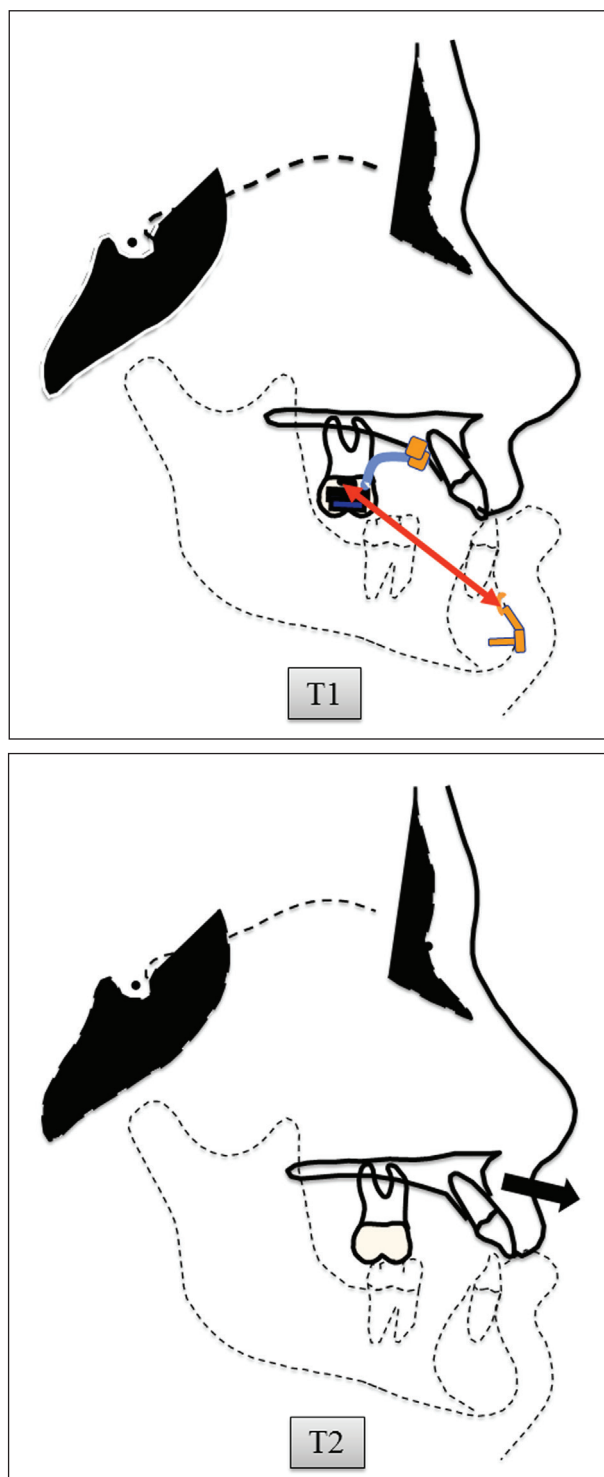


Figure 4. Cephalometric tracings depicting significant changes seen with Hybrid Hyrax-Mentoplate protocol before (T1) and after (T2) treatment.

without increasing the vertical facial dimension or upper incisor angulation, which is similar to the findings of the present study. Although the HH-Mentoplate is slightly more surgically invasive

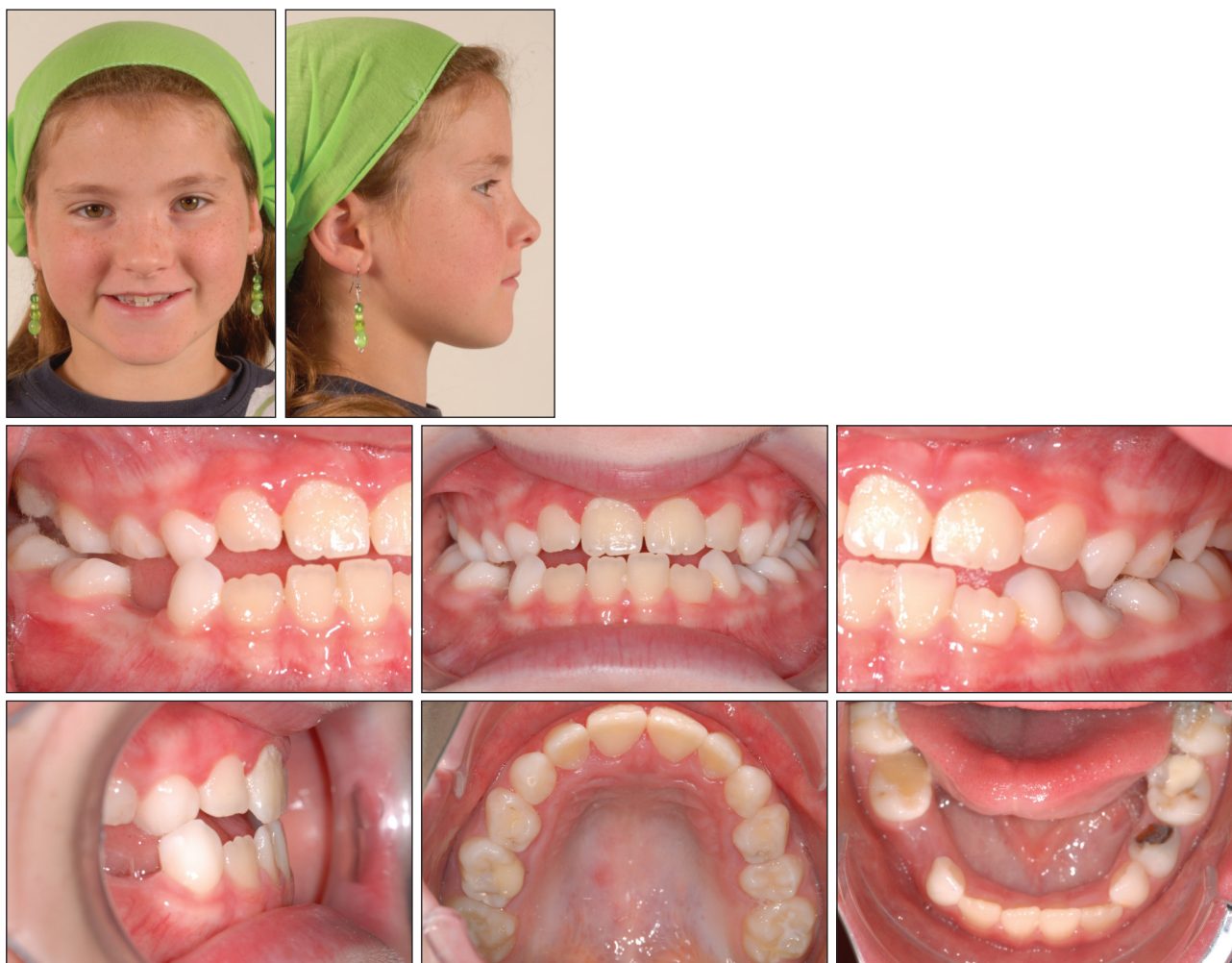

Figure 5. Pretreatment photographs of a female patient treated with the Hybrid Hyrax-Mentoplate protocol from the present study.

compared with the HH-facemask protocol, it could benefit children who prefer to have an intra-oral elastic force over the bulkiness of the extra-oral facemask.

Reports of maxillary orthopaedic protraction using skeletal anchorage and intra-oral forces are rare in contemporary orthodontic literature. Three-dimensional imaging studies by De Clerck and co-workers have shown that bone-anchored maxillary protraction stimulates forward displacement and modelling of the maxillary and zygomatic bones as well as affecting mandibular shape.^{21,22} It was evident that the treated groups in the present study and those of De Clerck et al.⁹ were similar in relation to age at commencement and pretreatment Wits value. However, a slightly higher improvement in Wits value of 4 mm was reported by De Clerck et al. at the end of treatment (3.4 ± 2.7 mm). It may be argued that the difference in Wits improvement between

the two studies is negligible and could have been due to variations in the sample size, demographics, compliance or the measurements obtained on three-dimensional images compared with two-dimensional imaging. An advantage of the HH-Mentoplate protocol is that only one surgical miniplate is inserted rather than four miniplates in the studies reported by De Clerck et al.^{9,10} The Mentoplate may be surgically inserted at younger ages because it does not encroach upon the developing mandibular canines due to its anterior and subapical placement. Additionally, the HH component of the HH-Mentoplate combination provides versatility when rapid palatal expansion is desired and can be performed simultaneously during protraction. Masucci et al.²³ and Wilmes et al.¹⁶ reported increased maxillary advancement when using the Alt-RAMEC protocol (alternating rapid maxillary expansion and constriction) with a facemask

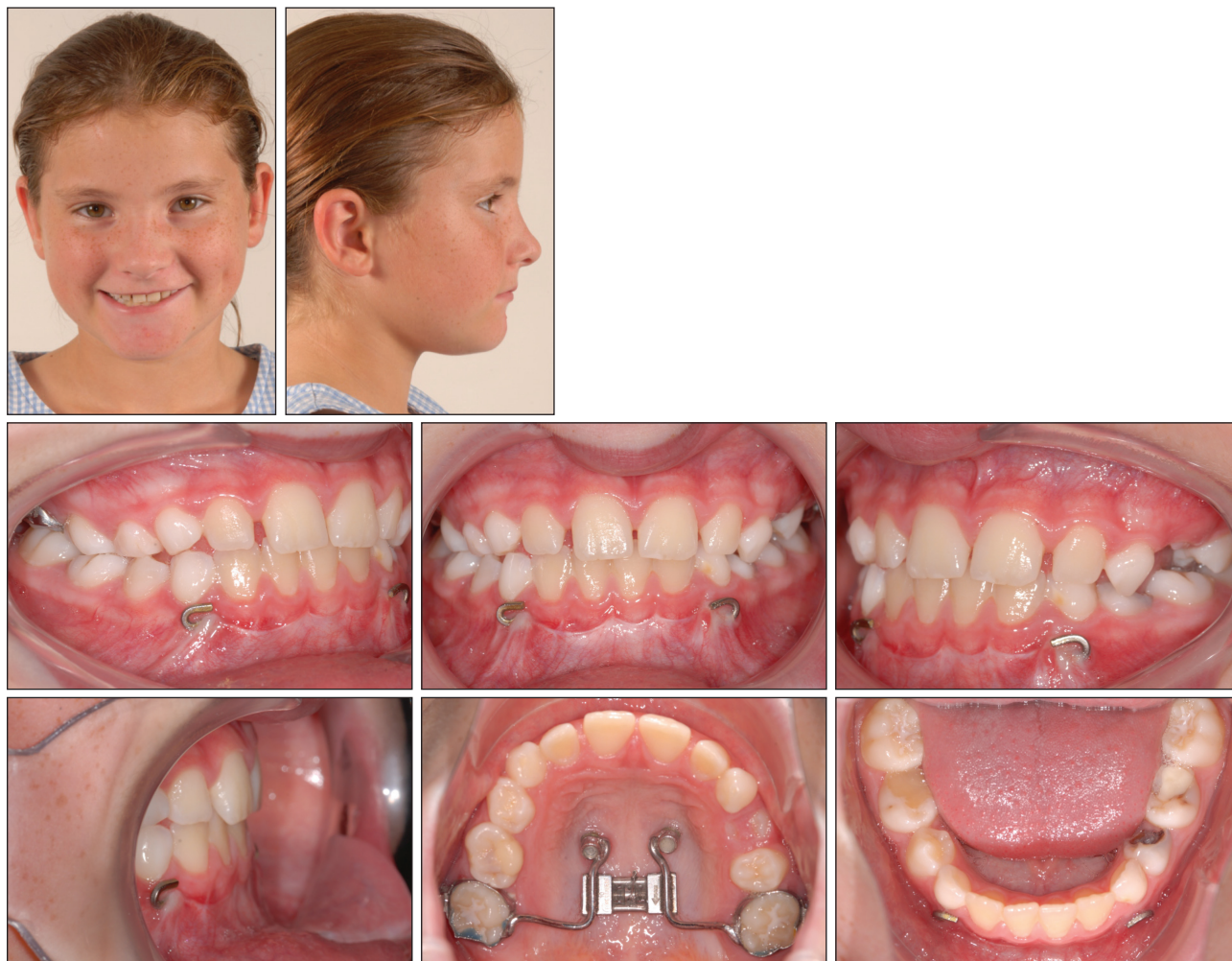

Figure 6. Post-treatment photographs of a female patient treated with the Hybrid Hyrax-Mentoplate protocol from the present study.

in comparison with a conventional RPE-facemask protocol and untreated controls.

Growth studies of untreated Class III malocclusions are rare in the literature and most are historical in nature. However, a relatively recent, semi-longitudinal study with a large Caucasian-based sample size has indicated that, on average, untreated Class III malocclusions worsen with age.²⁴ Hence, once a Class III growth pattern is established, it rarely self-corrects without dentofacial orthopaedics or orthognathic surgery.

In agreement with previously reported studies,^{25,26} the presented protocol failed to find any significant changes in the linear dimension of the nasopharyngeal airway at the adenoidal level. Interestingly, Lee et al.²⁷ reported an approximate increase of 1.4 mm in the sagittal dimension of the nasopharyngeal airway following maxillary protraction with a facemask. This

may have been due to different characteristics of the examined sample compared with the subjects of the present study.

No complications or failures in relation to the HH-Mentoplate appliance protocol were reported for any of the patients, which suggested good compliance and acceptability. Pre- and post-treatment photographs of a patient treated with the HH-Mentoplate from the present study are shown in Figure 5 and 6.

Limitations

A limitation of the present study relates to its retrospective design, although attempts were made to include all consecutively treated cases along with the availability of T1 and T2 radiographs. Although 15 consecutive patients had been treated with the HH-Mentoplate protocol at the university hospital,

one patient was excluded due to migration out of the area and unavailability of the T2 radiograph.

Additional limitations include the small sample size, relatively short longitudinal follow-up and reliance on lateral cephalograms for treatment efficacy. Most cephalometric measurements have inherent problems with landmark identification, measurement errors and the representation of three-dimensional anatomical patterns by two-dimensional analyses.²⁸ Nevertheless, the lateral cephalogram is a valid radiograph for orthodontic screening and diagnosis with a lower radiation dose in comparison with computed tomography.²⁹ To overcome some of the errors that are inherent when analysing a lateral cephalogram, only one author (VK) digitised all radiographs in a standardised manner and the error of the method indicated that intra-examiner reliability was acceptable.

Future research directions

Future research aims to focus on increasing the current sample size and to compare treatment efficacy of the HH-Mentoplate Class III protocol with that of a conventional Class III treatment and matched untreated controls. Additionally, an extended follow-up is desired due to challenges reported with long-term maintenance of the results and re-establishment of an initial unfavourable growth pattern.^{4,30} It may also be beneficial to acquire three-dimensional study models or intra-oral scans for the assessment of changes after the RPE phase of the HH-Mentoplate protocol. Future studies should also report on patient compliance, pain perception and complications.

Masucci et al.,²³ utilising a conventional RPE device, facemask and the Alt-RAMEC protocol in the early treatment of Class III malocclusion, reported enhanced sagittal maxillary protraction when compared with a conventional protocol. It may be hypothesised that the HH-Mentoplate with an Alt-RAMEC protocol could provide even greater efficacy and efficiency in the early treatment of a Class III malocclusion.²⁴ However, a controlled clinical study with a larger sample size is required to test the study hypothesis.

Conclusion

The HH-Mentoplate Class III treatment protocol produced a mean Wits improvement of 3.4 mm in

the sagittal base discrepancy between maxilla and mandible at the functional occlusal level. This was primarily achieved by sagittal maxillary skeletal protraction with negligible effects on the mandible, facial vertical dimension and the incisor angulations. A controlled clinical study with a larger sample size and longer follow-up times is needed.

Corresponding author

Dr Vandana Katyal or Professor Dieter Drescher
Department of Orthodontics
The University of Düsseldorf
Moorenstrasse 5, 40225
Düsseldorf
Germany

Email: vandykatyal@gmail.com /
d.drescher@uni-duesseldorf.de

Acknowledgments

We thank the Australian Society of Orthodontists Foundation for Research and Education (ASOFRE) for their guidance and financial support granted towards the author Dr. Vandana Katyal.

References

1. Litton SF, Ackermann LV, Isaacson RJ, Shapiro BL. A genetic study of class III malocclusion. *Am J Orthod* 1970;58:565-77.
2. Ellis E 3rd, McNamara JA Jr. Components of adult class III malocclusion. *J Oral Maxillofac Surg* 1984;42:295-305.
3. Sugawara J, Mitani H. Facial growth of skeletal class III malocclusion and the effects, limitations, and long-term dentofacial adaptations to chin cap therapy. *Semin Orthod* 1997;3:244-54.
4. Mandall N, Cousley R, DiBiase A, Dyer F, Littlewood S, Mattick R et al. Is early Class III protraction facemask treatment effective? A multicentre, randomized, controlled trial: 3-year follow-up. *J Orthod* 2012;39:176-85.
5. Williams MD, Sarver DM, Sadowsky PL, Bradley E. Combined rapid maxillary expansion and protraction facemask in the treatment of Class III malocclusions in growing children: a prospective long-term study. *Semin Orthod* 1997;3:265-74.
6. Kokich VG, Shapiro PA, Oswald R, Koskinen-Moffett L, Clarren SK. Ankylosed teeth as abutments for maxillary protraction: a case report. *Am J Orthod* 1985;88:303-7.
7. Cha BK, Choi DS, Ngan P, Jost-Brinkmann PG, Kim SM, Jang IS. Maxillary protraction with miniplates providing skeletal anchorage in a growing Class III patient. *Am J Orthod Dentofacial Orthop* 2011;139:99-112.
8. Singer SL, Henry PJ, Rosenberg I. Osseointegrated implants as an adjunct to facemask therapy: a case report. *Angle Orthod* 2000;70:253-62.
9. De Clerck H, Cevidanes L, Baccetti T. Dentofacial effects of bone-anchored maxillary protraction: a controlled study of consecutively treated Class III patients. *Am J Orthod Dentofacial Orthop* 2010;138:577-81.

10. Wilmes B, Nienkemper M, Ludwig B, Kau CH, Drescher D. Early Class III treatment with a hybrid hyrax-mentoplate combination. *J Clin Orthod* 2011;45:15-21.
11. Baccetti T, De Clerck HJ, Cevidanes LH, Franchi L. Morphometric analysis of treatment effects of bone-anchored maxillary protraction in growing Class III patients. *Eur J Orthod* 2011;33:121-5.
12. McNamara JA, Baccetti T, Franchi L, Herberger TA. Rapid maxillary expansion followed by fixed appliances: a long-term evaluation of changes in arch dimensions. *Angle Orthod* 2003;73:344-53.
13. Baccetti T, McGill JS, Franchi L, McNamara JA Jr, Tollaro I. Skeletal effects of early treatment of Class III malocclusion with maxillary expansion and face-mask therapy. *Am J Orthod Dentofacial Orthop* 1998;113:333-43.
14. Vaughn GA, Mason B, Moon HB, Turley PK. The effects of maxillary protraction therapy with or without rapid palatal expansion: a prospective, randomized clinical trial. *Am J Orthod Dentofacial Orthop* 2005;128:299-309.
15. Ludwig B, Baumgaertel S, Zorkun B, Bonitz L, Glasl B, Wilmes B et al. Application of a new viscoelastic finite element method model and analysis of miniscrew-supported hybrid hyrax treatment. *Am J Orthod Dentofacial Orthop* 2013;143:426-35.
16. Wilmes B, Ngan P, Liou EJ, Franchi L, Drescher D. Early Class III facemask treatment with the Hybrid Hyrax and Alt-RAMEC protocol. *J Clin Orthod* 2014;48:84-93.
17. Wilmes B, Nienkemper M, Drescher D. Application and effectiveness of a new mini-implant- and tooth-borne rapid palatal expansion device: the hybrid hyrax. *World J Orthod* 2010;11:323-30.
18. Wilmes B, Drescher D. A miniscrew system with interchangeable abutments. *J Clin Orthod* 2008;42:574-80.
19. Jäger A, Braumann B, Kim C, Wahner S. Skeletal and dental effects of maxillary protraction in patients with angle class III malocclusion. A meta-analysis. *J Orofac Orthop* 2001;62:275-84.
20. Nienkemper M, Wilmes B, Pauls A, Drescher D. Maxillary protraction using a hybrid hyrax-facemask combination. *Prog Orthod* 2013;14:5.
21. De Clerck H, Nguyen T, de Paula LK, Cevidanes L. Three-dimensional assessment of mandibular and glenoid fossa changes after bone-anchored Class III intermaxillary traction. *Am J Orthod Dentofacial Orthop* 2012;142:25-31.
22. Nguyen T, Cevidanes L, Cornelis MA, Heymann G, de Paula LK, De Clerck H. Three-dimensional assessment of maxillary changes associated with bone anchored maxillary protraction. *Am J Orthod Dentofacial Orthop* 2011;140:790-8.
23. Masucci C, Franchi L, Giuntini V, Defraia E. Short-term effects of a modified Alt-RAMEC protocol for early treatment of Class III malocclusion: a controlled study. *Orthod Craniofac Res* 2014;17:259-69.
24. Baccetti T, Reyes B, McNamara JA Jr. Craniofacial changes in Class III malocclusion as related to skeletal and dental maturation. *Am J Orthod Dentofacial Orthop* 2007;132:171.e1-e12.
25. Mucedero M, Baccetti T, Franchi L, Cozza P. Effects of maxillary protraction with or without expansion on the sagittal pharyngeal dimensions in Class III subjects. *Am J Orthod Dentofacial Orthop* 2009;135:777-81.
26. Baccetti T, Franchi L, Mucedero M, Cozza P. Treatment and post-treatment effects of facemask therapy on the sagittal pharyngeal dimensions in Class III subjects. *Eur J Orthod* 2010;32:346-50.
27. Lee JW, Park KH, Kim SH, Park YG, Kim SJ. Correlation between skeletal changes by maxillary protraction and upper airway dimensions. *Angle Orthod* 2011;81:426-32.
28. Houston WJ, Maher RE, McElroy D, Sherriff M. Sources of error in measurements from cephalometric radiographs. *Eur J Orthod* 1986;8:149-51.
29. Mah JK, Danforth RA, Bumann A, Hatcher D. Radiation absorbed in maxillofacial imaging with a new dental computed tomography device. *Oral Surg Oral Med Oral Pathol Oral Radiol Endod* 2003;96:508-13.
30. Wells AP, Sarver DM, Proffit WR. Long-term efficacy of reverse pull headgear therapy. *Angle Orthod* 2006;76:915-22.