

Cephalometric assessment of soft tissue morphology of patients with acromegaly

Nehir Canigur Bavbek,* Burcu Balos Tuncer,* Cumhuri Tuncer,* Kahraman Gungor,† Cigdem Ozkan,+ Emre Arslan,+ Alev Eroglu Altinova,+ Mujde Akturk+ and Fusun Balos Toruner+

Department of Orthodontics, Faculty of Dentistry,* Department of Oral and Dentomaxillofacial Radiology, Faculty of Dentistry† and Department of Endocrinology and Metabolism, Faculty of Medicine,+ Gazi University, Ankara, Turkey

Aim: To assess the sagittal soft tissue morphology of patients with acromegaly in comparison with a healthy control group.

Methods: Twenty-seven patients with acromegaly (11 male, 16 female; mean age 47.3 ± 11.5 years) and 30 healthy subjects (15 male, 15 female; mean age 42.2 ± 17.4 years) were included in the study. Linear and angular measurements were made on lateral cephalograms to evaluate soft tissue and skeletal characteristics. The intergroup comparisons were analysed with the Student's *t*-test.

Results: Facial convexity ($p < 0.01$) and the nasolabial angle ($p < 0.001$) were reduced in patients with acromegaly, whereas nose prominence ($p < 0.01$), upper lip sulcus depth ($p < 0.01$), upper lip thickness ($p < 0.01$), basic upper lip thickness ($p < 0.01$), lower lip protrusion ($p < 0.05$), mentolabial sulcus depth ($p < 0.05$) and soft tissue chin thickness ($p < 0.001$) were increased. Anterior cranial base length ($p < 0.05$), the supraorbital ridge ($p < 0.01$), the length of the maxilla and mandible ($p < 0.001$, $p < 0.01$, respectively) were significantly increased, and mandibular prognathism was an acromegalic feature ($p < 0.05$).

Conclusion: Acromegalic coarsening and thickening of the craniofacial soft tissues was identified from lateral cephalograms, which may therefore contribute to early diagnosis when evaluated together with other changes caused by the disease.

(Aust Orthod J 2016; 32: 48–54)

Received for publication: August 2015

Accepted: February 2016

Nehir Canigur Bavbek: ncanigur@yahoo.com; Burcu Balos Tuncer: burcubalostuncer@yahoo.com; Cumhuri Tuncer: cumhurtu@yahoo.co.uk; Kahraman Gungor: kahraman@gazi.edu.tr; Cigdem Ozkan: cozkan34@hotmail.com; Emre Arslan: emarslan@gmail.com; Alev Eroglu Altinova: alevaltinova@yahoo.com; Mujde Akturk: mujdeakturk@hotmail.com; Fusun Balos Toruner: fusunbalostoruner@yahoo.com

Introduction

Acromegaly is a rare and complicated disease caused by the overproduction of growth hormone (GH) usually due to a pituitary somatotrophic adenoma. Although its prevalence is uncertain, published numbers show an estimated prevalence of 36–60 cases per 1,000,000 population with an annual incidence of three to four new cases per 1,000,000 population each year.^{1,2} As the tumour expands, GH production becomes excessive and persistent, which leads to facial changes, acral growth, soft tissue, bone and organ enlargements, as well as impaired glucose tolerance, hypertension, colonic polyps and sleep apnoea.^{3,4} The clinical manifestations

of acromegaly develop very slowly, and healthcare professionals often fail to recognise the disease until changes in facial features and extremities become profound. This usually results in four to eight years of delay in diagnosis.⁵ Early diagnosis and treatment is important, since acromegaly increases premature mortality when compared with healthy adults.⁶

Since the complications due to acromegaly may be confused with other common disorders, patients typically visit a number of healthcare providers prior to diagnosis.⁵ Therefore, improving educational programs for carers likely to encounter the disease is crucial.^{5,7} Currently, the education of orthodontists regarding

the clinical and radiographic features of acromegaly is important since they might be the first consultants to detect the disease. As a previous study determined, 7% of patients with acromegaly are diagnosed by dentists,⁵ and some patients may be referred to an orthodontist due to a recent exacerbation in a malocclusion.^{8,9}

Several articles have emphasised the vertical and sagittal changes in craniofacial bony features in patients presenting with acromegaly.⁹⁻¹² In addition, coarsening and thickening of soft tissues are as important as skeletal structural change in producing the characteristic appearance, and so an evaluation of the sagittal soft tissues can assist identification. However, detailed analyses of soft tissue profile changes in patients with acromegaly are limited. Therefore, the purpose of the present study was to assess the sagittal soft tissue morphology in patients with acromegaly and provide a comparison with a healthy control group.

Materials and methods

The study was approved by the Ethics Committee of Gazi University, Ankara, Turkey. All participants were informed and written consent was obtained. The investigation was performed by adding new patients with acromegaly and control subjects to a previous study group.¹³ Twenty-seven patients with acromegaly (11 male, 16 female; mean age 47.3 ± 11.5 years) who attended the Department of Endocrinology and Metabolism in Gazi University Faculty of Medicine were identified and included. The disease duration was 5.9 ± 6.3 years. All patients had undergone trans-sphenoidal surgery and, if required, received somatostatin analog therapy.

A control group consisted of 30 healthy individuals (15 male, 15 female; mean age 42.2 ± 17.4 years), who received a cephalometric assessment for either a pre-orthodontic evaluation, planning an implant placement and/or occlusal plane reconstructions. All subjects were of Caucasian ethnicity, had no chronic disease, no craniofacial anomaly, and were without any previous orthodontic treatment history. All were fully informed that their radiographs would be used for research purposes.

Cephalometric measurements

All lateral cephalometric radiographs were taken in natural head position, in maximal dental

intercuspatation with the lips in repose, using an Orthophos XG 5 DS/Ceph; Sirona Dental System (Bensheim, Germany; C3 30 × 23, at 200–240 V, 12 mA) by a single technician. The distance from the focus of the radiographic device to the midsagittal plane of the patient was 150 cm and the distance from the film to the midsagittal plane was 20 cm. The measurements obtained from the cephalograms were adjusted to avoid the effects of magnification. All radiographs were traced, measured and evaluated by the same researcher, blinded to the group allocation and names of the patients.

Four linear and four angular measurements were made on lateral cephalograms to evaluate the skeletal morphology of the participants. The assessment of facial form and soft tissues was generated from fourteen linear, four angular and two ratio evaluations, using the following reference lines: a line through nasion (N) and seven degrees up from sella-nasion line (HP), perpendicular to HP (HP+), Frankfort horizontal plane (FH), tangent from the tip of the soft tissue chin to the upper lip (H line), a line from soft tissue nasion to soft tissue chin (soft tissue facial plane), and a line through hard tissue nasion (N) to hard tissue pogonion (Pg) (hard tissue facial plane).^{14,15} Definitions of linear and angular measurements are provided in Table I. Cephalometric landmarks and reference planes are illustrated in Figure 1.

Statistical analysis

Data were analysed with the Statistical Package for Social Sciences SPSS Version 21.0 (SPSS Inc., IL, USA). Numerical variables were presented as means (SD). The normality of data was assessed by the Shapiro-Wilks test, and the Student's *t*-test was used to evaluate differences between the groups. $P < 0.05$ was considered to be statistically significant.

Results

The mean body mass index (BMI) of patients with acromegaly was 30.53 ± 5.69 kg/m², and 29.60 ± 4.03 kg/m² in control subjects. There was no statistically significant difference in age and BMI between the groups. The skeletal and soft tissue characteristics of patients with acromegaly and the control group, and the differences between the groups, are provided in Table II.

Table 1. Definitions of linear and angular measurements made on lateral cephalograms.

	Definition
<i>Skeletal morphology – linear</i>	
S-N	Anterior cranial base length
S-G	Supraorbital ridge protrusion
ANS-PNS	The length of the maxilla
Go-Gn	The length of the mandible
<i>Skeletal morphology – angular</i>	
SNA°	The sagittal position of the maxilla in relation to S-N
SNB°	The sagittal position of the mandible in relation to S-N
ANB°	Sagittal maxillo-mandibular relation
Sn/GoGn°	Mandibular plane angle
<i>Facial form</i>	
G-Sn-Pg°	Facial convexity angle
G-Sn-HP	Maxillary prognathism
G-Pg'-HP	Mandibular prognathism
G-Sn/Sn-Me' on HP+	The vertical height ratio
<i>Soft tissue positions and forms</i>	
Nose prominence	Distance between the tip of the nose and a perpendicular line drawn to the FH plane from vermillion
Cm-Sn-Ls°	Nasolabial angle
Ls to Sn-Pg'	Upper lip protrusion
Upper lip sulcus depth	Distance between the upper lip sulcus and a perpendicular line drawn from the vermillion to FH
Upper lip thickness	Distance between the vermillion point and the labial surface of the maxillary incisor
Basic upper lip thickness	Distance measured approximately 3 mm below A point and upper lip
Upper lip strain	The difference between upper lip thickness and basic upper lip thickness
Li to Sn-Pg'	Lower lip protrusion
Si to Sn-Pg'	Mentolabial sulcus depth
Inferior sulcus depth	Measurement at the point of greatest convexity between the vermillion border of the lower lip and H line
Soft tissue chin thickness (Pg-Pg')	Distance between the hard and soft tissue facial planes at the level of suprapogonion
Soft tissue facial angle	The downward and inner angle between FH and soft tissue facial line from N' to Pg'
Sn'-H line	Soft tissue subnasale to H line
Li-H line	Lower lip to H line
Holdaway angle (H angle)	Angle between the soft tissue facial line (N'-Pg') and H line
Sn-Stms/Stmi-Me' on HP+	Vertical lip-chin ratio

Differences in skeletal morphology

Anterior cranial base length (S-N; $p < 0.05$) increased, the supraorbital ridge (S-G; $p < 0.01$) was more protrusive, maxillary (ANS-PNS; $p < 0.001$) and mandibular lengths (Go-Gn; $p < 0.01$) increased in patients with acromegaly compared with controls. The ANB angle showing the sagittal relationship of the jaws was smaller in patients with acromegaly ($p < 0.05$).

Differences in facial form

Facial convexity (G-Sn-Pg', $p < 0.01$) was reduced and mandibular prognathism (G-Pg'-HP; $p < 0.05$) increased in patients with acromegaly.

Differences in soft tissue position and form

The nose was more prominent ($p < 0.01$) and the nasolabial angle (Cm-Sn-Ls; $p < 0.001$) was significantly lower in patients with acromegaly when

Table II. Skeletal and soft tissue cephalometric variables and comparisons between the two groups.

Variables	Acromegaly group		Control group		
	Mean	SD	Mean	SD	<i>p</i>
<i>Skeletal morphology</i>					
S-N (mm)	76.81	4.02	74.21	4.17	0.020*
S-G (mm)	84.72	5.55	80.33	3.96	0.001**
ANS-PNS (mm)	59.14	4.95	54.66	3.14	0.000***
Go-Gn (mm)	86.18	7.07	80.96	5.56	0.003**
SNA (°)	80.7	4.12	80.96	3.42	NS
SNB (°)	79.11	4.53	77.15	3.45	NS
ANB (°)	1.44	4.9	3.81	2.05	0.019*
SN-Go-Gn (°)	34.96	5.9	33.13	6.5	NS
<i>Facial form</i>					
Facial convexity angle, G-Sn-Pg' (°)	8.92	6.48	14.6	6.78	0.002**
Maxillary prognathism (G-Sn-HP) (mm)	3.87	4.86	5.31	4.06	NS
Mandibular prognathism (G-Pg'-HP) (mm)	-1.1	9.24	-4.38	9.71	0.012*
Vertical height ratio (G-Sn/Sn-Me' on HP+)	1.00	0.12	1.06	0.11	NS
<i>Soft tissue position and form</i>					
Nose prominence (mm)	21.92	3.97	18.46	3.43	0.001**
Nasolabial angle (Cm-Sn-Ls) (°)	97.61	14.76	111.06	10.71	0.000***
Upper lip protrusion (Ls to Sn-Pg') (mm)	4.51	3.38	3.2	1.99	NS
Upper lip sulcus depth (mm)	3.6	2.23	2.01	1.07	0.001**
Upper lip thickness (mm)	14.62	4.09	11.9	2.5	0.003**
Basic upper lip thickness (mm)	16.4	3.75	14.3	1.57	0.007**
Upper lip strain (mm)	2.25	1.6	2.8	1.29	NS
Lower lip protrusion (Li to Sn-Pg') (mm)	5.2	4.15	3.08	2.38	0.020*
Mentolabial sulcus depth (Si to Li-Pg') (mm)	6.79	2.69	5.56	1.52	0.037*
Inferior sulcus depth (mm)	5.83	3.04	5.35	1.85	NS
Soft tissue chin thickness (Pg-Pg') (mm)	16.51	3.4	13.06	2.27	0.000***
Soft tissue facial angle (FH-N'-Pg') (°)	89.5	5.35	89.76	5.14	NS
Soft tissue subnasale to H line (Sn'-H line) (mm)	6.58	4.32	4.81	2.43	NS
Lower lip to H line (Li-H) (mm)	2.74	3.11	1.51	1.62	NS
H angle (N'-Pg'-FH) (°)	11.48	6.48	13.4	4.89	NS
Vertical lip-chin ratio (Sn-Stms/Stmi-Me') (HP+)	0.45	0.08	0.46	0.07	NS

HP, line through N, 7° up from S-N; HP+, perpendicular to HP; FH, Frankfurt horizontal plane;

SD, Standard deviation; **p* < 0.05; ***p* < 0.01; ****p* < 0.001; *p* > 0.05; NS, *p* > 0.05.

compared with controls. Upper lip sulcus depth (*p* < 0.01), upper lip thickness (*p* < 0.01), basic upper lip thickness (*p* < 0.01), lower lip protrusion (*p* < 0.05), mentolabial sulcus depth (*p* < 0.05) and soft tissue chin thickness (*p* < 0.001) were greater in the acromegalic group.

Discussion

Acromegaly is characterised by skin and soft tissue changes due to increased GH levels, and reports have emphasised the craniofacial changes.¹⁶⁻¹⁸ Most previous literature explored the skeletal changes in the craniofacial region, but excessive GH and IGF-1 were

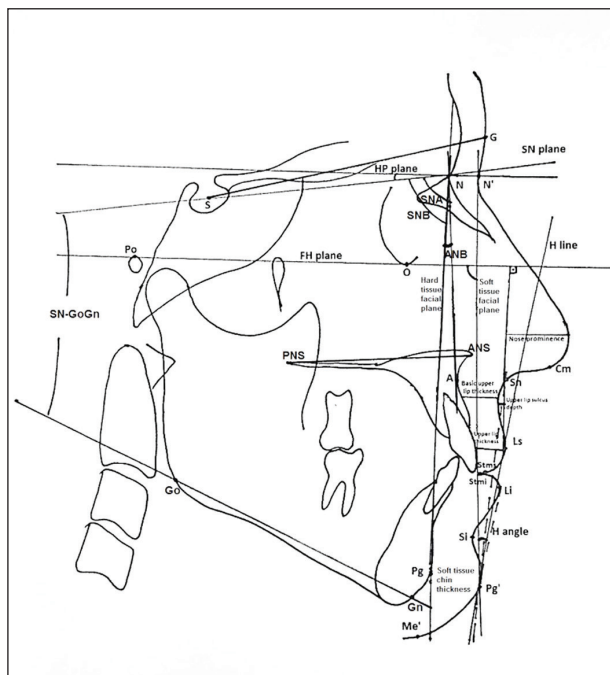


Figure 1. Cephalometric landmarks and reference planes: (1) S, midpoint of sella turcica; (2) N, anterior point at nasofrontal suture; (3) Po, most superior point of external auditory meatus; (4) O, most inferior point of the orbit; (5) A, deepest point in concavity of anterior maxilla; (6) ANS, most anterior point of anterior nasal spine; (7) PNS, most posterior point of nasal spine; (8) Go, point constructed by bisecting the posterior and inferior borders of the mandible; (9) Me, most inferior point of bony chin; (10) Pg, most anterior point of bony chin; (11) Gn, most anterior-inferior point of bony chin; (12) G, the most prominent point in the midsagittal plane of supraorbital ridge; (13) N', soft tissue nasion, the most concave point in the tissue overlying the area of the frontonasal suture; (14) Cm, columella, the most anterior soft tissue point on the columella (nasal septum) of the nose; (15) Sn, subnasale, the point at which the columella merges with the upper lip in the midsagittal plane; (16) Ls, labrale superius, most anterior point on the upper lip; (17) Stms, stomion superius, lower most point on vermillion of upper lip; (18) Li, labrale inferius, most anterior point on the lower lip; (19) Stmi, stomion inferius, upper most point on vermillion of lower lip; (20) Si, sulcus inferius, the point of greatest concavity in the midline of the lower lip between the labiale inferius and the soft tissue pogonion; (21) Pg', soft tissue pogonion, the most anterior point on the soft tissue chin; (22) Me', soft tissue menton, the most inferior point on the soft tissue chin; (23) HP, horizontal reference line constructed by raising a line 7 degree from S-N plane; (24) FH, reference line through Po and O; (25) Hard tissue facial plane, line from N to Pg; (26) Soft tissue facial plane, line from N' to Pg'; (27) H line, line drawn tangent to the soft tissue chin and upper lip.

proved to act on soft tissues and organs as well as bones.³ However, the recognition of the disease is made easier by patients and others following the characteristic facial changes, which reflect the underlying bones and soft tissues. Correspondingly, a detailed soft tissue analysis in lateral cephalograms was considered beneficial in interpreting the effects of acromegaly. The dominant role of BMI in the alteration of facial soft tissue thickness has been confirmed previously.¹⁹ However, there was no significant difference

in BMI between the groups involved in the present study. Therefore, the detected soft tissue changes could be attributed to the effects of the disease.

Acromegaly may remain undetected for years, and it is imperative that clinical recognition should be improved by health workers.⁵ Therefore, detecting acromegalic facial soft tissue changes may be beneficial for early diagnosis. Initial attempts were aimed at the creation of a computer program which formed three-dimensional (3D) models of the face from two-dimensional (2D) photographs.^{20,21} With time, Schneider et al.²² introduced face classification software based on pre-determined points and nodes located on frontal and side view photographs, in order to detect the presence and severity of the disease. The results specifically mentioned that the inclusion of side views improved the identification of affected patients. Although the diagnosis of the disease improved, there was no quantifiable change described in the soft tissues as a result of the disease. To address this issue, Wagenmakers et al.¹⁷ used 3D cone-beam computed tomography (CBCT) scans and 3D stereophotographs of patients suffering from acromegaly and found that they had larger soft tissues in all dimensions when compared with control subjects. Although 3D evaluation is preferred for a more realistic analysis of the craniofacial region, there are no data regarding the radiation risk of a CBCT assessment of acromegalic patients to determine the value of the procedure. In addition, the effective dose of CBCT scans can be anywhere from 68–1073 micro-Sieverts (μSv)²³ while the effective dose of a cephalometric radiograph is estimated to be 1.7–3.4 μSv ,²⁴ which raises further questions about the appropriateness of CBCT scans to evaluate the craniofacial effects of acromegaly. Access to 3D modelling software and CBCTs is limited. Detailed soft tissue analysis performed on traditional cephalometric radiographs is an acceptable, reliable, attainable and cheaper diagnostic tool for the identification of the disease. Therefore, the present results may be beneficial for the early diagnosis of acromegaly since the data reflect possible common facial features.

Acromegalic patients show a thickening of the skin as a result of hypertrophy of collagen fibres caused by the excess of GH.¹⁷ The hypertrophy is not fully reversible and persists²⁵ and is an important consideration for joint and cartilage integrity.¹⁷ For this reason, changes in facial structures are a vital key in the self-detection of acromegaly or its detection by healthcare workers.⁵

The present results indicated the deformation in craniofacial soft tissues due to the disease. The nose was more prominent and upper lip thickness increased, which resulted in a decreased nasolabial angle and increased upper lip sulcus depth. A more protruded lower lip and an increased soft tissue chin thickness caused the mentolabial sulcus to be deeper. Reid et al.⁵ presented a clinical review of neurosurgeons and personal interviews with patients at diagnosis, and reported that facial feature change related to soft tissue coarsening, deepening of nasolabial folds, thickening of soft tissues and enlargement of lips and nose were the main complaints by patients, which therefore assisted diagnosis. Wagenmakers et al.¹⁷ also found that the nose and lips were enlarged in these patients. The present radiological data support and are consistent with the clinical observations of Reid et al.⁵ and the 3D data of Wagenmakers et al.¹⁷ and demonstrate the soft tissue changes caused by the disease more objectively and more easily.

The increase in supraorbital ridge protrusion and soft tissue chin thickness were also significant in the present patient cohort when compared with the healthy controls. The changes were attributed to signs of soft tissue thickening due to the hormonal excess. Facial convexity was reduced in acromegalic patients, in comparison with healthy controls, and this might be secondarily related to the protrusion of the supraorbital ridge and marked frontal bossing as well as the increase in soft tissue chin thickness in affected patients. Although not evaluated, an enlargement in the frontal sinus was a common cephalometric finding. In a smaller previous study evaluating the hard tissue changes caused by acromegaly, it was indicated that a significant enlargement in frontal sinus width occurred,¹³ which was confirmed by Karakis et al.¹⁰ and Dostálová et al.¹⁶

The present results revealed no difference between acromegaly and control groups in sagittal intermaxillary position, but the length of the maxilla and mandible were significantly increased, and mandibular protrusion was more prominent in the acromegalic group. The changes were also revealed by lower ANB values, which may reflect the mandibular prognathism tendency in affected patients. It was well identified by previous reports that due to periosteal bone apposition and profound growth in the condyle and ramus, mandibular prognathism is a feature of most patients suffering from acromegaly.^{11,26} However, it should

be noted that bone apposition is not specific to the mandible, but in the maxilla as well. There are contradicting reports suggesting that maxillary bone is minimally affected by the disease and that changes in mandibular dimensions are more prominent.^{16,18} The present results are in accordance with Wagenmakers et al.,¹⁷ who found increased maxillary and mandibular lengths, without any difference in the sagittal position and relationship of the jaws in acromegaly patients compared with controls. A possible explanation may be the elongation of the anterior cranial base in affected patients, which masks the actual intergroup differences in maxillary and mandibular lengths.^{16,27}

Conclusion

The craniofacial soft tissues of the patients assessed in the present study showed coarsening and thickening due to acromegaly. The nose, lips and chin were more prominent. As a result, facial convexity and the nasolabial angle were significantly lower in affected patients compared with controls. Maxillary and mandibular lengths were increased and the acromegalic mandible was prognathic. Early diagnosis is the key for treatment success and so clinicians should have a solid understanding of the soft tissue changes caused by the disease. The results of the present study support the clinical subjective examination with objective measurements performed on radiographs to confirm a diagnosis. Together with a clinical examination, a cephalometric assessment may be beneficial for improved diagnosis and data sharing of patients affected by acromegaly.

References

1. Holdaway IM, Rajasoorya C. Epidemiology of acromegaly. *Pituitary* 1999;2:29-41.
2. Mestron A, Webb SM, Astorga R, Benito P, Catala M, Gaztambide S et al. Epidemiology, clinical characteristics, outcome, morbidity and mortality in acromegaly based on the Spanish Acromegaly Registry (Registro Espanol de Acromegalia, REA). *Eur J Endocrinol* 2004;151:439-46.
3. Jane JA Jr, Thapar K, Laws ER Jr. Acromegaly: historical perspectives and current therapy. *J Neurooncol* 2001;54:129-37.
4. Fukuda I, Hizuka N, Muraoka T, Kurimoto M, Yamakado Y, Takano K et al. Clinical features and therapeutic outcomes of acromegaly during the recent 10 years in a single institution in Japan. *Pituitary* 2014;17:90-5.
5. Reid TJ, Post KD, Bruce JN, Nabi Kanibir M, Reyes-Vidal CM, Freda PU. Features at diagnosis of 324 patients with acromegaly did not change from 1981 to 2006: acromegaly remains under-recognized and under-diagnosed. *Clin Endocrinol (Oxf)* 2010;72:203-8.
6. Dekkers OM, Biermasz NR, Pereira AM, Romijn JA, Vandenbroucke JP. Mortality in acromegaly: a metaanalysis. *J Clin Endocrinol Metab*

- 2008;93:61-7.
7. Iuliano SL, Laws ER Jr. Recognizing the clinical manifestations of acromegaly: case studies. *J Am Assoc Nurse Pract* 2014;26:136-42.
 8. Sugata T, Myoken Y, Tanaka S. Acromegaly identified in a patient with a complaint of malocclusion. *Oral Surg Oral Med Oral Pathol Oral Radiol Endod* 1998;85:44-6.
 9. Vitral RW, Tanaka OM, Fraga MR, Rosa EA. Acromegaly in an orthodontic patient. *Am J Orthod Dentofacial Orthop* 2006;130:388-90.
 10. Karakis D, Aktas-Yilmaz B, Dogan A, Yetkin I, Bek B. The bite force and craniofacial morphology in patients with acromegaly: a pilot study. *Med Oral Patol Oral Cir Bucal* 2014;19:e1-7.
 11. Kashyap RR, Babu GS, Shetty SR. Dental patient with acromegaly: a case report. *J Oral Sci* 2011;53:133-6.
 12. Nakano H, Mishima K, Matsushita A, Suga H, Miyawaki Y, Mano T et al. Orthognathic surgery in an acromegalic patient with obstructive sleep apnea syndrome. *Sleep Breath* 2013;17:29-32.
 13. Balos Tuncer B, Canigur Bavbek N, Ozkan C, Tuncer C, Eroglu Altinova A, Gungor K et al. Craniofacial and pharyngeal airway morphology in patients with acromegaly. *Acta Odontol Scand* 2015;73:433-40.
 14. Legan HL, Burstone CJ. Soft tissue cephalometric analysis for orthognathic surgery. *J Oral Surg* 1980;38:744-51.
 15. Gelgör IE, Karaman AI, Zekiç E. The use of parental data to evaluate soft tissues in an Anatolian Turkish population according to Holdaway soft tissue norms. *Am J Orthod Dentofacial Orthop* 2006;129:330 e1-9.
 16. Dostálová S, Sonka K, Smahel Z, Weiss V, Marek J. Cephalometric assessment of cranial abnormalities in patients with acromegaly. *J Craniomaxillofac Surg* 2003;31:80-7.
 17. Wagenmakers MA, Roerink SH, Maal TJ, Pelleboer RH, Smith JW, Hermus AR et al. Three-dimensional facial analysis in acromegaly: a novel tool to quantify craniofacial characteristics after long-term remission. *Pituitary* 2015;18:126-34.
 18. Künzler A, Farmand M. Typical changes in the viscerocranium in acromegaly. *J Craniomaxillofac Surg* 1991;19:332-40.
 19. De Greef S, Vandermeulen D, Claes P, Suetens P, Willems G. The influence of sex, age and body mass index on facial soft tissue depths. *Forensic Sci Med Pathol* 2009;5:60-5.
 20. Learned-Miller E, Lu Q, Paisley A, Trainer P, Blanz V, Dedden K et al. Detecting acromegaly: screening for disease with a morphable model. *Med Image Comput Comput Assist Interv* 2006;9:495-503.
 21. Miller RE, Learned-Miller EG, Trainer P, Paisley A, Blanz V. Early diagnosis of acromegaly: computers vs clinicians. *Clin Endocrinol (Oxf)* 2011;75:226-31.
 22. Schneider HJ, Kosilek RP, Günther M, Roemmler J, Stalla GK, Sievers C et al. A novel approach to the detection of acromegaly: accuracy of diagnosis by automatic face classification. *J Clin Endocrinol Metab* 2011;96:2074-80.
 23. Ludlow JB, Ivanovic M. Comparative dosimetry of dental CBCT devices and 64-slice CT for oral and maxillofacial radiology. *Oral Surg Oral Med Oral Pathol Oral Radiol Endod* 2008;106:106-14.
 24. Gijbels F, Sanderink G, Wyatt J, Van Dam J, Nowak B, Jacobs R. Radiation doses of indirect and direct digital cephalometric radiography. *Br Dent J* 2004;197:149-52.
 25. Ferguson JK, Donald RA, Weston TS, Espiner EA. Skin thickness in patients with acromegaly and Cushing's syndrome and response to treatment. *Clin Endocrinol (Oxf)* 1983;18:347-53.
 26. Chang HP, Tseng YC, Chou TM. An enlarged sella turcica on cephalometric radiograph. *Dentomaxillofac Radiol* 2005;34:308-12.
 27. Dostalova S, Sonka K, Smahel Z, Weiss V, Marek J, Horinek D. Craniofacial abnormalities and their relevance for sleep apnoea syndrome aetiopathogenesis in acromegaly. *Eur J Endocrinol* 2001;144:491-7.