

Multicentre evaluation of impacted and transmigrated canines: a retrospective study

Hakan Avsever,^{*} Kaan Gunduz,[†] Mesut Akyol⁺ and Kaan Orhan[‡]

Department of Dentomaxillofacial Radiology, Health Sciences University, Ankara,^{*} Faculty of Dentistry, Department of Dentomaxillofacial Radiology, Ondokuz Mayıs University, Samsun,[†] Department of Biostatistics, Yildirim Beyazıt University, Ankara,⁺ Faculty of Dentistry, Department of Dentomaxillofacial Radiology, Ankara University, Ankara⁺ and Faculty of Dentistry, Department of Dentomaxillofacial Radiology, Near East University, Mersin,[‡] Turkey

Objectives: The present multicentre study assessed the prevalence and patterns of impacted and transmigrated maxillary and mandibular canines in a Turkish subpopulation.

Methods: The study identified 1625 patients who had impacted teeth from a group of 10,700 patients (referred to three university hospitals between January 2014 and December 2015) and examined the accompanying records, panoramic and periapical radiographs, and cone-beam computed tomographic images (if available). An impacted canine was considered to be transmigrated when at least part of the tooth had crossed the midline.

Results: Out of 1625 patients, 163 (10.0%) had impacted canines (comprising a total of 170 affected teeth). Impacted canines were found in the maxilla in 114 patients (69.9%) and 49 patients (30.1%) showed mandibular canine impaction. Thirty-eight patients (2.3%) had transmigrated canines, of which twenty (52.6%) were located in the mandible, while 18 (47.4%) were found in the maxilla. No significant difference was evident between the genders, the site (right/left) and the impacted/transmigrated canines ($p > 0.05$). However, it was determined that canine impaction was significantly more frequent in the maxilla than in the mandible ($p < 0.05$). In addition, of the 38 patients presenting with transmigrated canines, eight (21.6%) had a history of alpha thalassemia.

Conclusions: Canine transmigration occurs in both the mandible and maxilla. The prevalence of impacted/transmigrated canines in the studied population was 10.0% and 2.3%, respectively. The mechanism of transmigration of maxillary canines remains unclear and requires further investigation. However, a possible correlation with genetic disorders (like alpha thalassemia) should not be overlooked.

(Aust Orthod J 2017; 33: 170-178)

Received for publication: August 2016

Accepted: April 2017

Hakan Avsever; hakanavsever@gmail.com; Kaan Gunduz; sementoma@hotmail.com; Mesut Akyol; mesut.akyol@gmail.com; Kaan Orhan; call52@yahoo.com

Introduction

The impaction of a permanent tooth is a frequent dental finding.¹⁻⁴ Torres-Lagares et al.⁵ defined a 'retained' tooth as one that had failed to exfoliate and its successor failed to erupt more than one year after expected emergence age. Several studies have reported the prevalence and numbers of impacted teeth, varying from 6.9% to 76.6%.³⁻⁶ If third molars are excluded, the prevalence is 5.6% to 18.8%.^{6,7} This large range is likely due to the examination of varying age groups,

the recruitment of inconsistent numbers of patients, and the use of different determination methods. The most commonly impacted teeth are the third molars and, in order, the maxillary canines, maxillary central incisors, and premolars.⁸⁻¹¹

The canines are important teeth for the establishment and maintenance of the form, function, and aesthetics of the dentition.^{12,13} Permanent canine impaction is relatively common and has been extensively reported.^{7,14-18} Impacted mandibular canines occur

less frequently compared with maxillary canines and claim a prevalence of 0.8–3.6% in the general population.^{7,14–18} Palatal impaction comprises 85% of ectopically-positioned maxillary canines.^{19,20} Moreover, in a study of 107 children with 156 ectopic maxillary canines, Ericson and Kurol²¹ found 50% were linguallly or distolingually positioned, 18% were distobuccal, and 21% were buccally related to the roots of the adjacent lateral incisor.²¹

Transmigration, defined as the crossing of an impacted tooth beyond the arch midline, is a much rarer occurrence.¹⁶ Although transmigrated mandibular canines have been reported,^{22–29} maxillary canine transmigration, first described by Aydin et al.,¹⁴ is rare, with an identified frequency of 0.1–0.34%.^{22,30} However, few studies have examined maxillary transmigrated teeth.^{14,22,26,31,32}

The use of the term transmigration is controversial. Tarsitano et al.³³ defined transmigration as the condition in which the entire length of the impacted canine had migrated across the midline, whereas Javid³⁰ suggested that only half of the length of the tooth across the midline would qualify. Although Vuchkova et al.²⁹ supported this definition, Auluck et al.²³ suggested that it is not the distance of migration that is important, but rather the tooth's tendency to cross the midline.

There are several theories regarding canine impaction, which include the ectopic position of the tooth-germ, a lack of space, a lack of eruptive guidance, or genetic factors.^{12,34–36} However, the specific aetiology of the transmigration of impacted canines remains unknown. Possible aetiological factors include trauma, heredity, a long eruption path, a loss of primary teeth, disharmony of tooth size, insufficient alveolar arch length, and odotomas.²⁶

It has been postulated that the prevalence of canine impaction varies between populations, and even between population regions.¹⁸ Numerous reports of the Turkish population have been published, yet the findings reveal considerable national variation.^{14,17,18,22,24,26,27,30,31,37–39}

Therefore, the aim of the present study was to determine the characteristics of impacted and transmigrated canines. It was intended to conduct a multicentre study to evaluate the prevalence, pattern, and demographic clinical and radiographic variables in a Turkish population.

Materials and methods

The records of 1625 patients who had impacted teeth were identified from a larger group of 10,700 patients referred to three university hospitals between January 2014 and December 2015. Periapical and panoramic radiographs of all patients were examined independently by three dentomaxillofacial radiologists, each with at least six years experience. All patients were informed about the investigation and gave their informed consent prior to the examinations according to the principles of the Helsinki Declaration, including all amendments and revisions. Collected data were noted and only accessible to the investigators.

The study was a retrospective evaluation of conventional radiographs and patient records, and also cone-beam computed tomography scans (CBCT), if available. The CBCT images were included if they were acquired to supplement conventional radiography. All evaluations were performed on a 21.3-inch flat panel color active matrix TFT medical display (Nio Color 3MP, Barco, Belgium) with a resolution of 2048 × 1536 at 76 Hz and 0.2115 mm dot pitch operated with colour supported 30 bit.

The numbers, positions, and locations (right/left) of impacted/transmigrated canines, as well as patient gender, age, retained deciduous canines, and any other associated pathology, were noted after a retrospective evaluation the patients' general histories, clinical and radiographic records.

If the patient was older than 16 years and the tooth was not visible in the oral cavity, it was classified as impacted.¹⁴ An impacted canine was considered transmigrated when at least part of its length had crossed the midline.^{16,31}

The position of a maxillary and mandibular impacted canine and the transmigration of these teeth were classified according to location (right or left) and gender, both in the maxilla and mandible (similar to Mupparapu's classification³⁸ in the mandible) according to:

Type 1: *Mesioangular* – in a mesioangularly-impacted position.

Transmigration; transmigrated across the midline within the skeletal base, labial, or lingual to the anterior teeth, and with the crown portion of the tooth crossing the midline.

Type 2: *Distoangular* – in a distoangularly-impacted position.

Transmigration; transmigrated across the midline within the skeletal base, labial, or lingual to the anterior teeth, but with the root portion of the tooth crossing the midline.

Type 3: *Horizontal* – impacted horizontally near the inferior border of the mandible or impacted horizontally below the incisor apices in both the maxilla and mandible.

Transmigration; horizontally transmigrated across the midline within the respective jaw.

Type 4: *Vertical* – positioned vertically in the midline either in the maxilla or in the mandible.

Transmigration; the tooth's long axis crossing the midline.

Type 5: *Inverted* – the canine crown facing the mandibular inferior border or nasal cavity in the maxilla (canine transposed upside-down) in the same quadrant of the respective jaw.

Type 6: *Buccolingually impacted* – impacted either buccally or lingually from its original location in the same jaw quadrant.

Statistical analysis

Statistical agreement between age-related variation and normal distribution was tested using the Shapiro-Wilk test. The descriptive statistics of age-related variables are shown as medians (interquartile range – IQR). The gender, numbers of impacted teeth and their positions are indicated as numbers and percentages (N, %). The Mann-Whitney *U* test was used to conduct a statistical comparison between gender and age groups. Cross tabs were computed for the locations and positions of impacted teeth. The chi-square test was used to evaluate differences between age groups

and the position and prevalence of the impacted teeth. Statistical analyses were performed using SPSS for Windows version 15.0 (SPSS, IL, USA). A value of $p \leq 0.05$ was considered as statistically significant.

No inter- or intra-examiner investigation was undertaken because the diagnosis of impaction and transmigration was an objective assessment. However, the examiners were calibrated to identify impacted/transmigrated canines in 200 panoramic and 50 periapical radiographs. All radiographic data collected on patients with impacted canines were shared between the investigators to obtain a final consensual diagnosis.

Results

The current study retrospectively reviewed the data of 10,700 patients. From this population, 1625 patients were identified with impacted or transmigrated teeth. Of these, 816 (50.2%) were female, while 809 (49.8%) were male. The patients ranged in age from 16 to 73 years. The females' mean age was 43.0 (IQR = 29.0) years, while males had a mean age of 45.0 (IQR = 28.0) years; the age difference was not significant ($Z = 1.560$, $p = 0.119$). Although patient age was not normally distributed ($W = 0.946$, $p < 0.001$), the male and female age groups were similar and the groups balanced (Table I).

The group distributions of impacted and transmigrated canines according to location and gender are shown in Table II. Of 1625 patients, 163 (10.0%) had an impacted canine (with a total of 170 affected teeth). Of the 163 patients, 76 (48.5%) were male and 87 (51.5%) were female. Impacted canines were found in the maxilla in 114 patients (69.9%) while 49 patients (30.1%) had mandibular canine impactions.

Table I. The distribution of patients according to gender and age groups. *P* value showing no statistical difference between male and female patients' mean age.

Age groups	Gender						Total	
	Female			Male			N	%
	N	%	Mean age (IQR)	N	%	Mean age (IQR)		
≤29 years	252	30.9		229	28.3		481	29.6
30 – 39 years	153	18.8		153	18.9		306	18.8
40 – 49 years	154	18.9		153	18.9		307	18.9
50 – 59 years	104	12.7	43.0 (29.0)	120	14.8	45.0 (28.0)	224	13.8
≥60 years	153	18.8		154	19.0		307	18.9
Total	816	100.0		809	100.0		1625	100.0

p value = ($Z = 1.560$; $p = 0.119$)

Table II. Distribution of canine impaction in the study group according to location and gender.

Impaction	Patients	% in sub-groups	<i>P</i> value	Males (N)	<i>P</i> value	Females (N)	<i>P</i> value
<i>Canine impaction</i>	163/1625	10.0		76		87	
Maxillary canine	114/163	69.9	0.016*	54	0.03*	60	0.02*
Mandibular canine	49/163	30.1		22		27	
<i>Canine transmigration</i>	38/163	23.3		17		21	
Maxillary transmigration	18/38	47.4	0.72	6	0.52	12	0.70
Mandibular transmigration	20/38	52.6		11		9	

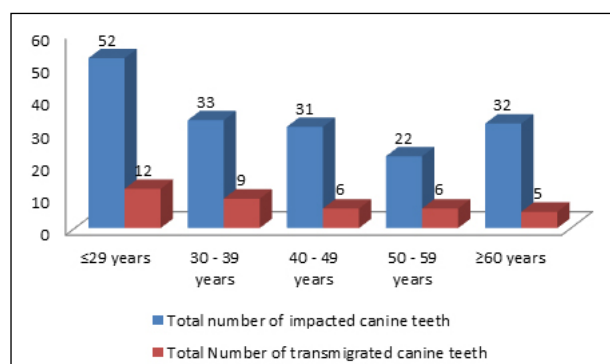
* Indicates statistical significance ($p \leq 0.05$)

Table III. Number of patients with impacted canine according to genders.

Gender	Number of impacted canine			<i>P</i> value
	Unilateral N (%)	Bilateral N (%)	Total N (%)	
Female	83 (95.4)	4 (4.6)	87 (100.0)	$p = 0.838$
Male	73 (96.0)	3 (4.0)	76 (100.0)	
Total	156 (95.7)	7 (4.3)	163 (100.0)	

According to gender, males had impacted canines, in 2.7% of the sample, present in the mandible and 6.7% in the maxilla ($p = 0.03$), while the corresponding values for females were 3.3% and 7.4% ($p = 0.02$), respectively.

In total, 170 impacted canines were detected in 163 patients. Of the impacted canines, 24 were on the right and 25 on the left in the mandible compared with 63 and 58, respectively, in the maxilla. Seven patients had bilaterally impacted canines while 156 were unilateral. There were no significant gender differences related to the impacted canines ($p = 0.838$) (Table III). Figure 1 illustrates the distribution of impacted and transmigrated canines. Canine impaction and transmigration were more frequent in those under 29 years of age, but the differences between the age groups were not significant.

**Figure 1.** The distribution of impacted and transmigrated canine teeth.

The positions of maxillary and mandibular impacted teeth were classified according to location (right or left) and gender. A mesioangular position of impacted canines was the most common displacement in the maxilla, while a vertical position was most commonly found in the mandible. No significant gender or location difference ($p > 0.05$) was identified, but maxillary canine impaction was significantly more frequently evident compared with mandibular canine impaction ($p < 0.05$) (Table IV).

Thirty-eight patients (2.3%) had transmigrated canines. Twenty (52.6%) transmigrated canines were located in the mandible, while 18 (47.4%) were in the maxilla (Figures 2, 3). All identified transmigrated canines were unilateral in nature. The positions of the maxillary and mandibular transmigrated impacted teeth were also classified according to location (right or left) and gender (Table IV). A mesioangular position was the second most frequently discovered following horizontal position for transmigrated canines in both the maxilla and mandible (Figures 4–6). There was no significant gender difference ($p > 0.05$). It was noted that eight patients (21.1%) who had transmigrated maxillary canines were also affected by alpha thalassemia.

Although pathology associated with impacted canines was not investigated in the present study, the CBCT images of those who had impacted canines (whether

Table IV. The distribution of impacted and transmigrated canine teeth according to maxilla and mandible.

	Mandible		Maxilla		
	Impacted canine*	Transmigration	Impacted canine*	Transmigration	
Position	N (M/F)**	N (M/F)**	N (M/F)**	N (M/F)**	
Right	None	797 / 804	781 / 781	-	
	Distoangular	-	-	-	
	Vertical	6 / 3	-	8 / 3	1 / 0
	Mesioangular	6 / 6	5 / 3	18 / 25	1 / 6
	Horizontal	0 / 3	-	2 / 7	1 / 2
	Buccolingual	-	-	-	-
	Inverted	-	-	-	-
	Total	809 / 816	5 / 3	809 / 816	3 / 8
Left	None	799 / 801	780 / 787	-	
	Distoangular	-	-	-	
	Vertical	2 / 4	-	8 / 5	-
	Mesioangular	7 / 8	5 / 3	19 / 19	3 / 3
	Horizontal	1 / 3	1 / 3	2 / 4	0 / 1
	Buccolingual	-	-	0 / 1	-
	Inverted	-	-	-	-
	Total	809 / 816	6 / 6	809 / 816	3 / 4

* Maxillary canine impaction was significantly more frequently apparent than mandibular canine impaction ($p < 0.05$).

** Male/Female

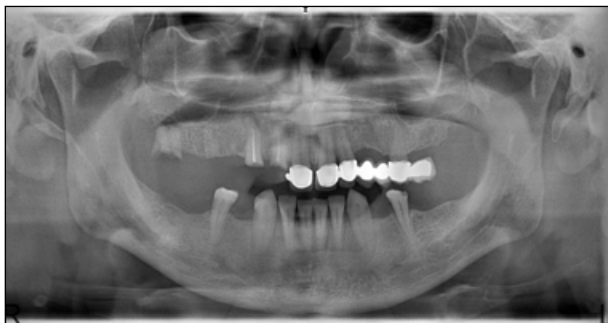

Figure 2. Panoramic radiograph of a 46-year-old patient showing a horizontal canine transmigration in the maxilla.

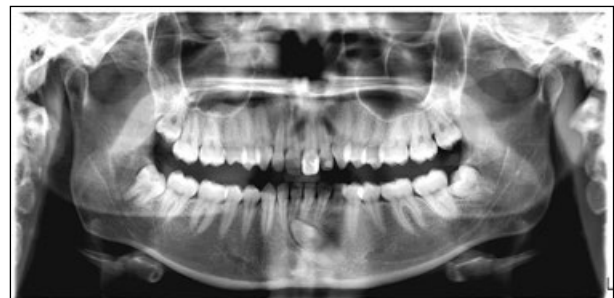

Figure 3. Panoramic radiograph of a 24-year-old patient who complained of pain due to a canine that transmigrated from left to right quadrant.

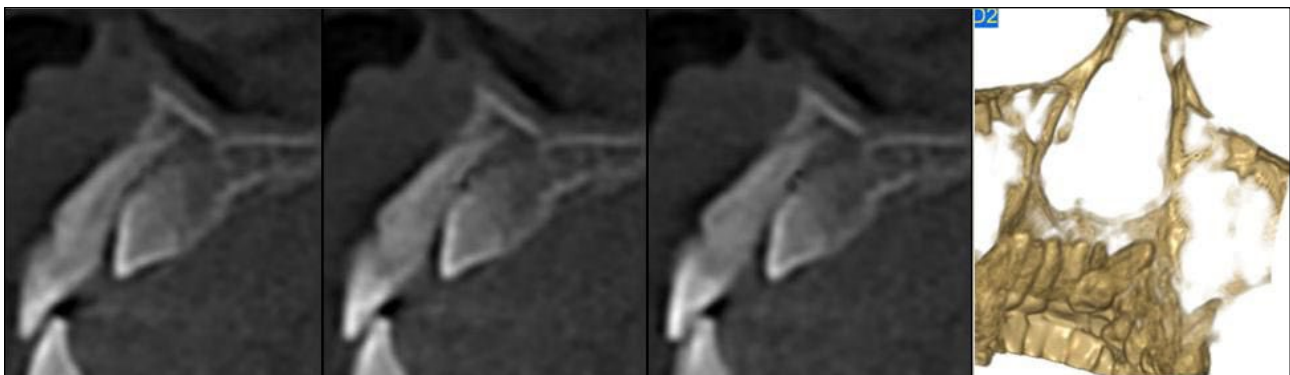


Figure 4. 3D CBCT image with sagittal slices showing the location of the transmigrated maxillary canine in detail.

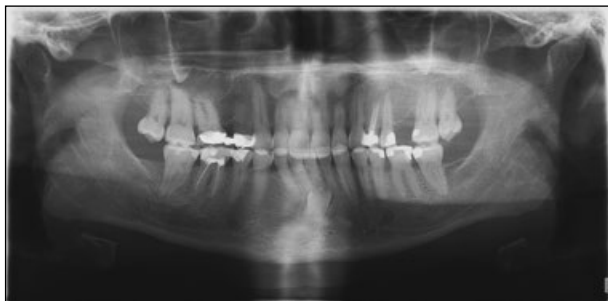

Figure 5. Panoramic radiograph of a patient showing transmigration of the right mandibular canine.

transmigrated or not) revealed resorption of adjacent teeth in 18 patients, which went undetected on conventional radiographs. However, no further comparison of the conventional and CBCT images of those patients was undertaken.

Discussion

Multicentre study designs have several advantages over single-site studies, and include the opportunity for larger sample sizes in different geographic locations, and the possibility of a wider range of population groups, offering an increased validity of the findings. In many cases, prevalence can vary significantly between population groups of different genetic, environmental, and ethnic or cultural backgrounds; in essence, demographic factors, which can usually only be evaluated in geographically widespread trials.⁴⁰

Most studies of impacted and transmigrated teeth have been conducted in a single centre,^{14,16-18,24-28,31-33,41-43} and few comprehensive studies are available.^{22,23,39,33,44} Chu et al.¹ investigated the prevalence of impacted

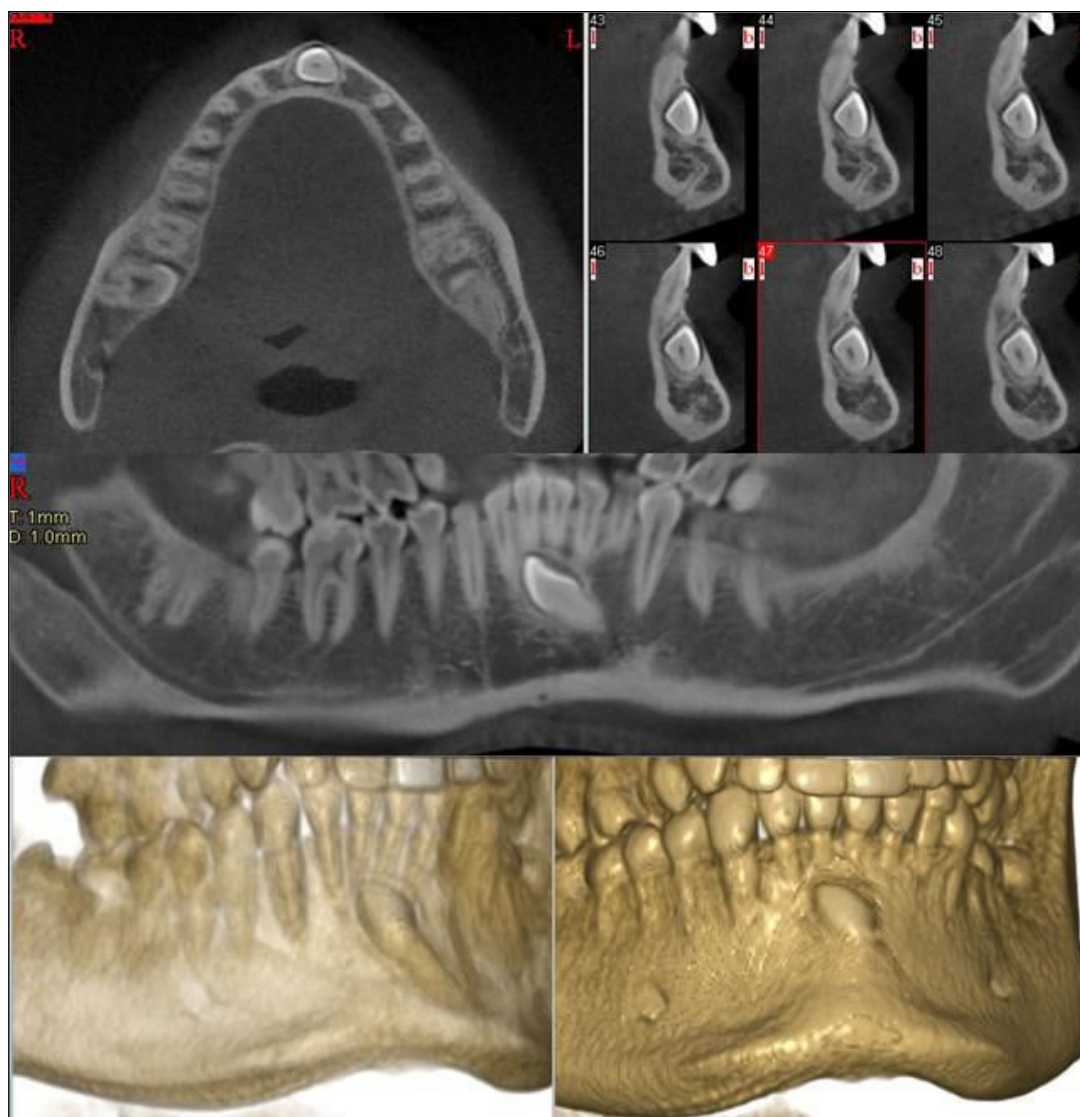


Figure 6. The CBCT axial, paraxial slices and 3D images revealed transmigration of the mandibular left canine.

teeth and their orientations, but did not mention transmigration. Aktan et al.²² reported canine transmigration together with that of other impacted teeth; however, no note was recorded of their orientations. The present comprehensive study investigated the prevalence of maxillary and mandibular impacted and transmigrated canines together with their positions.

As found previously, canine impaction is more prevalent in the maxilla compared with the mandible. Shah et al.⁶ found eight (0.1%) transmigrated mandibular canines, 4.1% maxillary canine impactions and 0.45% mandibular canine impactions in 7,886 individuals. Aktan et al.²² found a prevalence of 0.3% for transmigrated mandibular canines and 0.14% for maxillary transmigrated canines, while Aydin et al.¹⁴ found a prevalence of 3.6% for impacted canines. Gündüz and Çelenk¹⁷ reviewed the records of 12,000 patients and found 13 (0.1%) transmigrated canines in 4.5% of impacted canine cases. Aras et al.³¹ found 12 transmigrated maxillary canines among 6,000 individuals, while Zvolanek³⁹ failed to find any cases in 4,000 individuals. The current study found 170 (1.6%) impacted canines in 10,700 individuals, with 38 (0.4%) transmigrated canines. Additional studies reported no significant variations in the prevalence and distribution of impacted canines.^{14,17,24,27,31} However, in the present study, maxillary canine impaction was significantly more frequently observed than mandibular canine impaction ($p < 0.05$).

Since almost all canine transmigrations are asymptomatic, diagnosis is usually determined by routine radiographic assessment.^{14,16,24,38} A few patients might complain of pain, infection, swelling, or cyst formation resulting from either impacted or transmigrated canines.^{34-36,41,45-47} Joshi⁴¹ indicated that nearly all transmigrated mandibular canines were totally embedded. Aydin et al.¹⁴ reported one partially erupted maxillary transmigrated canine in 14 transmigrated canine cases. Partial eruption is mentioned in only 5% of cases⁶ but, contrarily, the present study determined that all the transmigrated canines were totally impacted, unerupted and asymptomatic.

Although there was no attempt to identify or classify any associated pathology or compare CBCT and conventional radiographs, the CBCT examinations revealed resorption of the adjacent teeth in 18 patients. This was not detected on conventional radiographs and it must be appreciated that an impacted canine can cause severe resorption of adjacent teeth. Since

periapical and panoramic radiographs are two-dimensional images of three-dimensional (3D) structures, the superimposition of adjacent structures can obscure the visibility of teeth. Following the development of CBCT, dentoalveolar imaging using reduced radiation is possible, which provides more accurate results. Recent studies have recommended that a dental CBCT scan be taken to assess impacted teeth and provide 3D regional visualisation to clarify the relationships between the impacted teeth and adjacent structures.⁴⁸⁻⁵⁰ It is suggested that further studies should compare CBCT images and conventional radiographs derived from larger patient samples.

Eight (21.6%) from a study group of 38 patients from Northern Cyprus presenting with transmigrated maxillary canines also had alpha thalassemia. The thalassemsias are a diverse group of genetic blood disorders^{51,52} which are inherited anaemias caused by mutations at the globin gene loci on chromosomes 11 and 16. The production of the α - and β -globin proteins are affected^{53,54} and it has been speculated that a common genetic defect might give rise to different phenotypic manifestations, including missing, malformed, and even ectopic and malpositioned teeth.^{55,56}

Thalassemia is observed chiefly in Mediterranean populations, with a prevalence as high as 15–20% in Greece, Turkey, Cyprus, and southern Italy.⁵¹ In addition to the great ethnic diversity of Northern Cyprus, consanguineous marriage, which contributes to the increased frequency of alpha thalassemia, remains common.⁵⁵ Investigators have compared the radiographic changes of a group of thalassemic patients and concluded that short roots, taurodonts, an attenuated lamina dura, enlarged bone-marrow spaces, small maxillary sinuses, the absence of an inferior alveolar canal, and a thin cortex in the mandible were reliable diagnostic criteria.⁵¹

While the involvement of thalassemia major remains speculative, the current study suggests that thalassemia has a weak association with transmigrated canines and further studies of larger groups are required to reveal a relationship. In conclusion, the present study determined that canine transmigration occurs in both the mandible and maxilla with a prevalence of 10.0% and 2.3%, respectively. The mechanism of canine transmigration remains unclear.

Corresponding author

Dr. Hakan Avsever
 Department of Dentomaxillofacial Radiology
 Health Sciences University
 Ankara
 Turkey
 Email: hakanavsever@gmail.com

References

1. Chu FC, Li TK, Lui VK, Newsome PR, Chow RL, Cheung LK. Prevalence of impacted teeth and associated pathologies--a radiographic study of the Hong Kong Chinese population. *Hong Kong Med J* 2003;9:158-63.
2. Hattab FN, Rawashdeh MA, Fahmy MS. Impaction status of third molars in Jordanian students. *Oral Surg Oral Med Oral Pathol Oral Radiol Endod* 1995;79:24-9.
3. Peltola JS. A panoramatomographic study of the teeth and jaws of Finnish university students. *Community Dent Oral Epidemiol* 1993;21:36-9.
4. Yamaoka M, Furusawa K, Yamamoto M. Influence of adjacent teeth on impacted third molars in the upper and lower jaws. *Aust Dent J* 1995;40:233-5.
5. Torres-Lagares D, Flores-Ruiz R, Infante-Cossío P, García-Calderón M, Gutiérrez-Pérez JL. Transmigration of impacted lower canine. Case report and review of the literature. *Med Oral Patol Oral Cir Bucal* 2006;11:E171-4.
6. Shah RM, Boyd MA, Wakil TF. Studies of permanent tooth anomalies in 7,886 Canadian individuals. I: impacted teeth. *Dent J* 1978;44:262-4.
7. Grover PS, Lorton L. The incidence of unerupted permanent teeth and related clinical cases. *Oral Surg Oral Med Oral Pathol* 1985;59:420-5.
8. Karapanou V. Endodontic management of an impacted premolar. *J Clin Pediatr Dent* 2005;29:293-8.
9. Lee PP. Impacted premolars. *Dent Update* 2005;32:152-4.
10. McNamara C, McNamara TG. Mandibular premolar impaction: 2 case reports. *J Can Dent Assoc* 2005;71:859-63.
11. Murray P, Brown NL. The conservative approach to managing unerupted lower premolars -- two case reports. *Int J Paediatr Dent* 2003;13:198-203.
12. Bjerklín K, Ericson S. How a computerized tomography examination changed the treatment plans of 80 children with retained and ectopically positioned maxillary canines. *Angle Orthod* 2006;76:43-51.
13. Zasciurinskiene E, Bjerklín K, Smailiene D, Sidlauskas A, Puisys A. Initial vertical and horizontal position of palatally impacted maxillary canine and effect on periodontal status following surgical-orthodontic treatment. *Angle Orthod* 2008;78:275-80.
14. Aydin U, Yilmaz HH, Yildirim D. Incidence of canine impaction and transmigration in a patient population. *Dentomaxillofac Radiol* 2004;33:164-9.
15. Ericson S, Kurol J. Longitudinal study and analysis of clinical supervision of maxillary canine eruption. *Community Dent Oral Epidemiol* 1986;14:172-6.
16. González-Sánchez MA, Berini-Aytés L, Gay-Escoda C. Transmigrant impacted mandibular canines: a retrospective study of 15 cases. *J Am Dent Assoc* 2007;138:1450-5.
17. Gündüz K, Çelenk P. The incidence of impacted transmigrant canines: a retrospective study. *Oral Radiol* 2010;26:77-81.
18. Mazinis E, Zafeiriadis A, Karathanasis A, Lambrianidis T. Transmigration of impacted canines: prevalence, management and implications on tooth structure and pulp vitality of adjacent teeth. *Clin Oral Investig* 2012;16:625-32.
19. Ericson S, Kurol J. Radiographic examination of ectopically erupting maxillary canines. *Am J Orthod Dentofacial Orthop* 1987;91:483-92.
20. Ericson S, Kurol PJ. Resorption of incisors after ectopic eruption of maxillary canines: a CT study. *Angle Orthod* 2000;70:415-23.
21. Ericson S, Kurol J. Incisor root resorptions due to ectopic maxillary canines imaged by computerized tomography: a comparative study in extracted teeth. *Angle Orthod* 2000;70:276-83.
22. Aktan AM, Kara S, Akgünlü F, Malkoç S. The incidence of canine transmigration and tooth impaction in a Turkish subpopulation. *Eur J Orthod* 2010;32:575-81.
23. Auluck A, Nagpal A, Setty S, Pai KM, Sunny J. Transmigration of impacted mandibular canines--report of 4 cases. *J Can Dent Assoc* 2006;72:249-52.
24. Buyukkurt MC, Aras MH, Caglaroglu M, Gungormus M. Transmigrant mandibular canines. *J Oral Maxillofac Surg* 2007;65:2025-9.
25. Camilleri S, Scerri E. Transmigration of mandibular canines--a review of the literature and a report of five cases. *Angle Orthod* 2003;73:753-62.
26. Celikoglu M, Kamak H, Oktay H. Investigation of transmigrated and impacted maxillary and mandibular canine teeth in an orthodontic patient population. *J Oral Maxillofac Surg* 2010;68:1001-6.
27. Kara MI, Ay S, Aktan AM, Şener I, Bereket C, Ezirganlı Ş, Demirkol M. Analysis of different type of transmigrant mandibular teeth. *Med Oral Patol Oral Cir Bucal* 2011;16:e335-40.
28. Sumer P, Sumer M, Ozden B, Otan F. Transmigration of mandibular canines: a report of six cases and a review of the literature. *J Contemp Dent Pract* 2007;8:104-10.
29. Vuchkova J, Farah CS. Canine transmigration: comprehensive literature review and report of 4 new Australian cases. *Oral Surg Oral Med Oral Pathol Oral Radiol Endod* 2010;109:e46-53.
30. Javid B. Transmigration of impacted mandibular cuspids. *Int J Oral Surg* 1985;14:547-9.
31. Aras MH, Büyükkurt MC, Yolcu U, Ertaş U, Dayı E. Transmigrant maxillary canines. *Oral Surg Oral Med Oral Pathol Oral Radiol Endod* 2008;105:e48-52.
32. Shapira Y, Kufteinc MM. Unusual intraosseous transmigration of a palatally impacted canine. *Am J Orthod Dentofacial Orthop* 2005;127:360-3.
33. Tarsitano JJ, Wooten JW, Burditt JT. Transmigration of nonerupted mandibular canines: report of cases. *J Am Dent Assoc* 1971;82:1395-7.
34. D'Amico RM, Bjerklín K, Kurol J, Falahat B. Long-term results of orthodontic treatment of impacted maxillary canines. *Angle Orthod* 2003;73:231-8.
35. Kurol J. Impacted and ankylosed teeth: why, when, and how to intervene. *Am J Orthod Dentofacial Orthop* 2006;129:S86-90.
36. Kurol J. Unusual transmigration of an impacted maxillary canine. *Am J Orthod Dentofacial Orthop* 2006;129:321.
37. Ahlqvist M, Gröndahl HG. Prevalence of impacted teeth and associated pathology in middle-aged and older Swedish women. *Community Dent Oral Epidemiol* 1991;19:116-9.
38. Mupparapu M. Patterns of intra-osseous transmigration and ectopic eruption of mandibular canines: review of literature and report of nine additional cases. *Dentomaxillofac Radiol* 2002;31:355-60.
39. Zvolanek JW. Transmigration of an impacted mandibular canine. *Ill Dent J* 1986;55:86-7.
40. Guthrie LB, Oken E, Sterne JA, Gillman MW, Patel R, Vilchuck K et al. Ongoing monitoring of data clustering in multicenter studies. *BMC Med Res Methodol* 2012;12:29.
41. Joshi MR. Transmigrant mandibular canines: a record of 28 cases and a retrospective review of the literature. *Angle Orthod* 2001;71:12-22.

42. Shapira Y, Kuftinec MM. Intrabony migration of impacted teeth. *Angle Orthod* 2003;73:738-43.
43. Tseng YC, Chang HP, Chou TM. Canine transposition. *Kaohsiung J Med Sci* 2005;21:441-7.
44. Fardi A, Kondylidou-Sidira A, Bachour Z, Parisis N, Tsirlis A. Incidence of impacted and supernumerary teeth-a radiographic study in a North Greek population. *Med Oral Patol Oral Cir Bucal* 2011;16:e56-61.
45. Bjerklín K, Bondemark L. Management of ectopic maxillary canines: variations among orthodontists. *Angle Orthod* 2008;78:852-9.
46. Bjerklín K, Guitirokh CH. Maxillary incisor root resorption induced by ectopic canines. *Angle Orthod* 2011;81:800-6.
47. Naoumova J, Kuroi J, Kjellberg H. A systematic review of the interceptive treatment of palatally displaced maxillary canines. *Eur J Orthod* 2011;33:143-9.
48. Cotton TP, Geisler TM, Holden DT, Schwartz SA, Schindler WG. Endodontic applications of cone-beam volumetric tomography. *J Endod* 2007;33:1121-32.
49. Patel S, Dawood A, Ford TP, Whaites E. The potential applications of cone beam computed tomography in the management of endodontic problems. *Int Endod J* 2007;40:818-30.
50. Patel S. New dimensions in endodontic imaging: Part 2. Cone beam computed tomography. *Int Endod J* 2009;42:463-75.
51. Hazza'a AM, Al-Jamal G. Dental development in subjects with thalassemia major. *J Contemp Dent Pract* 2006;7:63-70.
52. Hazza'a AM, Al-Jamal G. Radiographic features of the jaws and teeth in thalassaemia major. *Dentomaxillofac Radiol* 2006;35:283-8.
53. Cunningham MJ. Update on thalassemia: clinical care and complications. *Hematol Oncol Clin North Am* 2010;24:215-27.
54. Vichinsky EP. Alpha thalassemia major--new mutations, intrauterine management, and outcomes. *Hematology Am Soc Hematol Educ Program* 2009:35-41.
55. Guvenc B, Yildiz SM, Tekinturhan F, Dincer S, Akyuzluer I, Okten S et al. Molecular characterization of alpha-Thalassemia in Adana, Turkey: A single center study. *Acta Haematol* 2010;123:197-200.
56. Kotsomitis N, Freer TJ. Inherited dental anomalies and abnormalities. *ASDC J Dent Child* 1997;64:405-8.